Textual Version of Modha and Singh's Diagram of the Macaque Brain Network Architecture

Eddie Monroe & Ben Goertzel, Novamente LLC

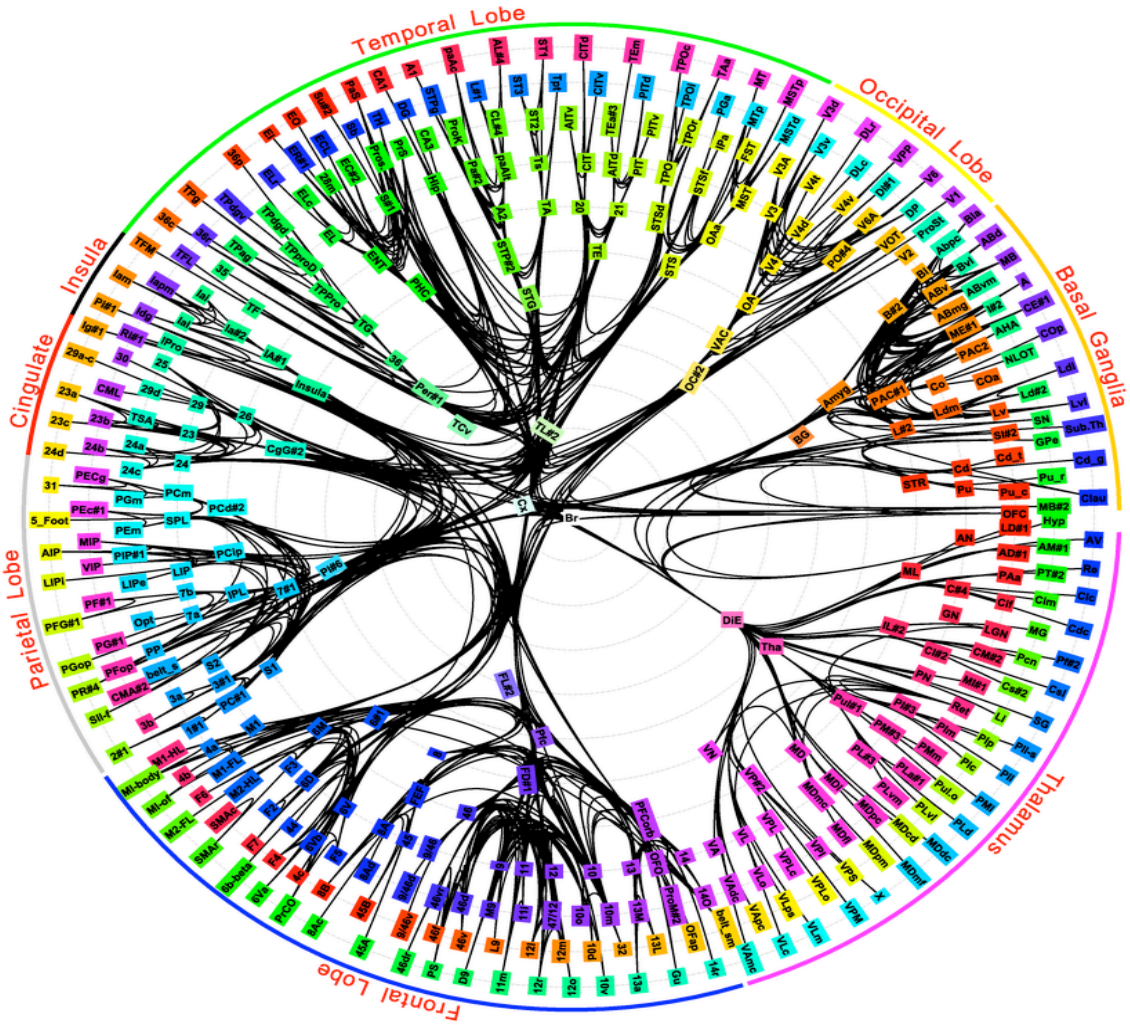
Temporal Lobe
Occipital Lobe
Basal Ganglia
Thalamus
Frontal Lobe
Parietal Lobe
Cingulate
Insula

Introduction

On July 27 2010, PNAS published a paper entitled "Network architecture of the long-distance pathways in the macaque brain" by Dharmendra Modha and Raghavendra Singh from IBM, which is briefly described here

http://modha.org/blog/2010/07/

and available in full here

http://www.pnas.org/content/107/30/13485.full

The highlight of the paper is a connectivity diagram of all the regions of the macaque (monkey) brain, reproduced on the previous page. See

http://www.modha.org/PNAS10/network.pdf

for a hi-res image of the diagram as a single PDF. But note that, even with the version on the previous page, you can zoom in on specific regions.

The diagram portrays "a unique network incorporating 410 anatomical tracing studies of the macaque brain from the Collation of Connectivity data on the Macaque brain (CoCoMac) neuroinformatic database. Our network consists of 383 hierarchically organized regions spanning cortex, thalamus, and basal ganglia; models the presence of 6,602 directed long-distance connections; is three times larger than any previously derived brain network; and contains subnetworks corresponding to classic corticocortical, corticosubcortical, and subcortico-subcortical fiber systems."

However, we found that the diagram can be somewhat confusing to browse, if one wants to look at specific brain regions and what they connect to. So we went back to the original data files, given in the online supplementary information for the paper, and used this to make a textual version of the information in the diagram. This is given below.

Notation

The textual notation we've used to depict the network is as follows:

Region: name (CoCoMac acronym)
Super-regions: region < parent region < parent region < parent region
Sources: regions which project to this region
Descendant sources: sources of all descendant regions
Targets: regions to which this region projects
Descendant targets: targets of all descendant regions
Subregions: direct children of the current region

If you want to search the file for a specific brain region and then see what regions it connects to, the easiest procedure is to search the file for a string such as "Region: Hippocampus" or search for the acronym used in the graph, such as "(Hip)", which will then bring you to the portion of the file listing all the Hippocampus's connections.

Note also that we have used indentation to denote the parent-child relationship between brain regions. So, the sections of the document corresponding to the children of a brain region, are shown indented below the section of the document corresponding to the parent brain region.

Finally, note that Pages 41-50 of the Appendix to the paper, available at

http://www.pnas.org/content/107/30/13485/suppl/DCSupplemental

translate the acronyms used in the diagram to the full textual brain region names used in this document. So if one browses the diagram, one can then check that Appendix to find the full region names corresponding to the acronyms used in the diagram.

Region: Brain (Br)

Sub-regions:
Basal Ganglia according to GM-Definition, Diencephalon, GM-CerebralCortex, Medial basal nucleus of the amygdala, Olfactory Complex

---
Region: Diencephalon (DiE)

Super-regions:
Diencephalon < Brain

Descendant sources:
Accessory basal amygdaloid nucleus, parvicellular part, Agranular frontal area 2 (= caudal dorsolateral premotor area), Agranular frontal area 3 (= SMA-proper), Agranular frontal area 4 (= caudal ventrolateral premotor area), Agranular frontal area 5 (= rostral ventrolateral premotor area), Agranular frontal area 6 (= pre-SMA), Agranular frontal area 7 (= rostral dorsolateral premotor area), Agranular insula, Amygdala, Area 1, Area 10, Area 11, Area 12, Area 23, Area 23c, Area 24a, Area 24b, Area 24c (rostral part of the cingulate sulcus), Area 24d (rostral part of the cingulate sulcus), Area 25, Area 32, Area 35, Area 36, Area 6, Area 6 (ventral part), Area 7, Area 7b, Area 8, Area 8A, Area 9, Basolateral nucleus of amygdala, Caudal and medial superior parietal lobule, Caudal inferior parietal lobule, Cortical area 45, Cortical area 46, Dorsal prelunate gyrus, Dorsal visual area 3, Dysgranular insular cortex, Entorhinal cortex, Extrastriate area OA, Frontal eye field, Globus pallidus external part, Gustatory cortex, Hippocampus, Inferior parietal lobule (lateral posterior cortex below the intraparietal sulcus), Inferotemporal area TE, Insula, Intraparietal sulcus associated area in the superior temporal sulcus, LGN external magnocellular layer, LGN layer 2, Lateral area 12, Lateral auditory field, Lateral auditory parakoniocortex, Medial agranular insular cortex, Medial area 12, Medial basal nucleus of the amygdala, Medial basal nucleus of the amygdala, Medial premotor area 6M, Middle temporal area, Midpart of the inferior parietal lobule, Nucleus basalis thalami, Nucleus peripeduncularis thalami, Nucleus pulvinaris inferior thalami, Nucleus pulvinaris thalami, Nucleus reticularis thalami, Olfactory Complex, Orbital area 12, Orbitofrontal area 13, Orbitofrontal area 13a, Orbitofrontal area 14, Orbitofrontal cortex, agranular periallocortical, Parietal area PE (cingulate part), Parietal area PG, medial part, Postcentral area 3a, Postcentral area 3b, Posterior inferotemporal area, Precentral opercular area, Premotor area 6 (dorsal part), Primary motor area, Primary motor cortex M1, forelimb area, Primary motor cortex M1, hindlimb area, Primary sensory cortex, Pro motor area, Receptive field for the foot in Area5, Rostral superior parietal lobule, Secondary auditory cortex, Secondary somatosensory cortex, Superior temporal area 3, Temporal area TF, Temporal area TH, Temporal parietooccipital associated area in superior temporal sulcus, Temporal proisocortex, Temporoparietal asscociated area (caudal part), Temporoparietal associated area (rostral part), Temporopolar area TG, V4 transitional area, Ventolateral Nucleii of Thalamus, Ventral area 46, Ventral visual area 3, Visual area 1, Visual area 2, Visual area 3, Visual area 4, Visual area 4 (dorsal part), accessory basal nucleus (amygdala), magnocellular subdivision, amygdalohippocampal area, anterior amygdaloid area, area 24, body representation of MI as defined in KSI03, central nucleus of the amygdala, cortical nucleus, anterior division, cortical nucleus, posterior division, periamygdaloid cortex, superior parietal lobule (posterior dorsomedial parietal cortex above the intraparietal sulcus), ventral striatal shell

Descendant targets:
Agranular frontal area 2 (= caudal dorsolateral premotor area), Agranular frontal area 3 (= SMA-proper), Agranular frontal area 4 (= caudal ventrolateral premotor area), Agranular frontal area 5 (= rostral ventrolateral premotor area), Agranular frontal area 6 (= pre-SMA), Agranular frontal area 7 (= rostral dorsolateral premotor area), Amygdala, Anterior inferotemporal area (dorsal), Area 1, Area 10, Area 11, Area 12, Area 20, Area 21, Area 23c, Area 24b, Area 24d (rostral part of the cingulate sulcus), Area 25, Area 32, Area 6, Area 6 (ventral part), Area 6 (ventral part), Area 7, Area 7b, Area 8, Area 8A, Area 8B, Area 9, Caudal and medial superior parietal lobule, Caudal auditory parakoniocortex, Caudal inferior parietal lobule, Cortical area 45, Cortical area 46, Cortical area TEm, Dorsal area 46, Dysgranular insular cortex, Entorhinal cortex, Extrastriate area OA, Fascia dentata hippocampi, Frontal eye field, Granular insular cortex, Gustatory cortex, Inferotemporal area TE, Insula, Intermediate agranula insular cortex, LGN layer 2, Lateral Geniculate Nucleus, Lateral agranular insular cortex, Lateral area 12, Lateral auditory field, Lateral auditory field, Lateral intraparietal area, Lateral nucleus (amygdala), dorsal intermediate division, Lateral nucleus (amygdala), ventral division, Medial agranular insular cortex, Medial area 11, Medial intraparietal area, Medial premotor area 6M, Middle temporal area,

Midpart of the inferior parietal lobule, Motor area 4c, Nucleus medialis dorsalis thalami, Nucleus medialis dorsalis thalami, pars magnocellularis, Nucleus paraventricularis thalami, Nucleus reticularis thalami, Nucleus ventralis anterior thalami, pars densocellularis, Nucleus ventralis anterior thalami, pars magnocellularis, Nucleus ventralis anterior thalami, pars parvocellularis, Occipitoparietal area, Orbital area 12, Orbitofrontal area 13, Orbitofrontal area 13a, Orbitofrontal area 14, Parasubiculum, Parietal area PG, medial part, Postcentral area 3a, Postcentral area 3b, Posterior inferotemporal area, Posteromedial agranular insular cortex, Precentral opercular area, Premotor area 6 (dorsal part), Presubiculum, Primary auditory cortex, Primary motor area, Primary motor cortex M1, forelimb area, Primary motor cortex M1, hindlimb area, Primary sensory area PC, Primary somatosensory cortex, Receptive field for the foot in Area5, Rostral area 14, Rostral inferior parietal lobule, Rostral superior parietal lobule, Secondary somatosensory cortex, Superior temporal area 1, Superior temporal area 2, Superior temporal area 3, Superior temporal sulcus, Temporal area TA, Temporal area TF, Temporal area TH, Temporal parietooccipital associated area in superior temporal sulcus, Temporoparietal cortex, Temporopolar area TG, Ventral area 46, Visual area 1, Visual area 2, Visual area 3, Visual area 4, area 24, auditory prokoniocortex, body representation of MI as defined in KSI03, superior parietal lobule (posterior dorsomedial parietal cortex above the intraparietal sulcus), superior temporal gyrus, ventral lateral nucleus (thalamus)

Sub-regions:
Hypothalamus, Thalamus

Region: Hypothalamus (Hyp)

Super-regions:
Hypothalamus < Diencephalon < Brain

Sources:
Lateral area 12, Primary sensory cortex

Targets:
Agranular frontal area 7 (= rostral dorsolateral premotor area), Amygdala, Area 12, Area 25, Area 7, Caudal inferior parietal lobule, Cortical area 45, Cortical area 46, Extrastriate area OA, Fascia dentata hippocampi, Frontal eye field, Granular insular cortex, Inferotemporal area TE, Insula, Orbitofrontal area 13, Premotor area 6 (dorsal part), Primary somatosensory cortex, Secondary somatosensory cortex, Temporal area TA, Temporal area TH, Temporopolar area TG, area 24, superior parietal lobule (posterior dorsomedial parietal cortex above the intraparietal sulcus)

Region: Thalamus (Tha)

Super-regions:
Thalamus < Diencephalon < Brain

Descendant sources:
Accessory basal amygdaloid nucleus, parvicellular part, Agranular frontal area 2 (= caudal dorsolateral premotor area), Agranular frontal area 3 (= SMA-proper), Agranular frontal area 4 (= caudal ventrolateral premotor area), Agranular frontal area 5 (= rostral ventrolateral premotor area), Agranular frontal area 6 (= pre-SMA), Agranular frontal area 7 (= rostral dorsolateral premotor area), Agranular insula, Amygdala, Area 1, Area 10, Area 11, Area 12, Area 23, Area 23c, Area 24a, Area 24b, Area 24c (rostral part of the cingulate sulcus), Area 24d (rostral part of the cingulate sulcus), Area 25, Area 32, Area 35, Area 36, Area 6, Area 6 (ventral part), Area 7, Area 7b, Area 8, Area 8A, Area 9, Basolateral nucleus of amygdala, Caudal and medial superior parietal lobule, Caudal inferior parietal lobule, Cortical area 45, Cortical area 46, Dorsal prelunate gyrus, Dorsal visual area 3, Dysgranular insular cortex, Entorhinal cortex, Extrastriate area OA, Frontal eye field, Globus pallidus external part, Gustatory cortex, Hippocampus, Inferior parietal lobule (lateral posterior cortex below the intraparietal sulcus), Inferotemporal area TE, Insula, Intraparietal sulcus associated area in the superior temporal sulcus, LGN external magnocellular layer, LGN layer 2, Lateral area 12, Lateral auditory field, Lateral auditory parakoniocortex, Medial agranular insular cortex, Medial area 12, Medial basal nucleus of the amygdala, Medial basal nucleus of the amygdala, Medial premotor area 6M, Middle temporal area, Midpart of the inferior parietal lobule, Nucleus basalis thalami, Nucleus peripeduncularis thalami, Nucleus pulvinaris inferior thalami, Nucleus pulvinaris thalami, Nucleus reticularis thalami, Olfactory Complex, Orbital area 12, Orbitofrontal area 13, Orbitofrontal area 13a, Orbitofrontal area 14, Orbitofrontal cortex, agranular periallocortical, Parietal area

PE (cingulate part), Parietal area PG, medial part, Postcentral area 3a, Postcentral area 3b, Posterior inferotemporal area, Precentral opercular area, Premotor area 6 (dorsal part), Primary motor area, Primary motor cortex M1, forelimb area, Primary motor cortex M1, hindlimb area, Primary sensory cortex, Pro motor area, Receptive field for the foot in Area5, Rostral superior parietal lobule, Secondary auditory cortex, Secondary somatosensory cortex, Superior temporal area 3, Temporal area TF, Temporal area TH, Temporal parietooccipital associated area in superior temporal sulcus, Temporal proisocortex, Temporoparietal asscociated area (caudal part), Temporoparietal associated area (rostral part), Temporopolar area TG, V4 transitional area, Ventolateral Nucleii of Thalamus, Ventral area 46, Ventral visual area 3, Visual area 1, Visual area 2, Visual area 3, Visual area 4, Visual area 4 (dorsal part), accessory basal nucleus (amygdala), magnocellular subdivision, amygdalohippocampal area, anterior amygdaloid area, area 24, body representation of MI as defined in KSI03, central nucleus of the amygdala, cortical nucleus, anterior division, cortical nucleus, posterior division, periamygdaloid cortex, superior parietal lobule (posterior dorsomedial parietal cortex above the intraparietal sulcus), ventral striatal shell

Targets:
Premotor area 6 (dorsal part)

Descendant targets:
Agranular frontal area 2 (= caudal dorsolateral premotor area), Agranular frontal area 3 (= SMA-proper), Agranular frontal area 4 (= caudal ventrolateral premotor area), Agranular frontal area 5 (= rostral ventrolateral premotor area), Agranular frontal area 6 (= pre-SMA), Agranular frontal area 7 (= rostral dorsolateral premotor area), Anterior inferotemporal area (dorsal), Area 1, Area 10, Area 11, Area 12, Area 20, Area 21, Area 23c, Area 24b, Area 24d (rostral part of the cingulate sulcus), Area 25, Area 32, Area 6, Area 6 (ventral part), Area 6 (ventral part), Area 7, Area 7b, Area 8, Area 8A, Area 8B, Area 9, Caudal and medial superior parietal lobule, Caudal auditory parakoniocortex, Caudal inferior parietal lobule, Cortical area 45, Cortical area 46, Cortical area TEm, Dorsal area 46, Dysgranular insular cortex, Entorhinal cortex, Extrastriate area OA, Fascia dentata hippocampi, Frontal eye field, Gustatory cortex, Inferotemporal area TE, Insula, Intermediate agranula insular cortex, LGN layer 2, Lateral Geniculate Nucleus, Lateral agranular insular cortex, Lateral area 12, Lateral auditory field, Lateral auditory field, Lateral intraparietal area, Lateral nucleus (amygdala), dorsal intermediate division, Lateral nucleus (amygdala), ventral division, Medial agranular insular cortex, Medial area 11, Medial intraparietal area, Medial premotor area 6M, Middle temporal area, Midpart of the inferior parietal lobule, Motor area 4c, Nucleus medialis dorsalis thalami, Nucleus medialis dorsalis thalami, pars magnocellularis, Nucleus paraventricularis thalami, Nucleus reticularis thalami, Nucleus ventralis anterior thalami, pars densocellularis, Nucleus ventralis anterior thalami, pars magnocellularis, Nucleus ventralis anterior thalami, pars parvocellularis, Occipitoparietal area, Orbital area 12, Orbitofrontal area 13, Orbitofrontal area 13a, Orbitofrontal area 14, Parasubiculum, Parietal area PG, medial part, Postcentral area 3a, Postcentral area 3b, Posterior inferotemporal area, Posteromedial agranular insular cortex, Precentral opercular area, Premotor area 6 (dorsal part), Presubiculum, Primary auditory cortex, Primary motor area, Primary motor cortex M1, forelimb area, Primary motor cortex M1, hindlimb area, Primary sensory area PC, Primary somatosensory cortex, Receptive field for the foot in Area5, Rostral area 14, Rostral inferior parietal lobule, Rostral superior parietal lobule, Secondary somatosensory cortex, Superior temporal area 1, Superior temporal area 2, Superior temporal area 3, Superior temporal sulcus, Temporal area TA, Temporal area TF, Temporal parietooccipital associated area in superior temporal sulcus, Temporoparietal cortex, Temporopolar area TG, Ventral area 46, Visual area 1, Visual area 2, Visual area 3, Visual area 4, area 24, auditory prokoniocortex, body representation of MI as defined in KSI03, superior parietal lobule (posterior dorsomedial parietal cortex above the intraparietal sulcus), superior temporal gyrus, ventral lateral nucleus (thalamus)

Sub-regions:
Anterior nuclei of the thalamus, Intralaminar nuclei of the thalamus, LGN internal magnocellular layer, Metathalamus (Geniculate Nucleii), Midline nuclei of the thalamus, Nucleus medialis dorsalis thalami, Nucleus pulvinaris thalami, Nucleus reticularis thalami, Posterior Nucleii of Thalamus, Ventolateral Nucleii of Thalamus

---
Region: Anterior nuclei of the thalamus (AN)

Super-regions:
Anterior nuclei of the thalamus < Thalamus < Diencephalon

<   Brain

Descendant sources:
Amygdala, Area 23, Area 7, Dorsal prelunate gyrus,
Extrastriate area OA, Orbitofrontal area 13a, Parietal area PG,
medial part, Temporal area TF, Temporal area TH, Visual area
2, area 24

Targets:
Area 11, Area 32, Cortical area 46, Lateral area 12, Orbital
area 12, Orbitofrontal area 14, Parasubiculum, Presubiculum

Descendant targets:
Agranular frontal area 2 (= caudal dorsolateral premotor area),
Agranular frontal area 6 (= pre-SMA), Agranular frontal area 7
(= rostral dorsolateral premotor area), Area 10, Area 11, Area
12, Area 32, Caudal inferior parietal lobule, Cortical area
46, Entorhinal cortex, Lateral area 12, Lateral intraparietal
area, Medial area 11, Occipitoparietal area, Orbital area 12,
Orbitofrontal area 13, Orbitofrontal area 13a, Orbitofrontal
area 14, Parietal area PG, medial part, Primary motor cortex
M1, forelimb area, Rostral area 14, Temporopolar area TG, area
24

Sub-regions:
Anterior medial nucleus, Laterodorsal nucleus (thalamus),
Nucleus anterior ventralis thalami, area dentata (dentate gyrus)

Region: Laterodorsal nucleus (thalamus) (LD#1)

Super-regions:
Laterodorsal nucleus (thalamus)   <   Anterior nuclei of the
thalamus   <   Thalamus   <   Diencephalon   <   Brain

Sources:
Amygdala, Area 23, Area 7, Dorsal prelunate gyrus,
Extrastriate area OA, Parietal area PG, medial part,
Temporal area TF, Temporal area TH, Visual area 2

Targets:
Agranular frontal area 2 (= caudal dorsolateral premotor
area), Entorhinal cortex, Lateral intraparietal area,
Occipitoparietal area, Primary motor cortex M1, forelimb
area

Region: Nucleus anterior ventralis thalami (AV)

Super-regions:
Nucleus anterior ventralis thalami   <   Anterior nuclei of
the thalamus   <   Thalamus   <   Diencephalon   <   Brain

Sources:
Area 23, Temporal area TH

Targets:
Agranular frontal area 2 (= caudal dorsolateral premotor
area), Area 32, Cortical area 46, Occipitoparietal area,
Parietal area PG, medial part

Region: Anterior medial nucleus (AM#1)

Super-regions:
Anterior medial nucleus   <   Anterior nuclei of the
thalamus   <   Thalamus   <   Diencephalon   <   Brain

Sources:
Amygdala, Area 23, Orbitofrontal area 13a, area 24

Targets:
Agranular frontal area 2 (= caudal dorsolateral premotor
area), Agranular frontal area 6 (= pre-SMA), Area 10,
Area 11, Area 12, Area 32, Caudal inferior parietal
lobule, Lateral area 12, Medial area 11, Occipitoparietal
area, Orbital area 12, Orbitofrontal area 13,
Orbitofrontal area 13a, Orbitofrontal area 14, Parietal
area PG, medial part, Rostral area 14, Temporopolar area
TG, area 24

Region: area dentata (dentate gyrus) (AD#1)

Super-regions:
area dentata (dentate gyrus) < Anterior nuclei of the thalamus < Thalamus < Diencephalon < Brain

Sources:
Orbitofrontal area 13a

Targets:
Agranular frontal area 2 (= caudal dorsolateral premotor area), Agranular frontal area 7 (= rostral dorsolateral premotor area), Area 32, Rostral area 14

Region: Midline nuclei of the thalamus (ML)

Super-regions:
Midline nuclei of the thalamus < Thalamus < Diencephalon < Brain

Descendant sources:
Amygdala, Area 1, Insula, Orbitofrontal area 13, Orbitofrontal area 13a, Postcentral area 3b, Temporopolar area TG, area 24

Targets:
Area 11, Area 32, Area 8B, Cortical area 46, Lateral area 12, Lateral auditory field, Lateral nucleus (amygdala), dorsal intermediate division, Lateral nucleus (amygdala), ventral division, Orbital area 12, Orbitofrontal area 14, Temporopolar area TG, Ventral area 46

Descendant targets:
Agranular frontal area 2 (= caudal dorsolateral premotor area), Agranular frontal area 3 (= SMA-proper), Agranular frontal area 6 (= pre-SMA), Agranular frontal area 7 (= rostral dorsolateral premotor area), Area 10, Area 11, Area 12, Area 32, Area 8B, Cortical area 46, Fascia dentata hippocampi, Frontal eye field, Inferotemporal area TE, Insula, Lateral area 12, Lateral auditory field, Orbital area 12, Orbitofrontal area 13, Orbitofrontal area 14, Parietal area PG, medial part, Posterior inferotemporal area, Posteromedial agranular insular cortex, Temporal parietooccipital associated area in superior temporal sulcus, Temporopolar area TG, Ventral area 46, area 24, superior parietal lobule (posterior dorsomedial parietal cortex above the intraparietal sulcus)

Sub-regions:
Cortical amygdaloid nucleus, Nucleus parataenialis thalami, Nucleus paraventricularis thalami, pars anterior, Nucleus reuniens thalami

---
Region: Nucleus reuniens thalami (Re)

Super-regions:
Nucleus reuniens thalami < Midline nuclei of the thalamus < Thalamus < Diencephalon < Brain

Sources:
Amygdala, Insula, Orbitofrontal area 13, Temporopolar area TG, area 24

Targets:
Agranular frontal area 2 (= caudal dorsolateral premotor area), Agranular frontal area 3 (= SMA-proper), Agranular frontal area 6 (= pre-SMA), Agranular frontal area 7 (= rostral dorsolateral premotor area), Area 11, Area 32, Inferotemporal area TE, Insula, Lateral area 12, Lateral auditory field, Orbital area 12, Orbitofrontal area 13, Orbitofrontal area 14, Parietal area PG, medial part, Posteromedial agranular insular cortex, Temporal parietooccipital associated area in superior temporal sulcus, Temporopolar area TG, Ventral area 46, area 24

Region: Nucleus parataenialis thalami (PT#2)

Super-regions:

Nucleus parataenialis thalami < Midline nuclei of the thalamus < Thalamus < Diencephalon < Brain

Sources:
Amygdala, Orbitofrontal area 13, Temporopolar area TG, area 24

Targets:
Area 10, Orbitofrontal area 13, Orbitofrontal area 14

Region: Nucleus paraventricularis thalami, pars anterior (PAa)

Super-regions:
Nucleus paraventricularis thalami, pars anterior < Midline nuclei of the thalamus < Thalamus < Diencephalon < Brain

Sources:
Amygdala, Area 1, Orbitofrontal area 13, Postcentral area 3b, area 24

Targets:
Area 11, Area 32, Lateral auditory field, Orbital area 12, Orbitofrontal area 14, Temporopolar area TG, area 24, superior parietal lobule (posterior dorsomedial parietal cortex above the intraparietal sulcus)

Region: Cortical amygdaloid nucleus (C#4)

Super-regions:
Cortical amygdaloid nucleus < Midline nuclei of the thalamus < Thalamus < Diencephalon < Brain

Descendant sources:
Amygdala, Orbitofrontal area 13, Orbitofrontal area 13a, area 24

Targets:
Agranular frontal area 3 (= SMA-proper), Inferotemporal area TE, Posterior inferotemporal area, Ventral area 46

Descendant targets:
Agranular frontal area 3 (= SMA-proper), Agranular frontal area 7 (= rostral dorsolateral premotor area), Area 10, Area 11, Area 12, Area 32, Area 8B, Cortical area 46, Fascia dentata hippocampi, Frontal eye field, Lateral area 12, Lateral auditory field, Orbital area 12, Orbitofrontal area 13, Orbitofrontal area 14, Temporopolar area TG, Ventral area 46, area 24

Sub-regions:
Nucleus centralis densocellularis thalami, Nucleus centralis inferior thalami, Nucleus centralis intermedialis thalami, Nucleus centralis latocellularis thalami

---

Region: Nucleus centralis latocellularis thalami (Clc)

Super-regions:
Nucleus centralis latocellularis thalami < Cortical amygdaloid nucleus < Midline nuclei of the thalamus < Thalamus < Diencephalon < Brain

Sources:
area 24

Targets:
Agranular frontal area 3 (= SMA-proper), Agranular frontal area 7 (= rostral dorsolateral premotor area), Area 10, Area 11, Area 32, Frontal eye field, Orbital area 12, Orbitofrontal area 13, Orbitofrontal area 14, area 24

Region: Nucleus centralis intermedialis thalami (Cim)

Super-regions:
Nucleus centralis intermedialis thalami < Cortical

amygdaloid nucleus < Midline nuclei of the thalamus < Thalamus < Diencephalon < Brain

Sources:
Amygdala, Orbitofrontal area 13, area 24

Targets:
Area 32, Lateral area 12, Orbital area 12, Orbitofrontal area 14

Region: Nucleus centralis inferior thalami (Cif)

Super-regions:
Nucleus centralis inferior thalami < Cortical amygdaloid nucleus < Midline nuclei of the thalamus < Thalamus < Diencephalon < Brain

Sources:
Amygdala, Orbitofrontal area 13a, area 24

Targets:
Area 11, Area 32, Area 8B, Lateral area 12, Lateral auditory field, Orbital area 12, Orbitofrontal area 14, Ventral area 46

Region: Nucleus centralis densocellularis thalami (Cdc)

Super-regions:
Nucleus centralis densocellularis thalami < Cortical amygdaloid nucleus < Midline nuclei of the thalamus < Thalamus < Diencephalon < Brain

Sources:
Amygdala, area 24

Targets:
Agranular frontal area 3 (= SMA-proper), Agranular frontal area 7 (= rostral dorsolateral premotor area), Area 11, Area 12, Area 32, Area 8B, Cortical area 46, Fascia dentata hippocampi, Lateral area 12, Lateral auditory field, Orbital area 12, Orbitofrontal area 13, Orbitofrontal area 14, Temporopolar area TG, area 24

Region: Metathalamus (Geniculate Nucleii) (GN)

Super-regions:
Metathalamus (Geniculate Nucleii) < Thalamus < Diencephalon < Brain

Descendant sources:
Caudal inferior parietal lobule, Extrastriate area OA, Lateral auditory parakoniocortex, Medial basal nucleus of the amygdala, Nucleus pulvinaris thalami, Secondary auditory cortex, Superior temporal area 3, Temporal parietooccipital associated area in superior temporal sulcus, Temporoparietal asscociated area (caudal part), Temporoparietal associated area (rostral part), Temporopolar area TG, Visual area 2

Descendant targets:
Area 10, Area 6 (ventral part), Area 6 (ventral part), Area 8A, Caudal auditory parakoniocortex, Caudal inferior parietal lobule, Insula, Lateral auditory field, Medial premotor area 6M, Nucleus paraventricularis thalami, Posterior inferotemporal area, Primary auditory cortex, Superior temporal area 1, Superior temporal area 2, Superior temporal area 3, Superior temporal sulcus, Temporal parietooccipital associated area in superior temporal sulcus, Ventral area 46, Visual area 1, Visual area 2, auditory prokoniocortex

Sub-regions:
Corpus geniculatum mediale, Lateral Geniculate Nucleus

Region: Corpus geniculatum mediale (MG)

Super-regions:

Corpus geniculatum mediale < Metathalamus (Geniculate Nucleii) < Thalamus < Diencephalon < Brain

Sources:
Caudal inferior parietal lobule, Lateral auditory parakoniocortex, Secondary auditory cortex, Superior temporal area 3, Temporal parietooccipital associated area in superior temporal sulcus, Temporoparietal asscociated area (caudal part), Temporoparietal associated area (rostral part), Temporopolar area TG

Targets:
Area 10, Area 8A, Caudal auditory parakoniocortex, Insula, Lateral auditory field, Medial premotor area 6M, Nucleus paraventricularis thalami, Primary auditory cortex, Superior temporal area 1, Superior temporal area 2, Superior temporal area 3, Superior temporal sulcus, Temporal parietooccipital associated area in superior temporal sulcus, Ventral area 46, auditory prokoniocortex

---
Region: Lateral Geniculate Nucleus (LGN)

Super-regions:
Lateral Geniculate Nucleus < Metathalamus (Geniculate Nucleii) < Thalamus < Diencephalon < Brain

Sources:
Extrastriate area OA, Medial basal nucleus of the amygdala, Nucleus pulvinaris thalami, Visual area 2

Targets:
Area 6 (ventral part), Area 6 (ventral part), Caudal inferior parietal lobule, Posterior inferotemporal area, Visual area 1, Visual area 2

Region: Intralaminar nuclei of the thalamus (IL#2)

Super-regions:
Intralaminar nuclei of the thalamus < Thalamus < Diencephalon < Brain

Sources:
Caudal and medial superior parietal lobule

Descendant sources:
Agranular frontal area 2 (= caudal dorsolateral premotor area), Agranular frontal area 3 (= SMA-proper), Agranular frontal area 7 (= rostral dorsolateral premotor area), Area 7, Area 8, Caudal and medial superior parietal lobule, Cortical area 46, Dorsal prelunate gyrus, Frontal eye field, Inferior parietal lobule (lateral posterior cortex below the intraparietal sulcus), Insula, Intraparietal sulcus associated area in the superior temporal sulcus, Middle temporal area, Midpart of the inferior parietal lobule, Orbitofrontal area 13, Parietal area PE (cingulate part), Parietal area PG, medial part, Premotor area 6 (dorsal part), Primary motor area, Primary motor cortex M1, forelimb area, Primary motor cortex M1, hindlimb area, Temporal parietooccipital associated area in superior temporal sulcus, Temporoparietal asscociated area (caudal part), Temporopolar area TG, V4 transitional area, Visual area 2, Visual area 4, area 24, body representation of MI as defined in KSI03

Targets:
Agranular frontal area 2 (= caudal dorsolateral premotor area), Agranular frontal area 3 (= SMA-proper), Agranular frontal area 6 (= pre-SMA), Agranular frontal area 7 (= rostral dorsolateral premotor area), Area 11, Area 32, Area 8B, Dorsal area 46, Lateral area 12, Orbital area 12, Orbitofrontal area 14, Ventral area 46, Visual area 1

Descendant targets:
Agranular frontal area 2 (= caudal dorsolateral premotor area), Agranular frontal area 3 (= SMA-proper), Agranular frontal area 4 (= caudal ventrolateral premotor area), Agranular frontal area 5 (= rostral ventrolateral premotor area), Agranular frontal area 6 (= pre-SMA), Agranular frontal area 7 (= rostral dorsolateral premotor area), Area 1, Area 10, Area 11, Area 12, Area 32, Area 6, Area 6 (ventral part), Area 8B, Caudal and medial superior parietal lobule, Caudal inferior parietal lobule, Cortical area 45, Cortical area 46, Dorsal area 46, Fascia dentata hippocampi, Frontal eye field, Inferotemporal area TE, Insula, Lateral area 12, Lateral intraparietal area,

Medial intraparietal area, Medial premotor area 6M, Midpart of the inferior parietal lobule, Motor area 4c, Occipitoparietal area, Orbital area 12, Orbitofrontal area 13, Orbitofrontal area 13a, Orbitofrontal area 14, Parietal area PG, medial part, Postcentral area 3a, Posterior inferotemporal area, Posteromedial agranular insular cortex, Premotor area 6 (dorsal part), Primary motor area, Primary motor cortex M1, forelimb area, Primary motor cortex M1, hindlimb area, Primary sensory area PC, Rostral inferior parietal lobule, Rostral superior parietal lobule, Temporal parietooccipital associated area in superior temporal sulcus, Temporopolar area TG, Ventral area 46, area 24, body representation of MI as defined in KSI03, superior parietal lobule (posterior dorsomedial parietal cortex above the intraparietal sulcus)

Sub-regions:
Central amygdaloid nucleus, lateral part, Centrum medianum thalami, Nucleus paracentralis thalami, Nucleus parafascicularis thalami

---
Region: Nucleus parafascicularis thalami (Pf#2)

Super-regions:
Nucleus parafascicularis thalami < Intralaminar nuclei of the thalamus < Thalamus < Diencephalon < Brain

Sources:
Agranular frontal area 7 (= rostral dorsolateral premotor area), Area 8, Frontal eye field, Insula, Premotor area 6 (dorsal part), area 24

Targets:
Agranular frontal area 5 (= rostral ventrolateral premotor area), Agranular frontal area 7 (= rostral dorsolateral premotor area), Area 11, Area 12, Area 32, Caudal inferior parietal lobule, Cortical area 45, Cortical area 46, Fascia dentata hippocampi, Inferotemporal area TE, Insula, Lateral area 12, Lateral intraparietal area, Medial premotor area 6M, Occipitoparietal area, Orbital area 12, Orbitofrontal area 13, Orbitofrontal area 14, Posterior inferotemporal area, Posteromedial agranular insular cortex, Premotor area 6 (dorsal part), Primary motor area, Temporal parietooccipital associated area in superior temporal sulcus, Temporopolar area TG, Ventral area 46, area 24

Region: Nucleus paracentralis thalami (Pcn)

Super-regions:
Nucleus paracentralis thalami < Intralaminar nuclei of the thalamus < Thalamus < Diencephalon < Brain

Sources:
Agranular frontal area 7 (= rostral dorsolateral premotor area), Area 8, Cortical area 46, Dorsal prelunate gyrus, Inferior parietal lobule (lateral posterior cortex below the intraparietal sulcus), Intraparietal sulcus associated area in the superior temporal sulcus, Midpart of the inferior parietal lobule, Premotor area 6 (dorsal part), Temporal parietooccipital associated area in superior temporal sulcus, Temporoparietal asscociated area (caudal part), V4 transitional area, Visual area 2, Visual area 4, area 24

Targets:
Agranular frontal area 2 (= caudal dorsolateral premotor area), Agranular frontal area 3 (= SMA-proper), Agranular frontal area 4 (= caudal ventrolateral premotor area), Agranular frontal area 5 (= rostral ventrolateral premotor area), Agranular frontal area 6 (= pre-SMA), Agranular frontal area 7 (= rostral dorsolateral premotor area), Area 10, Area 11, Area 12, Area 32, Area 6, Area 6 (ventral part), Area 8B, Cortical area 46, Dorsal area 46, Fascia dentata hippocampi, Frontal eye field, Inferotemporal area TE, Insula, Lateral area 12, Medial premotor area 6M, Midpart of the inferior parietal lobule, Motor area 4c, Occipitoparietal area, Orbital area 12, Orbitofrontal area 13, Orbitofrontal area 14, Parietal area PG, medial part, Posterior inferotemporal area, Premotor area 6 (dorsal part), Primary motor area, Primary motor cortex M1, forelimb area, Rostral inferior parietal lobule, Temporal parietooccipital associated area in superior temporal

sulcus, Ventral area 46, body representation of MI as defined in KSI03

Region: Centrum medianum thalami (CM#2)

Super-regions:
Centrum medianum thalami < Intralaminar nuclei of the thalamus < Thalamus < Diencephalon < Brain

Sources:
Agranular frontal area 2 (= caudal dorsolateral premotor area), Agranular frontal area 3 (= SMA-proper), Agranular frontal area 7 (= rostral dorsolateral premotor area), Frontal eye field, Insula, Midpart of the inferior parietal lobule, Premotor area 6 (dorsal part), Primary motor area, Primary motor cortex M1, forelimb area, Primary motor cortex M1, hindlimb area, area 24, body representation of MI as defined in KSI03

Targets:
Agranular frontal area 2 (= caudal dorsolateral premotor area), Agranular frontal area 3 (= SMA-proper), Agranular frontal area 4 (= caudal ventrolateral premotor area), Agranular frontal area 5 (= rostral ventrolateral premotor area), Agranular frontal area 6 (= pre-SMA), Agranular frontal area 7 (= rostral dorsolateral premotor area), Area 1, Area 12, Area 32, Area 6, Area 6 (ventral part), Caudal and medial superior parietal lobule, Caudal inferior parietal lobule, Cortical area 45, Cortical area 46, Fascia dentata hippocampi, Lateral area 12, Medial intraparietal area, Medial premotor area 6M, Motor area 4c, Orbitofrontal area 13, Postcentral area 3a, Premotor area 6 (dorsal part), Primary motor area, Primary motor cortex M1, forelimb area, Primary motor cortex M1, hindlimb area, Primary sensory area PC, Rostral inferior parietal lobule, Rostral superior parietal lobule, Temporal parietooccipital associated area in superior temporal sulcus, body representation of MI as defined in KSI03

Region: Central amygdaloid nucleus, lateral part (Cl#2)

Super-regions:
Central amygdaloid nucleus, lateral part < Intralaminar nuclei of the thalamus < Thalamus < Diencephalon < Brain

Sources:
Agranular frontal area 2 (= caudal dorsolateral premotor area), Agranular frontal area 3 (= SMA-proper), Area 7, Caudal and medial superior parietal lobule, Dorsal prelunate gyrus, Frontal eye field, Inferior parietal lobule (lateral posterior cortex below the intraparietal sulcus), Middle temporal area, Midpart of the inferior parietal lobule, Parietal area PE (cingulate part), Parietal area PG, medial part, Premotor area 6 (dorsal part), Primary motor area, Primary motor cortex M1, forelimb area, Primary motor cortex M1, hindlimb area, Temporal parietooccipital associated area in superior temporal sulcus, Temporoparietal asscociated area (caudal part), Visual area 4

Descendant sources:
Agranular frontal area 7 (= rostral dorsolateral premotor area), Area 7, Caudal and medial superior parietal lobule, Dorsal prelunate gyrus, Frontal eye field, Inferior parietal lobule (lateral posterior cortex below the intraparietal sulcus), Orbitofrontal area 13, Parietal area PG, medial part, Temporopolar area TG, V4 transitional area, Visual area 4, area 24

Targets:
Agranular frontal area 2 (= caudal dorsolateral premotor area), Agranular frontal area 3 (= SMA-proper), Agranular frontal area 4 (= caudal ventrolateral premotor area), Agranular frontal area 5 (= rostral ventrolateral premotor area), Agranular frontal area 6 (= pre-SMA), Agranular frontal area 7 (= rostral dorsolateral premotor area), Area 6, Area 6 (ventral part), Area 8B, Caudal and medial superior parietal lobule, Caudal inferior parietal lobule, Frontal eye field, Lateral area 12, Lateral intraparietal area, Medial intraparietal area, Medial premotor area 6M, Midpart of the inferior parietal lobule, Motor area 4c,

Occipitoparietal area, Parietal area PG, medial part,
Postcentral area 3a, Premotor area 6 (dorsal part),
Primary motor area, Primary motor cortex M1, forelimb area,
Primary motor cortex M1, hindlimb area, Primary sensory
area PC, Rostral inferior parietal lobule, Rostral
superior parietal lobule, Temporal parietooccipital
associated area in superior temporal sulcus, Ventral area
46, body representation of MI as defined in KSI03,
superior parietal lobule (posterior dorsomedial parietal
cortex above the intraparietal sulcus)

Descendant targets:
Agranular frontal area 3 (= SMA-proper), Agranular frontal
area 6 (= pre-SMA), Agranular frontal area 7 (= rostral
dorsolateral premotor area), Area 11, Area 32, Area 8B,
Dorsal area 46, Frontal eye field, Lateral intraparietal
area, Midpart of the inferior parietal lobule,
Occipitoparietal area, Orbitofrontal area 13a,
Orbitofrontal area 14, Parietal area PG, medial part,
Premotor area 6 (dorsal part), Primary motor cortex M1,
forelimb area, area 24

Sub-regions:
Nucleus centralis superior lateralis thalami, Nucleus
centralis superior thalami

Region: Nucleus centralis superior lateralis thalami (Csl)

Super-regions:
Nucleus centralis superior lateralis thalami <
Central amygdaloid nucleus, lateral part <
Intralaminar nuclei of the thalamus < Thalamus <
Diencephalon < Brain

Sources:
Agranular frontal area 7 (= rostral dorsolateral
premotor area), Area 7, Caudal and medial superior
parietal lobule, Dorsal prelunate gyrus, Frontal eye
field, Inferior parietal lobule (lateral posterior
cortex below the intraparietal sulcus), Parietal area
PG, medial part, Temporopolar area TG, V4
transitional area, Visual area 4, area 24

Targets:
Agranular frontal area 3 (= SMA-proper), Agranular
frontal area 6 (= pre-SMA), Agranular frontal area 7
(= rostral dorsolateral premotor area), Area 11, Area
32, Area 8B, Dorsal area 46, Frontal eye field,
Lateral intraparietal area, Midpart of the inferior
parietal lobule, Occipitoparietal area, Orbitofrontal
area 13a, Orbitofrontal area 14, Parietal area PG,
medial part, Premotor area 6 (dorsal part), Primary
motor cortex M1, forelimb area, area 24

Region: Nucleus centralis superior thalami (Cs#2)

Super-regions:
Nucleus centralis superior thalami < Central
amygdaloid nucleus, lateral part < Intralaminar
nuclei of the thalamus < Thalamus <
Diencephalon < Brain

Sources:
Orbitofrontal area 13, area 24

Targets:
Area 11, Area 32, Orbitofrontal area 14

Region: LGN internal magnocellular layer (MI#1)

Super-regions:
LGN internal magnocellular layer < Thalamus <
Diencephalon < Brain

Sources:
Area 7b

Targets:
Area 7b, Parietal area PG, medial part

Region: Posterior Nucleii of Thalamus (PN)

Super-regions:
Posterior Nucleii of Thalamus < Thalamus < Diencephalon < Brain

Sources:
Secondary somatosensory cortex

Descendant sources:
Amygdala, Area 9, Caudal inferior parietal lobule, Cortical area 46, Inferior parietal lobule (lateral posterior cortex below the intraparietal sulcus), Intraparietal sulcus associated area in the superior temporal sulcus, Lateral auditory parakoniocortex, Midpart of the inferior parietal lobule, Orbitofrontal area 13, Secondary auditory cortex, Superior temporal area 3, Temporal parietooccipital associated area in superior temporal sulcus, Temporoparietal asscociated area (caudal part), area 24

Targets:
Orbitofrontal area 13a

Descendant targets:
Agranular frontal area 2 (= caudal dorsolateral premotor area), Agranular frontal area 3 (= SMA-proper), Agranular frontal area 6 (= pre-SMA), Agranular frontal area 7 (= rostral dorsolateral premotor area), Area 10, Area 11, Area 12, Area 32, Area 6 (ventral part), Area 8A, Area 8B, Area 9, Caudal auditory parakoniocortex, Caudal inferior parietal lobule, Cortical area 46, Fascia dentata hippocampi, Inferotemporal area TE, Insula, Lateral area 12, Lateral auditory field, Nucleus paraventricularis thalami, Orbital area 12, Orbitofrontal area 13, Orbitofrontal area 14, Posterior inferotemporal area, Primary auditory cortex, Primary motor cortex M1, forelimb area, Rostral superior parietal lobule, Superior temporal area 1, Superior temporal area 2, Superior temporal area 3, Temporal parietooccipital associated area in superior temporal sulcus, Temporoparietal cortex, Temporopolar area TG, Ventral area 46, area 24

Sub-regions:
Nucleus limitans thalami, Nucleus suprageniculatus thalami

Region: Nucleus suprageniculatus thalami (SG)

Super-regions:
Nucleus suprageniculatus thalami < Posterior Nucleii of Thalamus < Thalamus < Diencephalon < Brain

Sources:
Caudal inferior parietal lobule, Inferior parietal lobule (lateral posterior cortex below the intraparietal sulcus), Lateral auditory parakoniocortex, Midpart of the inferior parietal lobule, Orbitofrontal area 13, Superior temporal area 3, Temporal parietooccipital associated area in superior temporal sulcus, Temporoparietal asscociated area (caudal part)

Targets:
Agranular frontal area 3 (= SMA-proper), Agranular frontal area 6 (= pre-SMA), Agranular frontal area 7 (= rostral dorsolateral premotor area), Area 10, Area 32, Area 8A, Area 8B, Area 9, Caudal auditory parakoniocortex, Caudal inferior parietal lobule, Insula, Lateral area 12, Lateral auditory field, Nucleus paraventricularis thalami, Orbital area 12, Primary auditory cortex, Superior temporal area 3, Temporal parietooccipital associated area in superior temporal sulcus, Temporoparietal cortex, Temporopolar area TG, Ventral area 46

Region: Nucleus limitans thalami (Li)

Super-regions:
Nucleus limitans thalami < Posterior Nucleii of Thalamus < Thalamus < Diencephalon < Brain

Sources:

Amygdala, Area 9, Caudal inferior parietal lobule, Cortical area 46, Intraparietal sulcus associated area in the superior temporal sulcus, Orbitofrontal area 13, Secondary auditory cortex, Superior temporal area 3, Temporal parietooccipital associated area in superior temporal sulcus, Temporoparietal asscociated area (caudal part), area 24

Targets:
Agranular frontal area 2 (= caudal dorsolateral premotor area), Agranular frontal area 3 (= SMA-proper), Agranular frontal area 6 (= pre-SMA), Agranular frontal area 7 (= rostral dorsolateral premotor area), Area 10, Area 11, Area 12, Area 32, Area 6 (ventral part), Area 8A, Area 8B, Area 9, Caudal auditory parakoniocortex, Caudal inferior parietal lobule, Cortical area 46, Fascia dentata hippocampi, Inferotemporal area TE, Insula, Lateral area 12, Orbitofrontal area 13, Orbitofrontal area 14, Posterior inferotemporal area, Primary auditory cortex, Primary motor cortex M1, forelimb area, Rostral superior parietal lobule, Superior temporal area 1, Superior temporal area 2, Temporal parietooccipital associated area in superior temporal sulcus, Temporoparietal cortex, Temporopolar area TG, Ventral area 46, area 24

Region: Nucleus reticularis thalami (Ret)

Super-regions:
Nucleus reticularis thalami < Thalamus < Diencephalon < Brain

Sources:
Agranular frontal area 2 (= caudal dorsolateral premotor area), Agranular frontal area 3 (= SMA-proper), Caudal and medial superior parietal lobule, Extrastriate area OA, Frontal eye field, Inferior parietal lobule (lateral posterior cortex below the intraparietal sulcus), Inferotemporal area TE, Insula, Medial area 12, Midpart of the inferior parietal lobule, Nucleus pulvinaris inferior thalami, Nucleus pulvinaris thalami, Parietal area PE (cingulate part), Parietal area PG, medial part, Posterior inferotemporal area, Premotor area 6 (dorsal part), Primary motor area, Primary motor cortex M1, forelimb area, Primary motor cortex M1, hindlimb area, Rostral superior parietal lobule, Visual area 2, area 24, body representation of MI as defined in KSI03

Targets:
Agranular frontal area 2 (= caudal dorsolateral premotor area), Nucleus medialis dorsalis thalami, Nucleus medialis dorsalis thalami, pars magnocellularis, Nucleus ventralis anterior thalami, pars densocellularis, Nucleus ventralis anterior thalami, pars magnocellularis, Nucleus ventralis anterior thalami, pars parvocellularis, area 24, ventral lateral nucleus (thalamus)

Region: Nucleus pulvinaris thalami (Pul#1)

Super-regions:
Nucleus pulvinaris thalami < Thalamus < Diencephalon < Brain

Sources:
Agranular frontal area 3 (= SMA-proper), Area 6 (ventral part), Area 8A, Cortical area 45, Dorsal visual area 3, Lateral area 12, Medial basal nucleus of the amygdala, Orbitofrontal area 13, Ventral area 46, Ventral visual area 3, Visual area 1, Visual area 2, Visual area 3, Visual area 4, area 24

Descendant sources:
Agranular frontal area 7 (= rostral dorsolateral premotor area), Amygdala, Area 23, Area 35, Area 6 (ventral part), Area 7, Area 9, Caudal and medial superior parietal lobule, Caudal inferior parietal lobule, Cortical area 46, Dorsal prelunate gyrus, Extrastriate area OA, Frontal eye field, Inferior parietal lobule (lateral posterior cortex below the intraparietal sulcus), Inferotemporal area TE, Insula, Intraparietal sulcus associated area in the superior temporal sulcus, LGN layer 2, Lateral auditory parakoniocortex, Medial basal nucleus of the amygdala, Middle temporal area, Midpart of the inferior parietal lobule, Orbitofrontal area 13, Parietal area PE (cingulate part), Parietal area PG, medial part, Posterior inferotemporal area, Primary motor cortex M1, forelimb area,

Primary motor cortex M1, hindlimb area, Receptive field for the foot in Area5, Rostral superior parietal lobule, Secondary auditory cortex, Secondary somatosensory cortex, Superior temporal area 3, Temporal area TF, Temporal area TH, Temporal parietooccipital associated area in superior temporal sulcus, Temporoparietal asscociated area (caudal part), Temporoparietal associated area (rostral part), Temporopolar area TG, V4 transitional area, Ventral visual area 3, Visual area 1, Visual area 2, Visual area 4, Visual area 4 (dorsal part), body representation of MI as defined in KSI03, superior parietal lobule (posterior dorsomedial parietal cortex above the intraparietal sulcus)

Targets:
Agranular frontal area 2 (= caudal dorsolateral premotor area), Agranular frontal area 7 (= rostral dorsolateral premotor area), Area 10, Area 11, Area 20, Area 21, Area 6, Area 6 (ventral part), Area 8, Caudal inferior parietal lobule, Cortical area 45, Extrastriate area OA, Inferotemporal area TE, Lateral Geniculate Nucleus, Lateral area 12, Lateral nucleus (amygdala), dorsal intermediate division, Lateral nucleus (amygdala), ventral division, Medial premotor area 6M, Nucleus reticularis thalami, Orbital area 12, Orbitofrontal area 13, Posterior inferotemporal area, Primary motor area, Temporal area TF, Ventral area 46, Visual area 1, Visual area 2, area 24, superior temporal gyrus

Descendant targets:
Agranular frontal area 2 (= caudal dorsolateral premotor area), Agranular frontal area 3 (= SMA-proper), Agranular frontal area 4 (= caudal ventrolateral premotor area), Agranular frontal area 5 (= rostral ventrolateral premotor area), Agranular frontal area 6 (= pre-SMA), Agranular frontal area 7 (= rostral dorsolateral premotor area), Anterior inferotemporal area (dorsal), Area 10, Area 11, Area 12, Area 20, Area 21, Area 32, Area 6, Area 6 (ventral part), Area 6 (ventral part), Area 7, Area 8A, Area 8B, Area 9, Caudal and medial superior parietal lobule, Caudal auditory parakoniocortex, Caudal inferior parietal lobule, Cortical area 45, Cortical area 46, Cortical area TEm, Dorsal area 46, Extrastriate area OA, Fascia dentata hippocampi, Frontal eye field, Inferotemporal area TE, Insula, LGN layer 2, Lateral area 12, Lateral intraparietal area, Medial intraparietal area, Middle temporal area, Midpart of the inferior parietal lobule, Motor area 4c, Nucleus reticularis thalami, Occipitoparietal area, Orbital area 12, Orbitofrontal area 13, Orbitofrontal area 14, Parietal area PG, medial part, Postcentral area 3a, Postcentral area 3b, Posterior inferotemporal area, Primary auditory cortex, Primary motor area, Primary motor cortex M1, forelimb area, Primary sensory area PC, Receptive field for the foot in Area5, Rostral inferior parietal lobule, Rostral superior parietal lobule, Superior temporal area 1, Superior temporal area 2, Superior temporal sulcus, Temporal area TA, Temporal area TF, Temporal parietooccipital associated area in superior temporal sulcus, Temporoparietal cortex, Temporopolar area TG, Ventral area 46, Visual area 1, Visual area 2, Visual area 3, Visual area 4, area 24, body representation of MI as defined in KSI03, superior parietal lobule (posterior dorsomedial parietal cortex above the intraparietal sulcus)

Sub-regions:
Nucleus pulvinaris inferior thalami, Nucleus pulvinaris medialis thalami, Nucleus pulvinaris oralis thalami, posterior lateral auditory area

---
Region: Nucleus pulvinaris inferior thalami (PI#3)

Super-regions:
Nucleus pulvinaris inferior thalami < Nucleus pulvinaris thalami < Thalamus < Diencephalon < Brain

Sources:
Area 6 (ventral part), Dorsal prelunate gyrus, Extrastriate area OA, Inferotemporal area TE, Intraparietal sulcus associated area in the superior temporal sulcus, Medial basal nucleus of the amygdala, Middle temporal area, Posterior inferotemporal area, V4 transitional area, Ventral visual area 3, Visual area 2, Visual area 4, Visual area 4 (dorsal part)

Descendant sources:
Area 6 (ventral part), Medial basal nucleus of the amygdala, Middle temporal area, Visual area 1

Targets:

Anterior inferotemporal area (dorsal), Area 21, Area 8A, Extrastriate area OA, Inferotemporal area TE, Middle temporal area, Nucleus reticularis thalami, Posterior inferotemporal area, Temporal parietooccipital associated area in superior temporal sulcus, Ventral area 46, Visual area 1, Visual area 2, Visual area 4

Descendant targets:
Area 6 (ventral part), Caudal inferior parietal lobule, Middle temporal area, Visual area 1, Visual area 2, Visual area 4

Sub-regions:
Nucleus pulvinaris inferior thalami, central subdivision, Nucleus pulvinaris inferior thalami, lateral subdivision, Nucleus pulvinaris inferior thalami, pars medialis, Nucleus pulvinaris inferior thalami, pars posterior, Nucleus pulvinaris inferior thalami, shell of the lateral subdivision

---
Region: Nucleus pulvinaris inferior thalami, shell of the lateral subdivision (PIl-s)

Super-regions:
Nucleus pulvinaris inferior thalami, shell of the lateral subdivision < Nucleus pulvinaris inferior thalami < Nucleus pulvinaris thalami < Thalamus < Diencephalon < Brain

Sources:
Visual area 1

Targets:
Visual area 1

Region: Nucleus pulvinaris inferior thalami, pars posterior (PIp)

Super-regions:
Nucleus pulvinaris inferior thalami, pars posterior < Nucleus pulvinaris inferior thalami < Nucleus pulvinaris thalami < Thalamus < Diencephalon < Brain

Sources:
Medial basal nucleus of the amygdala, Middle temporal area

Targets:
Middle temporal area, Visual area 4

Region: Nucleus pulvinaris inferior thalami, pars medialis (PIm)

Super-regions:
Nucleus pulvinaris inferior thalami, pars medialis < Nucleus pulvinaris inferior thalami < Nucleus pulvinaris thalami < Thalamus < Diencephalon < Brain

Sources:
Medial basal nucleus of the amygdala, Middle temporal area, Visual area 1

Targets:
Area 6 (ventral part), Caudal inferior parietal lobule, Middle temporal area, Visual area 2

Region: Nucleus pulvinaris inferior thalami, lateral subdivision (PIl)

Super-regions:
Nucleus pulvinaris inferior thalami, lateral subdivision < Nucleus pulvinaris inferior thalami < Nucleus pulvinaris thalami < Thalamus < Diencephalon < Brain

Sources:
Area 6 (ventral part), Medial basal nucleus of the amygdala, Middle temporal area, Visual area 1

Targets:
Area 6 (ventral part), Middle temporal area, Visual area 1, Visual area 2, Visual area 4

Region: Nucleus pulvinaris inferior thalami, central subdivision (PIc)

Super-regions:
Nucleus pulvinaris inferior thalami, central subdivision < Nucleus pulvinaris inferior thalami < Nucleus pulvinaris thalami < Thalamus < Diencephalon < Brain

Sources:
Area 6 (ventral part), Medial basal nucleus of the amygdala, Middle temporal area, Visual area 1

Targets:
Area 6 (ventral part), Caudal inferior parietal lobule, Middle temporal area, Visual area 2, Visual area 4

Region: Nucleus pulvinaris medialis thalami (PM#3)

Super-regions:
Nucleus pulvinaris medialis thalami < Nucleus pulvinaris thalami < Thalamus < Diencephalon < Brain

Sources:
Agranular frontal area 7 (= rostral dorsolateral premotor area), Amygdala, Area 23, Area 35, Area 6 (ventral part), Area 7, Caudal and medial superior parietal lobule, Dorsal prelunate gyrus, Frontal eye field, Inferior parietal lobule (lateral posterior cortex below the intraparietal sulcus), Inferotemporal area TE, Insula, Intraparietal sulcus associated area in the superior temporal sulcus, Lateral auditory parakoniocortex, Medial basal nucleus of the amygdala, Middle temporal area, Midpart of the inferior parietal lobule, Orbitofrontal area 13, Parietal area PE (cingulate part), Parietal area PG, medial part, Posterior inferotemporal area, Primary motor cortex M1, forelimb area, Primary motor cortex M1, hindlimb area, Rostral superior parietal lobule, Secondary auditory cortex, Superior temporal area 3, Temporal area TF, Temporal area TH, Temporal parietooccipital associated area in superior temporal sulcus, Temporoparietal asscociated area (caudal part), Temporoparietal associated area (rostral part), Temporopolar area TG, V4 transitional area, Ventral visual area 3, Visual area 4, Visual area 4 (dorsal part), body representation of MI as defined in KSI03

Descendant sources:
Area 9, Caudal inferior parietal lobule, Cortical area 46, Inferior parietal lobule (lateral posterior cortex below the intraparietal sulcus), Lateral auditory parakoniocortex, Secondary auditory cortex, Superior temporal area 3

Targets:
Agranular frontal area 2 (= caudal dorsolateral premotor area), Agranular frontal area 3 (= SMA-proper), Agranular frontal area 5 (= rostral ventrolateral premotor area), Agranular frontal area 6 (= pre-SMA), Agranular frontal area 7 (= rostral dorsolateral premotor area), Anterior inferotemporal area (dorsal), Area 10, Area 11, Area 12, Area 20, Area 32, Area 6, Area 8A, Area 8B, Area 9, Caudal auditory parakoniocortex, Caudal inferior parietal lobule, Cortical area 45, Cortical area 46, Cortical area TEm, Dorsal area 46, Fascia dentata hippocampi, Frontal eye field, Inferotemporal area TE, Insula, Lateral area 12, Lateral intraparietal area, Middle temporal area, Midpart of the inferior parietal lobule, Occipitoparietal area, Orbital area 12, Orbitofrontal area 13, Orbitofrontal area 14, Parietal area PG, medial part, Posterior inferotemporal area, Primary auditory cortex, Rostral inferior parietal lobule, Superior temporal area 1, Superior temporal area 2, Superior temporal sulcus, Temporal area TF, Temporal parietooccipital associated area in superior temporal sulcus, Temporoparietal cortex, Temporopolar area TG, Ventral area 46, Visual area 4, area 24, body representation of MI as defined in KSI03

Descendant targets:
Caudal inferior parietal lobule

Sub-regions:
Nucleus pulvinaris medialis thalami, lateral division,
Nucleus pulvinaris medialis thalami, medial division

Region: Nucleus pulvinaris medialis thalami, medial division (PMm)

Super-regions:
Nucleus pulvinaris medialis thalami, medial division < Nucleus pulvinaris medialis thalami < Nucleus pulvinaris thalami < Thalamus < Diencephalon < Brain

Sources:
Area 9, Caudal inferior parietal lobule, Cortical area 46, Inferior parietal lobule (lateral posterior cortex below the intraparietal sulcus), Lateral auditory parakoniocortex, Secondary auditory cortex

Targets:
Caudal inferior parietal lobule

Region: Nucleus pulvinaris medialis thalami, lateral division (PMl)

Super-regions:
Nucleus pulvinaris medialis thalami, lateral division < Nucleus pulvinaris medialis thalami < Nucleus pulvinaris thalami < Thalamus < Diencephalon < Brain

Sources:
Area 9, Caudal inferior parietal lobule, Cortical area 46, Inferior parietal lobule (lateral posterior cortex below the intraparietal sulcus), Lateral auditory parakoniocortex, Secondary auditory cortex, Superior temporal area 3

Targets:
Caudal inferior parietal lobule

Region: Nucleus pulvinaris oralis thalami (Pul.o)

Super-regions:
Nucleus pulvinaris oralis thalami < Nucleus pulvinaris thalami < Thalamus < Diencephalon < Brain

Sources:
Area 7, Caudal and medial superior parietal lobule, Dorsal prelunate gyrus, Inferior parietal lobule (lateral posterior cortex below the intraparietal sulcus), Insula, LGN layer 2, Middle temporal area, Midpart of the inferior parietal lobule, Parietal area PE (cingulate part), Parietal area PG, medial part, Primary motor cortex M1, forelimb area, Receptive field for the foot in Area5, Rostral superior parietal lobule, Secondary somatosensory cortex, Temporal parietooccipital associated area in superior temporal sulcus, Temporoparietal asscociated area (caudal part), Temporoparietal associated area (rostral part), Visual area 2, Visual area 4, Visual area 4 (dorsal part), superior parietal lobule (posterior dorsomedial parietal cortex above the intraparietal sulcus)

Targets:
Agranular frontal area 2 (= caudal dorsolateral premotor area), Agranular frontal area 3 (= SMA-proper), Agranular frontal area 4 (= caudal ventrolateral premotor area), Agranular frontal area 5 (= rostral ventrolateral premotor area), Agranular frontal area 6 (= pre-SMA), Agranular frontal area 7 (= rostral dorsolateral premotor area), Area 6 (ventral part), Caudal and medial superior parietal lobule, LGN layer 2, Medial intraparietal area, Midpart of the inferior parietal lobule, Motor area 4c, Parietal area PG, medial part, Postcentral area 3a, Postcentral area 3b, Primary motor area, Primary motor cortex M1, forelimb area, Primary sensory area PC, Receptive field for the foot in Area5, Rostral inferior parietal lobule, Rostral superior parietal lobule, Superior temporal sulcus,

Temporal parietooccipital associated area in superior temporal sulcus, superior parietal lobule (posterior dorsomedial parietal cortex above the intraparietal sulcus)

Region: posterior lateral auditory area (PL#3)

Super-regions:
posterior lateral auditory area < Nucleus pulvinaris thalami < Thalamus < Diencephalon < Brain

Sources:
Area 6 (ventral part), Area 7, Dorsal prelunate gyrus, Extrastriate area OA, Inferior parietal lobule (lateral posterior cortex below the intraparietal sulcus), Inferotemporal area TE, Medial basal nucleus of the amygdala, Middle temporal area, Midpart of the inferior parietal lobule, Orbitofrontal area 13, Parietal area PE (cingulate part), Parietal area PG, medial part, Posterior inferotemporal area, Temporal parietooccipital associated area in superior temporal sulcus, Temporoparietal asscociated area (caudal part), V4 transitional area, Ventral visual area 3, Visual area 2, Visual area 4, Visual area 4 (dorsal part)

Descendant sources:
Area 9, Cortical area 46, Inferior parietal lobule (lateral posterior cortex below the intraparietal sulcus), Lateral auditory parakoniocortex, Medial basal nucleus of the amygdala, Middle temporal area

Targets:
Anterior inferotemporal area (dorsal), Area 11, Area 6 (ventral part), Area 7, Area 8A, Caudal and medial superior parietal lobule, Caudal auditory parakoniocortex, Caudal inferior parietal lobule, Cortical area 45, Cortical area TEm, Inferotemporal area TE, Lateral intraparietal area, Medial intraparietal area, Middle temporal area, Midpart of the inferior parietal lobule, Parietal area PG, medial part, Posterior inferotemporal area, Primary auditory cortex, Rostral inferior parietal lobule, Rostral superior parietal lobule, Temporal area TA, Temporal parietooccipital associated area in superior temporal sulcus, Temporoparietal cortex, Temporopolar area TG, Ventral area 46, Visual area 1, Visual area 2, Visual area 3, Visual area 4, superior parietal lobule (posterior dorsomedial parietal cortex above the intraparietal sulcus)

Descendant targets:
Caudal inferior parietal lobule, Middle temporal area, Visual area 1, Visual area 2, Visual area 4

Sub-regions:
Nucleus pulvinaris lateralis thalami pars alpha, Nucleus pulvinaris lateralis thalami pars ventrolateralis, Nucleus pulvinaris lateralis thalami pars ventromedialis, Nucleus pulvinaris lateralis thalami, dorsal division

---

Region: Nucleus pulvinaris lateralis thalami pars alpha (PLa#1)

Super-regions:
Nucleus pulvinaris lateralis thalami pars alpha < posterior lateral auditory area < Nucleus pulvinaris thalami < Thalamus < Diencephalon < Brain

Sources:
Medial basal nucleus of the amygdala

Targets:
Visual area 1

Region: Nucleus pulvinaris lateralis thalami, dorsal division (PLd)

Super-regions:
Nucleus pulvinaris lateralis thalami, dorsal division < posterior lateral auditory area < Nucleus pulvinaris thalami < Thalamus < Diencephalon < Brain

Sources:
Area 9, Cortical area 46, Inferior parietal lobule (lateral posterior cortex below the intraparietal sulcus), Lateral auditory parakoniocortex

Targets:
Caudal inferior parietal lobule

Region: Nucleus pulvinaris lateralis thalami pars ventrolateralis (PLvl)

Super-regions:
Nucleus pulvinaris lateralis thalami pars ventrolateralis < posterior lateral auditory area < Nucleus pulvinaris thalami < Thalamus < Diencephalon < Brain

Sources:
Middle temporal area

Targets:
Middle temporal area, Visual area 1, Visual area 2, Visual area 4

Region: Nucleus pulvinaris lateralis thalami pars ventromedialis (PLvm)

Super-regions:
Nucleus pulvinaris lateralis thalami pars ventromedialis < posterior lateral auditory area < Nucleus pulvinaris thalami < Thalamus < Diencephalon < Brain

Sources:
Middle temporal area

Targets:
Middle temporal area, Visual area 1, Visual area 2, Visual area 4

Region: Nucleus medialis dorsalis thalami (MD)

Super-regions:
Nucleus medialis dorsalis thalami < Thalamus < Diencephalon < Brain

Sources:
Accessory basal amygdaloid nucleus, parvicellular part, Agranular frontal area 2 (= caudal dorsolateral premotor area), Agranular frontal area 3 (= SMA-proper), Agranular frontal area 7 (= rostral dorsolateral premotor area), Agranular insula, Amygdala, Area 10, Area 11, Area 12, Area 23, Area 25, Area 32, Area 35, Area 36, Area 6, Area 8, Area 9, Caudal and medial superior parietal lobule, Cortical area 45, Cortical area 46, Dysgranular insular cortex, Entorhinal cortex, Frontal eye field, Globus pallidus external part, Gustatory cortex, Hippocampus, Inferior parietal lobule (lateral posterior cortex below the intraparietal sulcus), Inferotemporal area TE, LGN external magnocellular layer, Lateral auditory field, Medial basal nucleus of the amygdala, Midpart of the inferior parietal lobule, Nucleus basalis thalami, Nucleus peripeduncularis thalami, Nucleus reticularis thalami, Olfactory Complex, Orbitofrontal area 13, Orbitofrontal area 13a, Orbitofrontal area 14, Orbitofrontal cortex, agranular periallocortical, Parietal area PG, medial part, Premotor area 6 (dorsal part), Primary motor area, Primary motor cortex M1, forelimb area, Primary motor cortex M1, hindlimb area, Primary sensory cortex, Pro motor area, Secondary auditory cortex, Temporal area TF, Temporal area TH, Temporal parietooccipital associated area in superior temporal sulcus, Temporal proisocortex, Temporoparietal asscociated area (caudal part), Temporoparietal associated area (rostral part), Temporopolar area TG, accessory basal nucleus (amygdala), magnocellular subdivision, amygdalohippocampal area, anterior amygdaloid area, area 24, body representation of MI as defined in KSI03, central nucleus of the amygdala, cortical nucleus, anterior division, cortical nucleus, posterior division, periamygdaloid cortex, ventral striatal shell

Descendant sources:

Accessory basal amygdaloid nucleus, parvicellular part, Agranular frontal area 7 (= rostral dorsolateral premotor area), Agranular insula, Amygdala, Area 10, Area 11, Area 12, Area 32, Area 35, Area 36, Area 8, Area 9, Basolateral nucleus of amygdala, Caudal inferior parietal lobule, Cortical area 45, Cortical area 46, Entorhinal cortex, Frontal eye field, Insula, Lateral auditory field, Medial agranular insular cortex, Medial basal nucleus of the amygdala, Nucleus basalis thalami, Nucleus reticularis thalami, Orbitofrontal area 13, Orbitofrontal area 13a, Orbitofrontal area 14, Premotor area 6 (dorsal part), Primary sensory cortex, Temporopolar area TG, Ventolateral Nucleii of Thalamus, accessory basal nucleus (amygdala), magnocellular subdivision, amygdalohippocampal area, area 24

Targets:
Agranular frontal area 2 (= caudal dorsolateral premotor area), Agranular frontal area 3 (= SMA-proper), Agranular frontal area 4 (= caudal ventrolateral premotor area), Agranular frontal area 5 (= rostral ventrolateral premotor area), Agranular frontal area 6 (= pre-SMA), Agranular frontal area 7 (= rostral dorsolateral premotor area), Area 10, Area 11, Area 12, Area 25, Area 32, Area 6, Area 6 (ventral part), Area 8A, Area 8B, Area 9, Cortical area 45, Cortical area 46, Dorsal area 46, Frontal eye field, Gustatory cortex, Intermediate agranula insular cortex, Lateral agranular insular cortex, Lateral area 12, Medial agranular insular cortex, Medial premotor area 6M, Motor area 4c, Orbital area 12, Orbitofrontal area 13, Orbitofrontal area 13a, Orbitofrontal area 14, Precentral opercular area, Premotor area 6 (dorsal part), Primary motor area, Primary motor cortex M1, forelimb area, Primary motor cortex M1, hindlimb area, Primary sensory area PC, Temporal parietooccipital associated area in superior temporal sulcus, Ventral area 46, area 24, body representation of MI as defined in KSI03

Descendant targets:
Agranular frontal area 3 (= SMA-proper), Agranular frontal area 4 (= caudal ventrolateral premotor area), Agranular frontal area 7 (= rostral dorsolateral premotor area), Area 10, Area 11, Area 12, Area 25, Area 32, Area 6, Area 8, Area 8A, Area 8B, Area 9, Caudal and medial superior parietal lobule, Caudal inferior parietal lobule, Cortical area 45, Cortical area 46, Dorsal area 46, Fascia dentata hippocampi, Insula, Intermediate agranula insular cortex, Lateral agranular insular cortex, Lateral area 12, Lateral intraparietal area, Medial agranular insular cortex, Medial intraparietal area, Medial premotor area 6M, Midpart of the inferior parietal lobule, Occipitoparietal area, Orbital area 12, Orbitofrontal area 13, Orbitofrontal area 13a, Orbitofrontal area 14, Parietal area PG, medial part, Precentral opercular area, Premotor area 6 (dorsal part), Primary motor area, Primary motor cortex M1, forelimb area, Rostral inferior parietal lobule, Rostral superior parietal lobule, Temporopolar area TG, Ventral area 46, area 24

Sub-regions:
Nucleus medialis dorsalis thalami, pars caudodorsalis, Nucleus medialis dorsalis thalami, pars densocellularis, Nucleus medialis dorsalis thalami, pars lateralis, Nucleus medialis dorsalis thalami, pars magnocellularis

---

Region: Nucleus medialis dorsalis thalami, pars densocellularis (MDdc)

Super-regions:
Nucleus medialis dorsalis thalami, pars densocellularis < Nucleus medialis dorsalis thalami < Thalamus < Diencephalon < Brain

Sources:
Area 9, Caudal inferior parietal lobule

Targets:
Agranular frontal area 7 (= rostral dorsolateral premotor area), Area 11, Area 32, Area 8B, Caudal inferior parietal lobule, Cortical area 46, Dorsal area 46, Fascia dentata hippocampi, Lateral area 12, Medial premotor area 6M, Orbital area 12, Orbitofrontal area 14, Parietal area PG, medial part, Premotor area 6 (dorsal part), Primary motor area, Primary motor cortex M1, forelimb area, Rostral superior parietal lobule, Temporopolar area TG, area 24

Region: Nucleus medialis dorsalis thalami, pars caudodorsalis (MDcd)

Super-regions:
Nucleus medialis dorsalis thalami, pars caudodorsalis < Nucleus medialis dorsalis thalami < Thalamus < Diencephalon < Brain

Sources:
Area 32

Targets:
Area 32, Intermediate agranula insular cortex, Orbitofrontal area 14, area 24

Region: Nucleus medialis dorsalis thalami, pars lateralis (MDl)

Super-regions:
Nucleus medialis dorsalis thalami, pars lateralis < Nucleus medialis dorsalis thalami < Thalamus < Diencephalon < Brain

Descendant sources:
Agranular frontal area 7 (= rostral dorsolateral premotor area), Area 10, Area 32, Area 8, Area 9, Cortical area 45, Cortical area 46, Frontal eye field, Insula, Premotor area 6 (dorsal part), Temporopolar area TG, area 24

Targets:
Area 12, Area 8A, Area 8B, Area 9, Cortical area 45, Cortical area 46

Descendant targets:
Agranular frontal area 3 (= SMA-proper), Agranular frontal area 4 (= caudal ventrolateral premotor area), Agranular frontal area 7 (= rostral dorsolateral premotor area), Area 11, Area 12, Area 32, Area 6, Area 8A, Area 8B, Area 9, Caudal and medial superior parietal lobule, Caudal inferior parietal lobule, Cortical area 46, Dorsal area 46, Fascia dentata hippocampi, Insula, Lateral area 12, Lateral intraparietal area, Medial intraparietal area, Medial premotor area 6M, Midpart of the inferior parietal lobule, Occipitoparietal area, Orbital area 12, Orbitofrontal area 14, Parietal area PG, medial part, Premotor area 6 (dorsal part), Primary motor area, Rostral inferior parietal lobule, Ventral area 46, area 24

Sub-regions:
Nucleus medialis dorsalis thalami, pars multiformis, Nucleus medialis dorsalis thalami, pars parvocellularis

---

Region: Nucleus medialis dorsalis thalami, pars parvocellularis (MDpc)

Super-regions:
Nucleus medialis dorsalis thalami, pars parvocellularis < Nucleus medialis dorsalis thalami, pars lateralis < Nucleus medialis dorsalis thalami < Thalamus < Diencephalon < Brain

Sources:
Agranular frontal area 7 (= rostral dorsolateral premotor area), Area 10, Area 32, Area 9, Cortical area 46, Frontal eye field, Insula, Premotor area 6 (dorsal part), Temporopolar area TG, area 24

Targets:
Agranular frontal area 3 (= SMA-proper), Agranular frontal area 4 (= caudal ventrolateral premotor area), Agranular frontal area 7 (= rostral dorsolateral premotor area), Area 11, Area 12, Area 32, Area 6, Area 8A, Area 8B, Area 9, Caudal inferior parietal lobule, Cortical area 46, Dorsal area 46, Fascia dentata hippocampi, Insula, Lateral area 12, Lateral intraparietal area, Medial intraparietal area, Medial premotor area 6M, Midpart of the inferior parietal lobule, Orbital area 12, Orbitofrontal area 14, Parietal area PG, medial part, Premotor area 6 (dorsal part), Primary motor area, Rostral inferior parietal lobule, Ventral area 46, area 24

Region: Nucleus medialis dorsalis thalami, pars multiformis (MDmf)

Super-regions:
Nucleus medialis dorsalis thalami, pars multiformis < Nucleus medialis dorsalis thalami, pars lateralis < Nucleus medialis dorsalis thalami < Thalamus < Diencephalon < Brain

Sources:
Agranular frontal area 7 (= rostral dorsolateral premotor area), Area 8, Cortical area 45, Premotor area 6 (dorsal part)

Targets:
Agranular frontal area 7 (= rostral dorsolateral premotor area), Area 11, Area 12, Area 8A, Area 8B, Caudal and medial superior parietal lobule, Lateral area 12, Medial premotor area 6M, Midpart of the inferior parietal lobule, Occipitoparietal area, Premotor area 6 (dorsal part), Rostral inferior parietal lobule, Ventral area 46

Region: Nucleus medialis dorsalis thalami, pars magnocellularis (MDmc)

Super-regions:
Nucleus medialis dorsalis thalami, pars magnocellularis < Nucleus medialis dorsalis thalami < Thalamus < Diencephalon < Brain

Sources:
Accessory basal amygdaloid nucleus, parvicellular part, Agranular insula, Amygdala, Area 10, Area 12, Area 32, Area 35, Area 36, Basolateral nucleus of amygdala, Cortical area 45, Entorhinal cortex, Insula, Lateral auditory field, Medial basal nucleus of the amygdala, Nucleus basalis thalami, Nucleus reticularis thalami, Orbitofrontal area 13, Orbitofrontal area 13a, Orbitofrontal area 14, Primary sensory cortex, Temporopolar area TG, Ventolateral Nucleii of Thalamus, accessory basal nucleus (amygdala), magnocellular subdivision, amygdalohippocampal area, area 24

Descendant sources:
Area 11, Entorhinal cortex, Medial agranular insular cortex, Nucleus basalis thalami, Orbitofrontal area 13

Targets:
Area 11, Area 12, Area 25, Area 32, Area 6, Area 8, Area 9, Cortical area 46, Fascia dentata hippocampi, Lateral area 12, Orbital area 12, Orbitofrontal area 13, Orbitofrontal area 14, Ventral area 46

Descendant targets:
Area 10, Area 11, Area 12, Area 6, Area 8, Area 9, Cortical area 45, Cortical area 46, Intermediate agranula insular cortex, Lateral agranular insular cortex, Medial agranular insular cortex, Orbital area 12, Orbitofrontal area 13, Orbitofrontal area 13a, Orbitofrontal area 14, Precentral opercular area, area 24

Sub-regions:
Nucleus medialis dorsalis thalami, pars fibrosa, Nucleus medialis dorsalis thalami, pars paramediana

---
Region: Nucleus medialis dorsalis thalami, pars paramediana (MDpm)

Super-regions:
Nucleus medialis dorsalis thalami, pars paramediana < Nucleus medialis dorsalis thalami, pars magnocellularis < Nucleus medialis dorsalis thalami < Thalamus < Diencephalon < Brain

Sources:
Entorhinal cortex, Medial agranular insular cortex, Nucleus basalis thalami, Orbitofrontal area 13

Targets:
Intermediate agranula insular cortex, Medial agranular insular cortex, Orbital area 12, Orbitofrontal area 13, Orbitofrontal area 13a, Orbitofrontal area 14

Region: Nucleus medialis dorsalis thalami, pars fibrosa (MDfi)

Super-regions:
Nucleus medialis dorsalis thalami, pars fibrosa < Nucleus medialis dorsalis thalami, pars magnocellularis < Nucleus medialis dorsalis thalami < Thalamus < Diencephalon < Brain

Sources:
Area 11, Entorhinal cortex, Medial agranular insular cortex, Nucleus basalis thalami, Orbitofrontal area 13

Targets:
Area 10, Area 11, Area 12, Area 6, Area 8, Area 9, Cortical area 45, Cortical area 46, Intermediate agranula insular cortex, Lateral agranular insular cortex, Medial agranular insular cortex, Orbital area 12, Orbitofrontal area 13, Orbitofrontal area 13a, Precentral opercular area, area 24

Region: Ventolateral Nucleii of Thalamus (VN)

Super-regions:
Ventolateral Nucleii of Thalamus < Thalamus < Diencephalon < Brain

Descendant sources:
Agranular frontal area 2 (= caudal dorsolateral premotor area), Agranular frontal area 3 (= SMA-proper), Agranular frontal area 4 (= caudal ventrolateral premotor area), Agranular frontal area 5 (= rostral ventrolateral premotor area), Agranular frontal area 6 (= pre-SMA), Agranular frontal area 7 (= rostral dorsolateral premotor area), Area 1, Area 23, Area 23c, Area 24a, Area 24b, Area 24c (rostral part of the cingulate sulcus), Area 24d (rostral part of the cingulate sulcus), Area 32, Area 6 (ventral part), Area 7, Area 8, Area 9, Caudal and medial superior parietal lobule, Cortical area 46, Dorsal prelunate gyrus, Frontal eye field, Inferior parietal lobule (lateral posterior cortex below the intraparietal sulcus), Insula, LGN layer 2, Lateral area 12, Medial area 12, Medial premotor area 6M, Midpart of the inferior parietal lobule, Nucleus reticularis thalami, Orbital area 12, Orbitofrontal area 13, Orbitofrontal area 13a, Orbitofrontal area 14, Parietal area PE (cingulate part), Parietal area PG, medial part, Postcentral area 3a, Postcentral area 3b, Precentral opercular area, Premotor area 6 (dorsal part), Primary motor area, Primary motor cortex M1, forelimb area, Primary motor cortex M1, hindlimb area, Receptive field for the foot in Area5, Rostral superior parietal lobule, Secondary somatosensory cortex, Temporal area TH, Ventral visual area 3, Visual area 2, Visual area 4, Visual area 4 (dorsal part), area 24, body representation of MI as defined in KSI03, superior parietal lobule (posterior dorsomedial parietal cortex above the intraparietal sulcus)

Targets:
Agranular frontal area 2 (= caudal dorsolateral premotor area), Agranular frontal area 3 (= SMA-proper), Agranular frontal area 5 (= rostral ventrolateral premotor area), Agranular frontal area 6 (= pre-SMA), Agranular frontal area 7 (= rostral dorsolateral premotor area), Nucleus medialis dorsalis thalami, pars magnocellularis, Primary motor area

Descendant targets:
Agranular frontal area 2 (= caudal dorsolateral premotor area), Agranular frontal area 3 (= SMA-proper), Agranular frontal area 4 (= caudal ventrolateral premotor area), Agranular frontal area 5 (= rostral ventrolateral premotor area), Agranular frontal area 6 (= pre-SMA), Agranular frontal area 7 (= rostral dorsolateral premotor area), Area 1, Area 10, Area 11, Area 12, Area 23c, Area 24b, Area 24d (rostral part of the cingulate sulcus), Area 32, Area 6, Area 6 (ventral part), Area 8A, Area 8B, Area 9, Caudal and medial superior parietal lobule, Caudal inferior parietal lobule, Cortical area 45, Cortical area 46, Dorsal area 46, Dysgranular insular cortex, Fascia dentata hippocampi, Frontal eye field, Gustatory cortex, Inferotemporal area TE, Insula, LGN layer 2, Lateral area 12, Lateral intraparietal area, Medial intraparietal area, Medial premotor area 6M, Midpart of the inferior parietal lobule, Motor area 4c, Occipitoparietal area, Orbital area 12,

Orbitofrontal area 13, Orbitofrontal area 14, Parietal area PG, medial part, Postcentral area 3a, Postcentral area 3b, Posterior inferotemporal area, Posteromedial agranular insular cortex, Precentral opercular area, Premotor area 6 (dorsal part), Primary motor area, Primary motor cortex M1, forelimb area, Primary motor cortex M1, hindlimb area, Primary sensory area PC, Primary somatosensory cortex, Receptive field for the foot in Area5, Rostral area 14, Rostral inferior parietal lobule, Rostral superior parietal lobule, Secondary somatosensory cortex, Temporal parietooccipital associated area in superior temporal sulcus, Ventral area 46, body representation of MI as defined in KSI03, superior parietal lobule (posterior dorsomedial parietal cortex above the intraparietal sulcus)

Sub-regions:
Area X (thalamus), Ventral posterior area, ventral anterior nucleus (thalamus), ventral lateral nucleus (thalamus)

Region: Area X (thalamus) (X)

Super-regions:
Area X (thalamus) < Ventolateral Nucleii of Thalamus < Thalamus < Diencephalon < Brain

Sources:
Agranular frontal area 2 (= caudal dorsolateral premotor area), Agranular frontal area 7 (= rostral dorsolateral premotor area), Cortical area 46, Midpart of the inferior parietal lobule, Premotor area 6 (dorsal part), Primary motor area, Primary motor cortex M1, forelimb area

Targets:
Agranular frontal area 2 (= caudal dorsolateral premotor area), Agranular frontal area 3 (= SMA-proper), Agranular frontal area 4 (= caudal ventrolateral premotor area), Agranular frontal area 5 (= rostral ventrolateral premotor area), Agranular frontal area 6 (= pre-SMA), Agranular frontal area 7 (= rostral dorsolateral premotor area), Area 32, Area 6, Area 6 (ventral part), Area 8B, Cortical area 45, Cortical area 46, Lateral intraparietal area, Medial premotor area 6M, Motor area 4c, Orbital area 12, Orbitofrontal area 14, Premotor area 6 (dorsal part), Primary motor area, Primary motor cortex M1, forelimb area, Ventral area 46

Region: Ventral posterior area (VP#2)

Super-regions:
Ventral posterior area < Ventolateral Nucleii of Thalamus < Thalamus < Diencephalon < Brain

Sources:
Primary motor cortex M1, forelimb area

Descendant sources:
Agranular frontal area 3 (= SMA-proper), Area 1, Area 23, Area 6 (ventral part), Area 7, Area 8, Caudal and medial superior parietal lobule, Dorsal prelunate gyrus, Inferior parietal lobule (lateral posterior cortex below the intraparietal sulcus), Insula, LGN layer 2, Midpart of the inferior parietal lobule, Parietal area PE (cingulate part), Parietal area PG, medial part, Postcentral area 3a, Postcentral area 3b, Premotor area 6 (dorsal part), Primary motor area, Primary motor cortex M1, forelimb area, Primary motor cortex M1, hindlimb area, Receptive field for the foot in Area5, Rostral superior parietal lobule, Secondary somatosensory cortex, Temporal area TH, Ventral visual area 3, Visual area 2, Visual area 4, body representation of MI as defined in KSI03, superior parietal lobule (posterior dorsomedial parietal cortex above the intraparietal sulcus)

Descendant targets:
Agranular frontal area 2 (= caudal dorsolateral premotor area), Agranular frontal area 3 (= SMA-proper), Agranular frontal area 4 (= caudal ventrolateral premotor area), Agranular frontal area 5 (= rostral ventrolateral premotor area), Agranular frontal area 6 (= pre-SMA), Agranular frontal area 7 (= rostral dorsolateral premotor area), Area 1, Area 6, Area 6 (ventral part), Area 8A, Caudal and medial superior parietal lobule, Caudal inferior parietal

lobule, Cortical area 46, Dysgranular insular cortex, Gustatory cortex, Insula, LGN layer 2, Lateral intraparietal area, Medial intraparietal area, Medial premotor area 6M, Midpart of the inferior parietal lobule, Motor area 4c, Occipitoparietal area, Parietal area PG, medial part, Postcentral area 3a, Postcentral area 3b, Posteromedial agranular insular cortex, Premotor area 6 (dorsal part), Primary motor area, Primary motor cortex M1, forelimb area, Primary sensory area PC, Primary somatosensory cortex, Receptive field for the foot in Area5, Rostral inferior parietal lobule, Rostral superior parietal lobule, Secondary somatosensory cortex, Temporal parietooccipital associated area in superior temporal sulcus, Ventral area 46, body representation of MI as defined in KSI03, superior parietal lobule (posterior dorsomedial parietal cortex above the intraparietal sulcus)

Sub-regions:
Nucleus ventralis posterior inferior thalami, Nucleus ventralis posterior medialis thalami, Ventral posterior lateral nucleus (thalamus), Ventroposterior superior nucleus thalami

---
Region: Ventroposterior superior nucleus thalami (VPS)

Super-regions:
Ventroposterior superior nucleus thalami < Ventral posterior area < Ventolateral Nucleii of Thalamus < Thalamus < Diencephalon < Brain

Sources:
Area 1, LGN layer 2, superior parietal lobule (posterior dorsomedial parietal cortex above the intraparietal sulcus)

Targets:
Area 1, LGN layer 2, Postcentral area 3a, superior parietal lobule (posterior dorsomedial parietal cortex above the intraparietal sulcus)

Region: Nucleus ventralis posterior inferior thalami (VPI)

Super-regions:
Nucleus ventralis posterior inferior thalami < Ventral posterior area < Ventolateral Nucleii of Thalamus < Thalamus < Diencephalon < Brain

Sources:
Insula, Midpart of the inferior parietal lobule, Primary motor area, Secondary somatosensory cortex

Targets:
Agranular frontal area 2 (= caudal dorsolateral premotor area), Agranular frontal area 4 (= caudal ventrolateral premotor area), Agranular frontal area 5 (= rostral ventrolateral premotor area), Insula, Medial premotor area 6M, Primary motor area, Rostral inferior parietal lobule, Temporal parietooccipital associated area in superior temporal sulcus

---
Region: Nucleus ventralis posterior medialis thalami (VPM)

Super-regions:
Nucleus ventralis posterior medialis thalami < Ventral posterior area < Ventolateral Nucleii of Thalamus < Thalamus < Diencephalon < Brain

Sources:
Insula, Midpart of the inferior parietal lobule, Postcentral area 3b, Primary motor area

Targets:
Agranular frontal area 2 (= caudal dorsolateral premotor area), Agranular frontal area 4 (= caudal ventrolateral premotor area), Agranular frontal area 5 (= rostral ventrolateral premotor area), Area 1, Area 6 (ventral part), Gustatory cortex, Insula, Medial premotor area 6M, Postcentral area 3a, Postcentral area 3b, Posteromedial agranular insular cortex,

Primary motor area, Primary motor cortex M1, forelimb area, Primary sensory area PC, Rostral inferior parietal lobule, Secondary somatosensory cortex

---

Region: Ventral posterior lateral nucleus (thalamus) (VPL)

Super-regions:
Ventral posterior lateral nucleus (thalamus) < Ventral posterior area < Ventolateral Nucleii of Thalamus < Thalamus < Diencephalon < Brain

Sources:
Agranular frontal area 3 (= SMA-proper), Area 1, Area 23, Area 6 (ventral part), Area 7, Caudal and medial superior parietal lobule, Dorsal prelunate gyrus, Inferior parietal lobule (lateral posterior cortex below the intraparietal sulcus), LGN layer 2, Midpart of the inferior parietal lobule, Parietal area PE (cingulate part), Parietal area PG, medial part, Premotor area 6 (dorsal part), Primary motor area, Primary motor cortex M1, forelimb area, Primary motor cortex M1, hindlimb area, Receptive field for the foot in Area5, Rostral superior parietal lobule, Temporal area TH, Ventral visual area 3, Visual area 2, Visual area 4, body representation of MI as defined in KSI03, superior parietal lobule (posterior dorsomedial parietal cortex above the intraparietal sulcus)

Descendant sources:
Agranular frontal area 3 (= SMA-proper), Area 1, Area 8, Caudal and medial superior parietal lobule, Inferior parietal lobule (lateral posterior cortex below the intraparietal sulcus), LGN layer 2, Postcentral area 3a, Postcentral area 3b, Primary motor area, Primary motor cortex M1, forelimb area, Rostral superior parietal lobule, Secondary somatosensory cortex

Targets:
Agranular frontal area 2 (= caudal dorsolateral premotor area), Agranular frontal area 3 (= SMA-proper), Agranular frontal area 4 (= caudal ventrolateral premotor area), Agranular frontal area 6 (= pre-SMA), Agranular frontal area 7 (= rostral dorsolateral premotor area), Area 1, Area 6 (ventral part), Area 8A, Caudal and medial superior parietal lobule, Caudal inferior parietal lobule, Cortical area 46, LGN layer 2, Lateral intraparietal area, Medial intraparietal area, Medial premotor area 6M, Midpart of the inferior parietal lobule, Occipitoparietal area, Parietal area PG, medial part, Postcentral area 3a, Postcentral area 3b, Premotor area 6 (dorsal part), Primary motor area, Primary motor cortex M1, forelimb area, Primary sensory area PC, Primary somatosensory cortex, Receptive field for the foot in Area5, Rostral inferior parietal lobule, Rostral superior parietal lobule, Temporal parietooccipital associated area in superior temporal sulcus, Ventral area 46, body representation of MI as defined in KSI03, superior parietal lobule (posterior dorsomedial parietal cortex above the intraparietal sulcus)

Descendant targets:
Agranular frontal area 2 (= caudal dorsolateral premotor area), Agranular frontal area 3 (= SMA-proper), Agranular frontal area 4 (= caudal ventrolateral premotor area), Agranular frontal area 5 (= rostral ventrolateral premotor area), Agranular frontal area 6 (= pre-SMA), Agranular frontal area 7 (= rostral dorsolateral premotor area), Area 1, Area 6, Area 6 (ventral part), Caudal and medial superior parietal lobule, Dysgranular insular cortex, LGN layer 2, Lateral intraparietal area, Medial intraparietal area, Medial premotor area 6M, Midpart of the inferior parietal lobule, Motor area 4c, Occipitoparietal area, Postcentral area 3a, Postcentral area 3b, Premotor area 6 (dorsal part), Primary motor area, Primary motor cortex M1, forelimb area, Primary sensory area PC, Primary somatosensory cortex, Rostral inferior parietal lobule, Rostral superior parietal lobule, Secondary somatosensory cortex, superior parietal lobule (posterior dorsomedial parietal cortex above the intraparietal sulcus)

Sub-regions:
Nucleus ventralis posterior lateralis thalami, pars caudalis, Nucleus ventralis posterior lateralis thalami, pars oralis

---
Region: Nucleus ventralis posterior lateralis thalami, pars oralis (VPLo)

Super-regions:
Nucleus ventralis posterior lateralis thalami, pars oralis < Ventral posterior lateral nucleus (thalamus) < Ventral posterior area < Ventolateral Nucleii of Thalamus < Thalamus < Diencephalon < Brain

Sources:
Agranular frontal area 3 (= SMA-proper), Area 8, Postcentral area 3b, Primary motor area, Primary motor cortex M1, forelimb area

Targets:
Agranular frontal area 2 (= caudal dorsolateral premotor area), Agranular frontal area 3 (= SMA-proper), Agranular frontal area 4 (= caudal ventrolateral premotor area), Agranular frontal area 5 (= rostral ventrolateral premotor area), Agranular frontal area 6 (= pre-SMA), Agranular frontal area 7 (= rostral dorsolateral premotor area), Area 6, Area 6 (ventral part), Medial premotor area 6M, Motor area 4c, Postcentral area 3a, Premotor area 6 (dorsal part), Primary motor area, Primary motor cortex M1, forelimb area, Rostral superior parietal lobule

---
Region: Nucleus ventralis posterior lateralis thalami, pars caudalis (VPLc)

Super-regions:
Nucleus ventralis posterior lateralis thalami, pars caudalis < Ventral posterior lateral nucleus (thalamus) < Ventral posterior area < Ventolateral Nucleii of Thalamus < Thalamus < Diencephalon < Brain

Sources:
Agranular frontal area 3 (= SMA-proper), Area 1, Caudal and medial superior parietal lobule, Inferior parietal lobule (lateral posterior cortex below the intraparietal sulcus), LGN layer 2, Postcentral area 3a, Postcentral area 3b, Primary motor area, Primary motor cortex M1, forelimb area, Rostral superior parietal lobule, Secondary somatosensory cortex

Targets:
Area 1, Caudal and medial superior parietal lobule, Dysgranular insular cortex, LGN layer 2, Lateral intraparietal area, Medial intraparietal area, Midpart of the inferior parietal lobule, Occipitoparietal area, Postcentral area 3a, Postcentral area 3b, Primary motor area, Primary motor cortex M1, forelimb area, Primary sensory area PC, Primary somatosensory cortex, Rostral inferior parietal lobule, Rostral superior parietal lobule, Secondary somatosensory cortex, superior parietal lobule (posterior dorsomedial parietal cortex above the intraparietal sulcus)

Region: ventral lateral nucleus (thalamus) (VL)

Super-regions:
ventral lateral nucleus (thalamus) < Ventolateral Nucleii of Thalamus < Thalamus < Diencephalon < Brain

Sources:
Area 7, Caudal and medial superior parietal lobule, Nucleus reticularis thalami, Parietal area PG, medial part, Primary motor cortex M1, forelimb area, Primary motor cortex M1, hindlimb area, area 24, body representation of

MI as defined in KSI03

Descendant sources:
Agranular frontal area 2 (= caudal dorsolateral premotor area), Agranular frontal area 3 (= SMA-proper), Agranular frontal area 4 (= caudal ventrolateral premotor area), Agranular frontal area 5 (= rostral ventrolateral premotor area), Agranular frontal area 6 (= pre-SMA), Agranular frontal area 7 (= rostral dorsolateral premotor area), Area 23, Area 23c, Area 24b, Area 24d (rostral part of the cingulate sulcus), Area 7, Area 8, Area 9, Cortical area 46, Frontal eye field, Inferior parietal lobule (lateral posterior cortex below the intraparietal sulcus), Lateral area 12, Medial premotor area 6M, Midpart of the inferior parietal lobule, Orbital area 12, Orbitofrontal area 13, Parietal area PE (cingulate part), Parietal area PG, medial part, Precentral opercular area, Premotor area 6 (dorsal part), Primary motor area, Primary motor cortex M1, forelimb area, Rostral superior parietal lobule, Visual area 4 (dorsal part)

Targets:
Area 11, Area 32, Area 8B, Lateral area 12, Orbital area 12, Orbitofrontal area 14, Primary motor cortex M1, forelimb area, Primary motor cortex M1, hindlimb area, Ventral area 46, body representation of MI as defined in KSI03

Descendant targets:
Agranular frontal area 2 (= caudal dorsolateral premotor area), Agranular frontal area 3 (= SMA-proper), Agranular frontal area 4 (= caudal ventrolateral premotor area), Agranular frontal area 5 (= rostral ventrolateral premotor area), Agranular frontal area 6 (= pre-SMA), Agranular frontal area 7 (= rostral dorsolateral premotor area), Area 23c, Area 24d (rostral part of the cingulate sulcus), Area 6, Area 6 (ventral part), Area 8B, Caudal and medial superior parietal lobule, Caudal inferior parietal lobule, Cortical area 45, Cortical area 46, Lateral intraparietal area, Medial intraparietal area, Medial premotor area 6M, Motor area 4c, Occipitoparietal area, Orbitofrontal area 14, Parietal area PG, medial part, Premotor area 6 (dorsal part), Primary motor area, Primary motor cortex M1, forelimb area, Primary sensory area PC, Rostral inferior parietal lobule, Rostral superior parietal lobule, superior parietal lobule (posterior dorsomedial parietal cortex above the intraparietal sulcus)

Sub-regions:
Nucleus ventralis lateralis thalami, pars caudalis, Nucleus ventralis lateralis thalami, pars medialis, Nucleus ventralis lateralis thalami, pars oralis, Nucleus ventralis lateralis thalami, pars postrema

---
Region: Nucleus ventralis lateralis thalami, pars medialis (VLm)

Super-regions:
Nucleus ventralis lateralis thalami, pars medialis < ventral lateral nucleus (thalamus) < Ventolateral Nucleii of Thalamus < Thalamus < Diencephalon < Brain

Sources:
Agranular frontal area 2 (= caudal dorsolateral premotor area), Agranular frontal area 3 (= SMA-proper), Area 9, Cortical area 46, Midpart of the inferior parietal lobule, Orbitofrontal area 13, Premotor area 6 (dorsal part), Primary motor area

Targets:
Agranular frontal area 2 (= caudal dorsolateral premotor area), Agranular frontal area 3 (= SMA-proper), Agranular frontal area 4 (= caudal ventrolateral premotor area), Agranular frontal area 5 (= rostral ventrolateral premotor area), Agranular frontal area 6 (= pre-SMA), Agranular frontal area 7 (= rostral dorsolateral premotor area), Area 6, Area 6 (ventral part), Area 8B, Cortical area 45, Cortical area 46, Medial premotor area 6M, Motor area 4c, Orbitofrontal area 14, Premotor area 6 (dorsal part), Primary motor area, Primary motor cortex M1, forelimb area

---

Region: Nucleus ventralis lateralis thalami, pars postrema (VLps)

Super-regions:
Nucleus ventralis lateralis thalami, pars postrema < ventral lateral nucleus (thalamus) < Ventolateral Nucleii of Thalamus < Thalamus < Diencephalon < Brain

Sources:
Agranular frontal area 3 (= SMA-proper), Area 7, Parietal area PG, medial part, Premotor area 6 (dorsal part), Primary motor area, Visual area 4 (dorsal part)

Targets:
Agranular frontal area 2 (= caudal dorsolateral premotor area), Agranular frontal area 3 (= SMA-proper), Agranular frontal area 6 (= pre-SMA), Agranular frontal area 7 (= rostral dorsolateral premotor area), Caudal and medial superior parietal lobule, Caudal inferior parietal lobule, Cortical area 46, Lateral intraparietal area, Medial intraparietal area, Medial premotor area 6M, Occipitoparietal area, Parietal area PG, medial part, Primary motor area, Rostral superior parietal lobule, superior parietal lobule (posterior dorsomedial parietal cortex above the intraparietal sulcus)

Region: Nucleus ventralis lateralis thalami, pars oralis (VLo)

Super-regions:
Nucleus ventralis lateralis thalami, pars oralis < ventral lateral nucleus (thalamus) < Ventolateral Nucleii of Thalamus < Thalamus < Diencephalon < Brain

Sources:
Agranular frontal area 2 (= caudal dorsolateral premotor area), Agranular frontal area 3 (= SMA-proper), Agranular frontal area 4 (= caudal ventrolateral premotor area), Agranular frontal area 5 (= rostral ventrolateral premotor area), Agranular frontal area 6 (= pre-SMA), Area 23c, Area 24b, Area 24d (rostral part of the cingulate sulcus), Area 8, Area 9, Frontal eye field, Lateral area 12, Medial premotor area 6M, Midpart of the inferior parietal lobule, Orbital area 12, Precentral opercular area, Premotor area 6 (dorsal part), Primary motor area, Primary motor cortex M1, forelimb area

Targets:
Agranular frontal area 2 (= caudal dorsolateral premotor area), Agranular frontal area 3 (= SMA-proper), Agranular frontal area 4 (= caudal ventrolateral premotor area), Agranular frontal area 5 (= rostral ventrolateral premotor area), Agranular frontal area 6 (= pre-SMA), Agranular frontal area 7 (= rostral dorsolateral premotor area), Area 23c, Area 24d (rostral part of the cingulate sulcus), Area 6 (ventral part), Cortical area 45, Medial premotor area 6M, Motor area 4c, Premotor area 6 (dorsal part), Primary motor area, Primary motor cortex M1, forelimb area

---
Region: Nucleus ventralis lateralis thalami, pars caudalis (VLc)

Super-regions:
Nucleus ventralis lateralis thalami, pars caudalis < ventral lateral nucleus (thalamus) < Ventolateral Nucleii of Thalamus < Thalamus < Diencephalon < Brain

Sources:
Agranular frontal area 2 (= caudal dorsolateral premotor area), Agranular frontal area 3 (= SMA-proper), Agranular frontal area 7 (= rostral dorsolateral premotor area), Area 23, Cortical area 46, Frontal eye field, Inferior parietal lobule (lateral posterior cortex below the intraparietal sulcus), Midpart of the inferior parietal lobule, Parietal area PE (cingulate part), Premotor area 6

(dorsal part), Primary motor area, Primary motor cortex M1, forelimb area, Rostral superior parietal lobule

Targets:
Agranular frontal area 2 (= caudal dorsolateral premotor area), Agranular frontal area 3 (= SMA-proper), Agranular frontal area 4 (= caudal ventrolateral premotor area), Agranular frontal area 5 (= rostral ventrolateral premotor area), Agranular frontal area 6 (= pre-SMA), Agranular frontal area 7 (= rostral dorsolateral premotor area), Area 6, Area 6 (ventral part), Caudal inferior parietal lobule, Medial premotor area 6M, Motor area 4c, Occipitoparietal area, Parietal area PG, medial part, Premotor area 6 (dorsal part), Primary motor area, Primary motor cortex M1, forelimb area, Primary sensory area PC, Rostral inferior parietal lobule, Rostral superior parietal lobule

---
Region: ventral anterior nucleus (thalamus) (VA)

Super-regions:
ventral anterior nucleus (thalamus) < Ventolateral Nucleii of Thalamus < Thalamus < Diencephalon < Brain

Sources:
Agranular frontal area 2 (= caudal dorsolateral premotor area), Agranular frontal area 3 (= SMA-proper), Area 9, Cortical area 46, Frontal eye field, Medial area 12, Premotor area 6 (dorsal part), area 24

Descendant sources:
Agranular frontal area 5 (= rostral ventrolateral premotor area), Agranular frontal area 6 (= pre-SMA), Agranular frontal area 7 (= rostral dorsolateral premotor area), Area 24a, Area 24b, Area 24c (rostral part of the cingulate sulcus), Area 24d (rostral part of the cingulate sulcus), Area 32, Area 8, Area 9, Cortical area 46, Frontal eye field, Lateral area 12, Nucleus reticularis thalami, Orbital area 12, Orbitofrontal area 13a, Orbitofrontal area 14, Premotor area 6 (dorsal part), Primary motor cortex M1, forelimb area, Primary motor cortex M1, hindlimb area, area 24, body representation of MI as defined in KSI03

Targets:
Agranular frontal area 2 (= caudal dorsolateral premotor area), Agranular frontal area 3 (= SMA-proper), Agranular frontal area 6 (= pre-SMA), Agranular frontal area 7 (= rostral dorsolateral premotor area), Area 10, Area 11, Area 12, Area 32, Area 6, Area 6 (ventral part), Area 8B, Area 9, Caudal inferior parietal lobule, Cortical area 46, Dorsal area 46, Fascia dentata hippocampi, Frontal eye field, Lateral area 12, Medial premotor area 6M, Orbital area 12, Orbitofrontal area 13, Orbitofrontal area 14, Premotor area 6 (dorsal part), Primary motor area, Ventral area 46

Descendant targets:
Agranular frontal area 2 (= caudal dorsolateral premotor area), Agranular frontal area 3 (= SMA-proper), Agranular frontal area 4 (= caudal ventrolateral premotor area), Agranular frontal area 5 (= rostral ventrolateral premotor area), Agranular frontal area 6 (= pre-SMA), Agranular frontal area 7 (= rostral dorsolateral premotor area), Area 11, Area 23c, Area 24b, Area 24d (rostral part of the cingulate sulcus), Area 32, Area 6 (ventral part), Area 9, Cortical area 45, Cortical area 46, Dorsal area 46, Frontal eye field, Inferotemporal area TE, Insula, Lateral area 12, Medial premotor area 6M, Orbital area 12, Orbitofrontal area 13, Orbitofrontal area 14, Posterior inferotemporal area, Precentral opercular area, Premotor area 6 (dorsal part), Primary motor area, Primary motor cortex M1, forelimb area, Primary motor cortex M1, hindlimb area, Rostral area 14, Ventral area 46, body representation of MI as defined in KSI03

Sub-regions:
Nucleus ventralis anterior thalami, pars densocellularis, Nucleus ventralis anterior thalami, pars magnocellularis, Nucleus ventralis anterior thalami, pars parvocellularis

---
Region: Nucleus ventralis anterior thalami, pars parvocellularis (VApc)

Super-regions:
Nucleus ventralis anterior thalami, pars parvocellularis < ventral anterior nucleus (thalamus) < Ventolateral Nucleii of Thalamus < Thalamus < Diencephalon < Brain

Sources:
Agranular frontal area 7 (= rostral dorsolateral premotor area), Nucleus reticularis thalami, Premotor area 6 (dorsal part)

Targets:
Agranular frontal area 2 (= caudal dorsolateral premotor area), Agranular frontal area 3 (= SMA-proper), Agranular frontal area 4 (= caudal ventrolateral premotor area), Agranular frontal area 5 (= rostral ventrolateral premotor area), Agranular frontal area 6 (= pre-SMA), Agranular frontal area 7 (= rostral dorsolateral premotor area), Area 23c, Area 24b, Area 24d (rostral part of the cingulate sulcus), Area 6 (ventral part), Area 9, Cortical area 45, Frontal eye field, Medial premotor area 6M, Precentral opercular area, Premotor area 6 (dorsal part), Primary motor area, Rostral area 14

Region: Nucleus ventralis anterior thalami, pars densocellularis (VAdc)

Super-regions:
Nucleus ventralis anterior thalami, pars densocellularis < ventral anterior nucleus (thalamus) < Ventolateral Nucleii of Thalamus < Thalamus < Diencephalon < Brain

Sources:
Nucleus reticularis thalami, Primary motor cortex M1, forelimb area, Primary motor cortex M1, hindlimb area, body representation of MI as defined in KSI03

Targets:
Primary motor cortex M1, forelimb area, Primary motor cortex M1, hindlimb area, body representation of MI as defined in KSI03

Region: Nucleus ventralis anterior thalami, pars magnocellularis (VAmc)

Super-regions:
Nucleus ventralis anterior thalami, pars magnocellularis < ventral anterior nucleus (thalamus) < Ventolateral Nucleii of Thalamus < Thalamus < Diencephalon < Brain

Sources:
Agranular frontal area 5 (= rostral ventrolateral premotor area), Agranular frontal area 6 (= pre-SMA), Agranular frontal area 7 (= rostral dorsolateral premotor area), Area 24a, Area 24b, Area 24c (rostral part of the cingulate sulcus), Area 24d (rostral part of the cingulate sulcus), Area 32, Area 8, Area 9, Cortical area 46, Frontal eye field, Lateral area 12, Nucleus reticularis thalami, Orbital area 12, Orbitofrontal area 13a, Orbitofrontal area 14, area 24

Targets:
Agranular frontal area 5 (= rostral ventrolateral premotor area), Agranular frontal area 6 (= pre-SMA), Agranular frontal area 7 (= rostral dorsolateral premotor area), Area 11, Area 32, Area 9, Cortical area 45, Cortical area 46, Dorsal area 46, Frontal eye field, Inferotemporal area TE, Insula, Lateral area 12, Orbital area 12, Orbitofrontal area 13, Orbitofrontal area 14, Posterior inferotemporal area, Premotor area 6 (dorsal part), Rostral area 14, Ventral area 46

Region: GM-CerebralCortex (Cx)

Super-regions:
GM-CerebralCortex < Brain

Descendant sources:
Accessor basal nucleus (amygdala), ventromedial division, Accessory basal amygdaloid nucleus, dorsal division, Accessory basal amygdaloid nucleus, parvicellular part, Accessory basal amygdaloid nucleus, ventral division, Agranular area of temporal polar cortex, Agranular frontal area 2 (= caudal dorsolateral premotor area), Agranular frontal area 3 (= SMA-proper), Agranular frontal area 4 (= caudal ventrolateral premotor area), Agranular frontal area 5 (= rostral ventrolateral premotor area), Agranular frontal area 6 (= pre-SMA), Agranular frontal area 7 (= rostral dorsolateral premotor area), Agranular insula, Amygdala, Anterior inferotemporal area (dorsal), Anterior inferotemporal area (ventral), Anterior intraparietal area, Anterior medial nucleus, Anterior nuclei of the thalamus, Area 1, Area 10, Area 11, Area 12, Area 20, Area 21, Area 23, Area 23a, Area 23b, Area 23c, Area 24a, Area 24b, Area 24c (rostral part of the cingulate sulcus), Area 24d (rostral part of the cingulate sulcus), Area 25, Area 26, Area 29, Area 29d, Area 3, Area 31, Area 32, Area 35, Area 36, Area 46 (dorsal rim of the principal sulcus), Area 46 (fundus of the principal sulcus), Area 46 (ventral rim of the principal sulcus), Area 6, Area 6 (ventral part), Area 6 (ventral part), Area 7, Area 7a, Area 7b, Area 8, Area 8A, Area 8B, Area 9, Area X (thalamus), Basal amygdaloid nucleus, intermediate part, Basal amygdaloid nucleus, ventral lateral division, Basolateral nucleus of amygdala, CA1 subfield of Ammon`s horn, CA3 subfield of Ammons horn, Caudal and medial superior parietal lobule, Caudal area 8A, Caudal auditory parakoniocortex, Caudal inferior parietal lobule, Caudal limiting field of entorhinal cortex, Caudal parietal operculum, Caudal part of area 36, Caudomedial lobule, Central amygdaloid nucleus, lateral part, Central inferotemporal area, Central inferotemporal area (dorsal), Central inferotemporal area (ventral), Centrum medianum thalami, Cingulate motor areas, Claustrum, Corpus geniculatum mediale, Cortical amygdaloid nucleus, Cortical area 29a-c, Cortical area 36p, Cortical area 44, Cortical area 45, Cortical area 45A, Cortical area 45B, Cortical area 46, Cortical area 9\/46d, Cortical area 9\/46v, Cortical area OAa, Cortical area PGa, Cortical area TEm, Dorsal area 10, Dorsal area 46, Dorsal dysgranular area of temporal polar cortex, Dorsal portion of area 8A, Dorsal prelunate gyrus, Dorsal visual area 3, Dysgranular Temporopolar Cortex, Dysgranular insular cortex, Entorhinal cortex, Entorhinal cortex, Extrastriate area OA, Fascia dentata hippocampi, Floor of superior temporal sulcus, Frontal eye field, Granular area of temporal polar cortex, Granular insular cortex, Gustatory cortex, Hippocampus, Hypothalamus, Inferior parietal lobule (lateral posterior cortex below the intraparietal sulcus), Inferotemporal area TE, Insula, Insular proisocortex, Intermediate agranula insular cortex, Intermediate field of entorhinal cortex, Intralaminar nuclei of the thalamus, Intraparietal sulcus associated area in the superior temporal sulcus, LGN external magnocellular layer, LGN internal magnocellular layer, LGN layer 2, Lateral Geniculate Nucleus, Lateral agranular insular cortex, Lateral area 11, Lateral area 12, Lateral area 9, Lateral auditory field, Lateral auditory field, Lateral auditory parakoniocortex, Lateral field (caudal part) of entorhinal cortex, Lateral field (rostral part) of entorhinal cortex, Lateral field of entorhinal cortex, Lateral intraparietal area, Lateral intraparietal area (external part), Lateral intraparietal area (internal part), Lateral nucleus (amygdala), dorsal division, Laterodorsal nucleus (thalamus), Medial agranular insular cortex, Medial area 10, Medial area 11, Medial area 12, Medial area 9, Medial basal nucleus of the amygdala, Medial basal nucleus of the amygdala, Medial intraparietal area, Medial premotor area 6M, Medial superior temporal area, Medial superior temporal area (dorsal), Medial superior temporal area (posterior), Middle temporal area, Midline nuclei of the thalamus, Midpart of the inferior parietal lobule, Motor area 4a, Motor area 4b, Motor area 4c, Nucleus anterior ventralis thalami, Nucleus basalis thalami, Nucleus centralis densocellularis thalami, Nucleus centralis inferior thalami, Nucleus centralis intermedialis thalami, Nucleus centralis latocellularis thalami, Nucleus centralis superior lateralis thalami, Nucleus centralis superior thalami, Nucleus dorsalis tegmenti, Nucleus limitans thalami, Nucleus medialis dorsalis thalami, Nucleus medialis dorsalis thalami, pars caudodorsalis, Nucleus medialis dorsalis thalami, pars densocellularis, Nucleus medialis dorsalis thalami, pars fibrosa, Nucleus medialis dorsalis thalami, pars lateralis, Nucleus medialis dorsalis thalami, pars magnocellularis, Nucleus medialis dorsalis thalami, pars multiformis, Nucleus medialis dorsalis thalami, pars paramediana, Nucleus medialis dorsalis thalami, pars parvocellularis, Nucleus of the lateral olfactory tract, Nucleus paracentralis thalami, Nucleus parafascicularis thalami, Nucleus parataenialis thalami, Nucleus paraventricularis thalami, Nucleus paraventricularis thalami, pars anterior, Nucleus peripeduncularis thalami, Nucleus pulvinaris inferior thalami, Nucleus pulvinaris inferior thalami, Nucleus pulvinaris inferior thalami, central subdivision, Nucleus pulvinaris inferior thalami, lateral subdivision, Nucleus pulvinaris inferior thalami, pars medialis, Nucleus pulvinaris inferior thalami, pars posterior, Nucleus pulvinaris inferior thalami, shell of the lateral subdivision, Nucleus pulvinaris lateralis thalami pars alpha, Nucleus pulvinaris lateralis thalami pars ventrolateralis, Nucleus pulvinaris lateralis thalami pars ventromedialis,

Nucleus pulvinaris lateralis thalami, dorsal division, Nucleus pulvinaris medialis thalami, Nucleus pulvinaris medialis thalami, lateral division, Nucleus pulvinaris medialis thalami, medial division, Nucleus pulvinaris oralis thalami, Nucleus pulvinaris thalami, Nucleus pulvinaris thalami, pars oralis, Nucleus reticularis thalami, Nucleus reuniens thalami, Nucleus subthalamicus, Nucleus supragenicularus thalami, Nucleus ventralis anterior thalami, pars densocellularis, Nucleus ventralis anterior thalami, pars magnocellularis, Nucleus ventralis anterior thalami, pars parvocellularis, Nucleus ventralis lateralis thalami, pars caudalis, Nucleus ventralis lateralis thalami, pars medialis, Nucleus ventralis lateralis thalami, pars oralis, Nucleus ventralis lateralis thalami, pars postrema, Nucleus ventralis posterior inferior thalami, Nucleus ventralis posterior lateralis thalami, pars caudalis, Nucleus ventralis posterior lateralis thalami, pars oralis, Nucleus ventralis posterior medialis thalami, Occipitoparietal area, Olfactory Complex, Olfactory field of entorhinal cortex, Orbital area 10, Orbital area 12, Orbital part of area 14, Orbital prefrontal cortex, Orbitofrontal area 13, Orbitofrontal area 13, lateral part, Orbitofrontal area 13, medial part, Orbitofrontal area 13a, Orbitofrontal area 14, Orbitofrontal cortex, agranular periallocortical, Orbitofrontal opercular area, Parahippocampal cortex, Parasubiculum, Parietal area PE (cingulate part), Parietal area PG, medial part, Periamygdaloid cortex 2, Peripheral part of area MT, Piriform cortex, Postcentral area 3a, Postcentral area 3b, Posterior Nucleii of Thalamus, Posterior inferotemporal area, Posterior inferotemporal area (dorsal), Posterior inferotemporal area (ventral), Posterior intraparietal area, Posterior parietal area, Posteromedial agranular insular cortex, Precentral opercular area, Prefrontal area 47\/12, Premotor area 6 (dorsal part), Premotor area 6Va, Premotor area 6Vb, Premotor area 6b-beta, Presubiculum, Primary auditory cortex, Primary motor area, Primary motor cortex M1, forelimb area, Primary motor cortex M1, hindlimb area, Primary sensory area PC, Primary sensory cortex, Primary somatosensory cortex, Principal Sulcus, Pro motor area, Prostriate cortex, Putamen; rostral, Retroinsular area, Retrosplenial area 30, Rostral area 12, Rostral area 14, Rostral field of entorhinal cortex, Rostral inferior parietal lobule, Rostral parietal operculum, Rostral part of area 36, Rostral superior parietal lobule, SMA - caudal part, SMA - rostral part, Secondary auditory cortex, Secondary somatosensory cortex, Subiculum, body portion, Subiculum, uncal portion, Superior temporal area 1, Superior temporal area 2, Superior temporal area 3, Superior temporal sulcus, Superior temporal sulcus, dorsal, Supplementary motor cortex M2, forelimb area, Supplementary motor cortex M2, hindlimb area, Supratemporal cortex, granular, Temporal area TA, Temporal area TAa, Temporal area TF, Temporal area TF (lateral part), Temporal area TF (medial part), Temporal area TH, Temporal parietooccipital associated area in superior temporal sulcus, Temporal proisocortex, Temporoparietal asscociated area (caudal part), Temporoparietal associated area (intermediate part), Temporoparietal associated area (rostral part), Temporoparietal cortex, Temporopolar area TG, Thalamus, Transitional sensory area, V4 transitional area, Ventolateral Nucleii of Thalamus, Ventral area 10, Ventral area 46, Ventral dysgranular area of temporal polar cortex, Ventral intraparietal area, Ventral occipitotemporal area, Ventral posterior lateral nucleus (thalamus), Ventral posterior parietal area, Ventral visual area 3, Ventroposterior superior nucleus thalami, Visual area 1, Visual area 2, Visual area 3, Visual area 3A, Visual area 4, Visual area 4 (dorsal part), Visual area 4 (ventral part), Visual area V6A, accessory basal nucleus (amygdala), magnocellular subdivision, amygdalohippocampal area, anterior amygdaloid area, anterior lateral auditory belt, area 24, area dentata (dentate gyrus), auditory prokoniocortex, belt line of the sensory system according to CP99, belt line of the sensorymotor system according to CP99, caudal lateral auditory (belt), central nucleus of the amygdala, cortical nucleus (amygdala), cortical nucleus, anterior division, cortical nucleus, posterior division, dorsal area 9, dorsointermediate visual field, dorsolateral visual cortex, caudal part, dorsolateral visual cortex, rostral part, face representation in SII as defined in DLRPK03, lateral nucleus (amygdala), ventrolateral subdivision, medial entorhinal cortex, orofacial representation in MI, periamygdaloid cortex, posterior lateral auditory area, prosubiculum, rostroventral parietal area as defined in DLRPK03, superior parietal lobule (posterior dorsomedial parietal cortex above the intraparietal sulcus), superior temporal gyrus, temporal visual association area in the lower bank of the superior temporal sulcus, ventral anterior nucleus (thalamus), ventral lateral nucleus (thalamus), ventral striatal shell

Descendant targets:

Accessory basal amygdaloid nucleus, parvicellular part, Agranular area of temporal polar cortex, Agranular frontal area 2 (= caudal dorsolateral premotor area), Agranular frontal area 3 (= SMA-proper), Agranular frontal area 4 (= caudal ventrolateral premotor area), Agranular frontal area 5 (= rostral ventrolateral premotor area), Agranular frontal area 6 (= pre-SMA), Agranular frontal area 7 (= rostral dorsolateral premotor area), Agranular insula, Amygdala, Anterior inferotemporal area (dorsal), Anterior inferotemporal area (ventral), Anterior intraparietal area, Anterior medial nucleus, Area 1, Area 10, Area 11, Area 12, Area 20, Area 21, Area 23, Area 23a, Area 23b, Area 23c, Area 24a, Area 24b, Area 24c (rostral part of the cingulate sulcus), Area 24d (rostral part of the cingulate sulcus), Area 25, Area 26, Area 29, Area 29d, Area 3, Area 31, Area 32, Area 35, Area 36, Area 46 (dorsal rim

of the principal sulcus), Area 46 (fundus of the principal sulcus), Area 46 (ventral rim of the principal sulcus), Area 6, Area 6 (ventral part), Area 6 (ventral part), Area 7, Area 7a, Area 7b, Area 8, Area 8A, Area 8B, Area 9, Area X (thalamus), Basal amygdaloid nucleus, intermediate part, Basolateral nucleus of amygdala, CA1 subfield of Ammon`s horn, CA3 subfield of Ammons horn, Caudal and medial superior parietal lobule, Caudal area 8A, Caudal auditory parakoniocortex, Caudal inferior parietal lobule, Caudal limiting field of entorhinal cortex, Caudal parietal operculum, Caudal part of area 36, Caudomedial lobule, Central amygdaloid nucleus, lateral part, Central inferotemporal area, Central inferotemporal area (dorsal), Central inferotemporal area (ventral), Centrum medianum thalami, Claustrum, Corpus geniculatum mediale, Cortical area 29a-c, Cortical area 36p, Cortical area 44, Cortical area 45, Cortical area 45A, Cortical area 45B, Cortical area 46, Cortical area 9\/46d, Cortical area 9\/46v, Cortical area OAa, Cortical area PGa, Cortical area TEm, Dorsal area 10, Dorsal area 46, Dorsal dysgranular area of temporal polar cortex, Dorsal portion of area 8A, Dorsal prelunate gyrus, Dorsal visual area 3, Dysgranular Temporopolar Cortex, Dysgranular insular cortex, Entorhinal cortex, Entorhinal cortex, Extrastriate area OA, Fascia dentata hippocampi, Floor of superior temporal sulcus, Frontal eye field, Granular area of temporal polar cortex, Granular insular cortex, Gustatory cortex, Hippocampus, Hypothalamus, Inferior parietal lobule (lateral posterior cortex below the intraparietal sulcus), Inferotemporal area TE, Insular proisocortex, Intermediate agranula insular cortex, Intermediate field of entorhinal cortex, Intralaminar nuclei of the thalamus, Intraparietal sulcus associated area in the superior temporal sulcus, LGN external magnocellular layer, LGN internal magnocellular layer, LGN layer 2, Lateral Geniculate Nucleus, Lateral agranular insular cortex, Lateral area 11, Lateral area 12, Lateral area 9, Lateral auditory field, Lateral auditory field, Lateral auditory parakoniocortex, Lateral field (caudal part) of entorhinal cortex, Lateral field (rostral part) of entorhinal cortex, Lateral field of entorhinal cortex, Lateral intraparietal area, Lateral intraparietal area (external part), Lateral intraparietal area (internal part), Lateral nucleus (amygdala), dorsal division, Lateral nucleus (amygdala), dorsal intermediate division, Lateral nucleus (amygdala), ventral division, Laterodorsal nucleus (thalamus), Medial agranular insular cortex, Medial area 10, Medial area 11, Medial area 12, Medial area 9, Medial basal nucleus of the amygdala, Medial basal nucleus of the amygdala, Medial intraparietal area, Medial premotor area 6M, Medial superior temporal area, Medial superior temporal area (dorsal), Medial superior temporal area (posterior), Middle temporal area, Midpart of the inferior parietal lobule, Motor area 4a, Motor area 4b, Nucleus anterior ventralis thalami, Nucleus basalis thalami, Nucleus caudatus, Nucleus caudatus; genu, Nucleus caudatus; tail, Nucleus centralis densocellularis thalami, Nucleus centralis inferior thalami, Nucleus centralis intermedialis thalami, Nucleus centralis latocellularis thalami, Nucleus centralis superior lateralis thalami, Nucleus centralis superior thalami, Nucleus dorsalis tegmenti, Nucleus limitans thalami, Nucleus medialis dorsalis thalami, Nucleus medialis dorsalis thalami, pars caudodorsalis, Nucleus medialis dorsalis thalami, pars densocellularis, Nucleus medialis dorsalis thalami, pars fibrosa, Nucleus medialis dorsalis thalami, pars magnocellularis, Nucleus medialis dorsalis thalami, pars multiformis, Nucleus medialis dorsalis thalami, pars paramediana, Nucleus medialis dorsalis thalami, pars parvocellularis, Nucleus of the lateral olfactory tract, Nucleus paracentralis thalami, Nucleus parafascicularis thalami, Nucleus parataenialis thalami, Nucleus paraventricularis thalami, Nucleus paraventricularis thalami, pars anterior, Nucleus peripeduncularis thalami, Nucleus pulvinaris inferior thalami, Nucleus pulvinaris inferior thalami, central subdivision, Nucleus pulvinaris inferior thalami, lateral subdivision, Nucleus pulvinaris inferior thalami, pars medialis, Nucleus pulvinaris inferior thalami, pars posterior, Nucleus pulvinaris inferior thalami, shell of the lateral subdivision, Nucleus pulvinaris lateralis thalami pars ventrolateralis, Nucleus pulvinaris lateralis thalami pars ventromedialis, Nucleus pulvinaris lateralis thalami, dorsal division, Nucleus pulvinaris medialis thalami, Nucleus pulvinaris medialis thalami, lateral division, Nucleus pulvinaris medialis thalami, medial division, Nucleus pulvinaris oralis thalami, Nucleus pulvinaris thalami, Nucleus pulvinaris thalami, pars oralis, Nucleus reticularis thalami, Nucleus reuniens thalami, Nucleus subthalamicus, Nucleus suprageniculatus thalami, Nucleus ventralis anterior thalami, pars densocellularis, Nucleus ventralis anterior thalami, pars magnocellularis, Nucleus ventralis anterior thalami, pars parvocellularis, Nucleus ventralis lateralis thalami, pars caudalis, Nucleus ventralis lateralis thalami, pars medialis, Nucleus ventralis lateralis thalami, pars oralis, Nucleus ventralis lateralis thalami, pars postrema, Nucleus ventralis posterior inferior thalami, Nucleus ventralis posterior lateralis thalami, pars caudalis, Nucleus ventralis posterior lateralis thalami, pars oralis, Nucleus ventralis posterior medialis thalami, Occipitoparietal area, Olfactory Complex, Olfactory field of entorhinal cortex, Orbital area 10, Orbital area 12, Orbital part of area 14, Orbital prefrontal cortex, Orbitofrontal area 13, Orbitofrontal area 13, lateral part, Orbitofrontal area 13, medial part, Orbitofrontal area 13a, Orbitofrontal area 14, Orbitofrontal cortex, agranular periallocortical, Orbitofrontal opercular area, Parahippocampal cortex, Parasubiculum, Parietal area PE (cingulate part), Parietal area PG, medial part, Periamygdaloid cortex 2, Peripheral part of area MT, Piriform cortex, Postcentral area 3a, Postcentral area 3b, Posterior

Nucleii of Thalamus, Posterior inferotemporal area, Posterior inferotemporal area (dorsal), Posterior inferotemporal area (ventral), Posterior intraparietal area, Posterior parietal area, Posteromedial agranular insular cortex, Precentral opercular area, Prefrontal area 47\/12, Premotor area 6 (dorsal part), Premotor area 6Va, Premotor area 6Vb, Premotor area 6b-beta, Presubiculum, Primary auditory cortex, Primary motor area, Primary motor cortex M1, forelimb area, Primary motor cortex M1, hindlimb area, Primary sensory area PC, Primary sensory cortex, Primary somatosensory cortex, Principal Sulcus, Pro motor area, Prostriate cortex, Putamen, Putamen; caudal, Putamen; rostral, Retroinsular area, Retrosplenial area 30, Rostral area 12, Rostral area 14, Rostral field of entorhinal cortex, Rostral inferior parietal lobule, Rostral parietal operculum, Rostral part of area 36, Rostral superior parietal lobule, SMA - caudal part, SMA - rostral part, Secondary auditory cortex, Secondary somatosensory cortex, Subiculum, body portion, Subiculum, uncal portion, Superior temporal area 1, Superior temporal area 2, Superior temporal area 3, Superior temporal sulcus, Superior temporal sulcus, dorsal, Supplementary motor cortex M2, forelimb area, Supplementary motor cortex M2, hindlimb area, Supratemporal cortex, granular, Temporal area TA, Temporal area TAa, Temporal area TF, Temporal area TF (lateral part), Temporal area TF (medial part), Temporal area TH, Temporal parietooccipital associated area in superior temporal sulcus, Temporal proisocortex, Temporoparietal asscociated area (caudal part), Temporoparietal associated area (intermediate part), Temporoparietal associated area (rostral part), Temporoparietal cortex, Temporopolar area TG, Transitional sensory area, V4 transitional area, Ventral area 10, Ventral area 46, Ventral dysgranular area of temporal polar cortex, Ventral intraparietal area, Ventral occipitotemporal area, Ventral posterior area, Ventral posterior lateral nucleus (thalamus), Ventral posterior parietal area, Ventral visual area 3, Ventroposterior superior nucleus thalami, Visual area 1, Visual area 2, Visual area 3, Visual area 3A, Visual area 4, Visual area 4 (dorsal part), Visual area 4 (ventral part), Visual area V6A, accessory basal nucleus (amygdala), magnocellular subdivision, amygdalohippocampal area, anterior amygdaloid area, anterior lateral auditory belt, area 24, area dentata (dentate gyrus), auditory prokoniocortex, belt line of the sensory system according to CP99, belt line of the sensorymotor system according to CP99, body representation of MI as defined in KSI03, caudal lateral auditory (belt), central nucleus of the amygdala, cortical nucleus (amygdala), cortical nucleus, anterior division, cortical nucleus, posterior division, dorsal area 9, dorsointermediate visual field, dorsolateral visual cortex, caudal part, dorsolateral visual cortex, rostral part, face representation in SII as defined in DLRPK03, lateral nucleus (amygdala), ventrolateral subdivision, medial entorhinal cortex, orofacial representation in MI, periamygdaloid cortex, posterior lateral auditory area, prosubiculum, rostroventral parietal area as defined in DLRPK03, substantia nigra, superior parietal lobule (posterior dorsomedial parietal cortex above the intraparietal sulcus), superior temporal gyrus, temporal visual association area in the lower bank of the superior temporal sulcus, ventral anterior nucleus (thalamus), ventral lateral nucleus (thalamus), ventral striatal shell

Sub-regions:
Cingulate gyrus, Cortical area FL, Insula, ParietalLobe according to GM-Definition, Striate cortex, Temporal Lobe according to GM-Definition

---
Region: Cortical area FL (FL#2)

Super-regions:
Cortical area FL < GM-CerebralCortex < Brain

Descendant sources:
Accessor basal nucleus (amygdala), ventromedial division, Accessory basal amygdaloid nucleus, parvicellular part, Agranular area of temporal polar cortex, Agranular frontal area 2 (= caudal dorsolateral premotor area), Agranular frontal area 3 (= SMA-proper), Agranular frontal area 4 (= caudal ventrolateral premotor area), Agranular frontal area 5 (= rostral ventrolateral premotor area), Agranular frontal area 6 (= pre-SMA), Agranular frontal area 7 (= rostral dorsolateral premotor area), Agranular insula, Amygdala, Anterior inferotemporal area (dorsal), Anterior inferotemporal area (ventral), Anterior intraparietal area, Anterior medial nucleus, Anterior nuclei of the thalamus, Area 1, Area 10, Area 11, Area 12, Area 23, Area 23a, Area 23b, Area 23c, Area 24a, Area 24b, Area 24c (rostral part of the cingulate sulcus), Area 24d (rostral part of the cingulate sulcus), Area 25, Area 29, Area 29d, Area 3, Area 31, Area 32, Area 35, Area 36, Area 46 (dorsal rim of the principal sulcus), Area 46 (fundus of the principal sulcus), Area 46 (ventral rim of the principal sulcus), Area 6, Area 6 (ventral part), Area 6 (ventral part), Area 7, Area 7a, Area 7b, Area 8, Area 8A, Area 8B, Area 9, Area X (thalamus), Basal amygdaloid nucleus, intermediate part, Basolateral nucleus of amygdala, CA1 subfield of Ammon`s horn, CA3 subfield of Ammons horn, Caudal and medial superior parietal lobule, Caudal auditory parakoniocortex, Caudal inferior parietal lobule, Caudal limiting field of entorhinal

cortex, Caudal parietal operculum, Caudomedial lobule, Central amygdaloid nucleus, lateral part, Central inferotemporal area, Central inferotemporal area (dorsal), Central inferotemporal area (ventral), Centrum medianum thalami, Cingulate motor areas, Claustrum, Corpus geniculatum mediale, Cortical amygdaloid nucleus, Cortical area 29a-c, Cortical area 44, Cortical area 45, Cortical area 45A, Cortical area 45B, Cortical area 46, Cortical area 9\/46d, Cortical area 9\/46v, Cortical area PGa, Cortical area TEm, Dorsal area 10, Dorsal area 46, Dorsal dysgranular area of temporal polar cortex, Dorsal portion of area 8A, Dorsal prelunate gyrus, Dorsal visual area 3, Dysgranular Temporopolar Cortex, Dysgranular insular cortex, Entorhinal cortex, Entorhinal cortex, Extrastriate area OA, Fascia dentata hippocampi, Floor of superior temporal sulcus, Frontal eye field, Granular area of temporal polar cortex, Granular insular cortex, Gustatory cortex, Hippocampus, Hypothalamus, Inferior parietal lobule (lateral posterior cortex below the intraparietal sulcus), Inferotemporal area TE, Insula, Insular proisocortex, Intermediate agranula insular cortex, Intermediate field of entorhinal cortex, Intralaminar nuclei of the thalamus, Intraparietal sulcus associated area in the superior temporal sulcus, LGN external magnocellular layer, LGN layer 2, Lateral Geniculate Nucleus, Lateral agranular insular cortex, Lateral area 11, Lateral area 12, Lateral area 9, Lateral auditory field, Lateral auditory field, Lateral auditory parakoniocortex, Lateral field (caudal part) of entorhinal cortex, Lateral field (rostral part) of entorhinal cortex, Lateral field of entorhinal cortex, Lateral intraparietal area, Lateral intraparietal area (external part), Lateral intraparietal area (internal part), Laterodorsal nucleus (thalamus), Medial agranular insular cortex, Medial area 10, Medial area 11, Medial area 12, Medial area 9, Medial basal nucleus of the amygdala, Medial intraparietal area, Medial premotor area 6M, Medial superior temporal area, Medial superior temporal area (dorsal), Medial superior temporal area (posterior), Middle temporal area, Midline nuclei of the thalamus, Midpart of the inferior parietal lobule, Motor area 4c, Nucleus anterior ventralis thalami, Nucleus basalis thalami, Nucleus centralis densocellularis thalami, Nucleus centralis inferior thalami, Nucleus centralis intermedialis thalami, Nucleus centralis latocellularis thalami, Nucleus centralis superior lateralis thalami, Nucleus centralis superior thalami, Nucleus limitans thalami, Nucleus medialis dorsalis thalami, Nucleus medialis dorsalis thalami, pars caudodorsalis, Nucleus medialis dorsalis thalami, pars densocellularis, Nucleus medialis dorsalis thalami, pars fibrosa, Nucleus medialis dorsalis thalami, pars lateralis, Nucleus medialis dorsalis thalami, pars magnocellularis, Nucleus medialis dorsalis thalami, pars multiformis, Nucleus medialis dorsalis thalami, pars paramediana, Nucleus medialis dorsalis thalami, pars parvocellularis, Nucleus paracentralis thalami, Nucleus parafascicularis thalami, Nucleus parataenialis thalami, Nucleus paraventricularis thalami, Nucleus paraventricularis thalami, pars anterior, Nucleus pulvinaris inferior thalami, Nucleus pulvinaris inferior thalami, Nucleus pulvinaris medialis thalami, Nucleus pulvinaris oralis thalami, Nucleus pulvinaris thalami, Nucleus pulvinaris thalami, pars oralis, Nucleus reticularis thalami, Nucleus reuniens thalami, Nucleus subthalamicus, Nucleus suprageniculatus thalami, Nucleus ventralis anterior thalami, pars densocellularis, Nucleus ventralis anterior thalami, pars magnocellularis, Nucleus ventralis anterior thalami, pars parvocellularis, Nucleus ventralis lateralis thalami, pars caudalis, Nucleus ventralis lateralis thalami, pars medialis, Nucleus ventralis lateralis thalami, pars oralis, Nucleus ventralis lateralis thalami, pars postrema, Nucleus ventralis posterior inferior thalami, Nucleus ventralis posterior lateralis thalami, pars caudalis, Nucleus ventralis posterior lateralis thalami, pars oralis, Nucleus ventralis posterior medialis thalami, Occipitoparietal area, Olfactory Complex, Olfactory field of entorhinal cortex, Orbital area 10, Orbital area 12, Orbital part of area 14, Orbital prefrontal cortex, Orbitofrontal area 13, Orbitofrontal area 13, lateral part, Orbitofrontal area 13, medial part, Orbitofrontal area 13a, Orbitofrontal area 14, Orbitofrontal cortex, agranular periallocortical, Parahippocampal cortex, Parasubiculum, Parietal area PE (cingulate part), Parietal area PG, medial part, Periamygdaloid cortex 2, Peripheral part of area MT, Piriform cortex, Postcentral area 3a, Postcentral area 3b, Posterior Nucleii of Thalamus, Posterior inferotemporal area, Posterior inferotemporal area (dorsal), Posterior parietal area, Posteromedial agranular insular cortex, Precentral opercular area, Prefrontal area 47\/12, Premotor area 6 (dorsal part), Premotor area 6Va, Premotor area 6Vb, Presubiculum, Primary auditory cortex, Primary motor area, Primary motor cortex M1, forelimb area, Primary motor cortex M1, hindlimb area, Primary sensory area PC, Primary sensory cortex, Primary somatosensory cortex, Principal Sulcus, Pro motor area, Retroinsular area, Retrosplenial area 30, Rostral area 12, Rostral area 14, Rostral field of entorhinal cortex, Rostral inferior parietal lobule, Rostral parietal operculum, Rostral superior parietal lobule, SMA - caudal part, SMA - rostral part, Secondary auditory cortex, Secondary somatosensory cortex, Subiculum, body portion, Subiculum, uncal portion, Superior temporal area 1, Superior temporal area 2, Superior temporal area 3, Superior

temporal sulcus, Superior temporal sulcus, dorsal, Supplementary motor cortex M2, forelimb area, Supplementary motor cortex M2, hindlimb area, Supratemporal cortex, granular, Temporal area TA, Temporal area TAa, Temporal area TF, Temporal area TH, Temporal parietooccipital associated area in superior temporal sulcus, Temporal proisocortex, Temporoparietal asscociated area (caudal part), Temporoparietal associated area (rostral part), Temporoparietal cortex, Temporopolar area TG, Thalamus, V4 transitional area, Ventolateral Nucleii of Thalamus, Ventral area 10, Ventral area 46, Ventral dysgranular area of temporal polar cortex, Ventral intraparietal area, Ventral posterior lateral nucleus (thalamus), Ventral visual area 3, Visual area 2, Visual area 3, Visual area 3A, Visual area 4, Visual area V6A, accessory basal nucleus (amygdala), magnocellular subdivision, amygdalohippocampal area, anterior amygdaloid area, anterior lateral auditory belt, area 24, area dentata (dentate gyrus), auditory prokoniocortex, belt line of the sensory system according to CP99, belt line of the sensorymotor system according to CP99, caudal lateral auditory (belt), cortical nucleus, anterior division, dorsal area 9, orofacial representation in MI, periamygdaloid cortex, posterior lateral auditory area, prosubiculum, rostroventral parietal area as defined in DLRPK03, superior parietal lobule (posterior dorsomedial parietal cortex above the intraparietal sulcus), superior temporal gyrus, temporal visual association area in the lower bank of the superior temporal sulcus, ventral anterior nucleus (thalamus), ventral lateral nucleus (thalamus), ventral striatal shell

Descendant targets:

Accessory basal amygdaloid nucleus, parvicellular part, Agranular area of temporal polar cortex, Agranular frontal area 2 (= caudal dorsolateral premotor area), Agranular frontal area 3 (= SMA-proper), Agranular frontal area 4 (= caudal ventrolateral premotor area), Agranular frontal area 5 (= rostral ventrolateral premotor area), Agranular frontal area 6 (= pre-SMA), Agranular frontal area 7 (= rostral dorsolateral premotor area), Agranular insula, Anterior inferotemporal area (dorsal), Anterior intraparietal area, Anterior medial nucleus, Area 1, Area 10, Area 11, Area 12, Area 23, Area 23a, Area 23b, Area 23c, Area 24a, Area 24b, Area 24c (rostral part of the cingulate sulcus), Area 24d (rostral part of the cingulate sulcus), Area 25, Area 29, Area 29d, Area 3, Area 31, Area 32, Area 35, Area 36, Area 46 (dorsal rim of the principal sulcus), Area 46 (fundus of the principal sulcus), Area 46 (ventral rim of the principal sulcus), Area 6, Area 6 (ventral part), Area 7, Area 7a, Area 7b, Area 8, Area 8A, Area 8B, Area 9, Area X (thalamus), Basal amygdaloid nucleus, intermediate part, Caudal and medial superior parietal lobule, Caudal auditory parakoniocortex, Caudal inferior parietal lobule, Caudal limiting field of entorhinal cortex, Caudal parietal operculum, Caudal part of area 36, Caudomedial lobule, Central amygdaloid nucleus, lateral part, Central inferotemporal area, Central inferotemporal area (ventral), Centrum medianum thalami, Claustrum, Cortical area 29a-c, Cortical area 44, Cortical area 45, Cortical area 45A, Cortical area 46, Cortical area 9\/46d, Cortical area 9\/46v, Cortical area OAa, Cortical area PGa, Cortical area TEm, Dorsal area 10, Dorsal area 46, Dorsal dysgranular area of temporal polar cortex, Dorsal portion of area 8A, Dorsal prelunate gyrus, Dysgranular insular cortex, Entorhinal cortex, Entorhinal cortex, Extrastriate area OA, Fascia dentata hippocampi, Floor of superior temporal sulcus, Frontal eye field, Granular area of temporal polar cortex, Granular insular cortex, Gustatory cortex, Hypothalamus, Inferior parietal lobule (lateral posterior cortex below the intraparietal sulcus), Inferotemporal area TE, Insular proisocortex, Intermediate agranula insular cortex, Intermediate field of entorhinal cortex, Intraparietal sulcus associated area in the superior temporal sulcus, LGN external magnocellular layer, LGN layer 2, Lateral agranular insular cortex, Lateral area 11, Lateral area 12, Lateral area 9, Lateral auditory field, Lateral auditory field, Lateral auditory parakoniocortex, Lateral field (caudal part) of entorhinal cortex, Lateral field (rostral part) of entorhinal cortex, Lateral intraparietal area, Lateral intraparietal area (external part), Lateral intraparietal area (internal part), Lateral nucleus (amygdala), dorsal division, Lateral nucleus (amygdala), dorsal intermediate division, Lateral nucleus (amygdala), ventral division, Medial agranular insular cortex, Medial area 10, Medial area 11, Medial area 12, Medial area 9, Medial basal nucleus of the amygdala, Medial intraparietal area, Medial premotor area 6M, Medial superior temporal area, Medial superior temporal area (dorsal), Medial superior temporal area (posterior), Midpart of the inferior parietal lobule, Nucleus basalis thalami, Nucleus caudatus, Nucleus caudatus; genu, Nucleus caudatus; tail, Nucleus centralis inferior thalami, Nucleus centralis intermedialis thalami, Nucleus centralis superior lateralis thalami, Nucleus centralis superior thalami, Nucleus limitans thalami, Nucleus medialis dorsalis thalami, Nucleus medialis dorsalis thalami, pars caudodorsalis, Nucleus medialis dorsalis thalami, pars densocellularis, Nucleus medialis dorsalis thalami, pars fibrosa, Nucleus medialis dorsalis thalami, pars magnocellularis, Nucleus medialis dorsalis thalami, pars multiformis,

Nucleus medialis dorsalis thalami, pars paramediana, Nucleus medialis dorsalis thalami, pars parvocellularis, Nucleus paracentralis thalami, Nucleus parafascicularis thalami, Nucleus parataenialis thalami, Nucleus paraventricularis thalami, Nucleus paraventricularis thalami, pars anterior, Nucleus pulvinaris lateralis thalami, dorsal division, Nucleus pulvinaris medialis thalami, Nucleus pulvinaris medialis thalami, lateral division, Nucleus pulvinaris medialis thalami, medial division, Nucleus pulvinaris oralis thalami, Nucleus pulvinaris thalami, Nucleus pulvinaris thalami, pars oralis, Nucleus reticularis thalami, Nucleus reuniens thalami, Nucleus subthalamicus, Nucleus supragenicularus thalami, Nucleus ventralis anterior thalami, pars densocellularis, Nucleus ventralis anterior thalami, pars magnocellularis, Nucleus ventralis anterior thalami, pars parvocellularis, Nucleus ventralis lateralis thalami, pars caudalis, Nucleus ventralis lateralis thalami, pars medialis, Nucleus ventralis lateralis thalami, pars oralis, Nucleus ventralis lateralis thalami, pars postrema, Nucleus ventralis posterior inferior thalami, Nucleus ventralis posterior lateralis thalami, pars caudalis, Nucleus ventralis posterior lateralis thalami, pars oralis, Nucleus ventralis posterior medialis thalami, Occipitoparietal area, Olfactory field of entorhinal cortex, Orbital area 10, Orbital area 12, Orbital part of area 14, Orbitofrontal area 13, Orbitofrontal area 13, lateral part, Orbitofrontal area 13, medial part, Orbitofrontal area 13a, Orbitofrontal area 14, Parahippocampal cortex, Parietal area PE (cingulate part), Parietal area PG, medial part, Postcentral area 3a, Postcentral area 3b, Posterior inferotemporal area, Posteromedial agranular insular cortex, Precentral opercular area, Prefrontal area 47\/12, Premotor area 6 (dorsal part), Premotor area 6Va, Premotor area 6Vb, Presubiculum, Primary auditory cortex, Primary motor area, Primary motor cortex M1, forelimb area, Primary motor cortex M1, hindlimb area, Primary sensory area PC, Primary sensory cortex, Primary somatosensory cortex, Principal Sulcus, Pro motor area, Putamen, Putamen; caudal, Putamen; rostral, Retrosplenial area 30, Rostral area 12, Rostral area 14, Rostral field of entorhinal cortex, Rostral inferior parietal lobule, Rostral parietal operculum, Rostral part of area 36, Rostral superior parietal lobule, SMA - caudal part, SMA - rostral part, Secondary somatosensory cortex, Subiculum, body portion, Subiculum, uncal portion, Superior temporal area 1, Superior temporal area 2, Superior temporal area 3, Superior temporal sulcus, Superior temporal sulcus, dorsal, Supplementary motor cortex M2, forelimb area, Supplementary motor cortex M2, hindlimb area, Temporal area TAa, Temporal area TF, Temporal area TF (lateral part), Temporal area TF (medial part), Temporal area TH, Temporal parietooccipital associated area in superior temporal sulcus, Temporal proisocortex, Temporoparietal asscociated area (caudal part), Temporoparietal associated area (intermediate part), Temporoparietal associated area (rostral part), Temporoparietal cortex, Temporopolar area TG, Transitional sensory area, Ventral area 10, Ventral area 46, Ventral dysgranular area of temporal polar cortex, Ventral intraparietal area, Ventral posterior area, Ventral posterior lateral nucleus (thalamus), Visual area 4, Visual area V6A, accessory basal nucleus (amygdala), magnocellular subdivision, anterior lateral auditory belt, area 24, area dentata (dentate gyrus), belt line of the sensory system according to CP99, belt line of the sensorymotor system according to CP99, body representation of MI as defined in KSI03, caudal lateral auditory (belt), central nucleus of the amygdala, dorsal area 9, lateral nucleus (amygdala), ventrolateral subdivision, orofacial representation in MI, periamygdaloid cortex, posterior lateral auditory area, prosubiculum, rostroventral parietal area as defined in DLRPK03, substantia nigra, superior parietal lobule (posterior dorsomedial parietal cortex above the intraparietal sulcus), temporal visual association area in the lower bank of the superior temporal sulcus, ventral anterior nucleus (thalamus), ventral lateral nucleus (thalamus), ventral striatal shell

Sub-regions:
Area 6, Prefrontal Cortex, Primary motor area, belt line of the sensorymotor system according to CP99

Region: belt line of the sensorymotor system according to CP99 (belt_sm)

Super-regions:
belt line of the sensorymotor system according to CP99 <
Cortical area FL < GM-CerebralCortex < Brain

Sources:
Agranular insula, Area 1, Area 12, Area 3, Area 6, Area 7b, Dysgranular insular cortex, Gustatory cortex, LGN layer 2, Orbitofrontal area 13, Primary motor area, Pro motor area, Secondary somatosensory cortex

Targets:

Area 1, Area 3, Area 6, Gustatory cortex, LGN layer 2, Pro motor area, Rostral inferior parietal lobule, Secondary somatosensory cortex, Ventral intraparietal area

---

Region: Prefrontal Cortex (Pfc)

Super-regions:
Prefrontal Cortex < Cortical area FL < GM-CerebralCortex < Brain

Descendant sources:
Accessor basal nucleus (amygdala), ventromedial division, Accessory basal amygdaloid nucleus, parvicellular part, Agranular area of temporal polar cortex, Agranular frontal area 4 (= caudal ventrolateral premotor area), Agranular frontal area 5 (= rostral ventrolateral premotor area), Agranular frontal area 6 (= pre-SMA), Agranular frontal area 7 (= rostral dorsolateral premotor area), Agranular insula, Amygdala, Anterior inferotemporal area (dorsal), Anterior inferotemporal area (ventral), Anterior intraparietal area, Anterior medial nucleus, Anterior nuclei of the thalamus, Area 1, Area 10, Area 11, Area 12, Area 23, Area 23a, Area 23b, Area 23c, Area 24a, Area 24b, Area 24c (rostral part of the cingulate sulcus), Area 24d (rostral part of the cingulate sulcus), Area 25, Area 29, Area 29d, Area 3, Area 31, Area 32, Area 35, Area 36, Area 46 (dorsal rim of the principal sulcus), Area 46 (fundus of the principal sulcus), Area 46 (ventral rim of the principal sulcus), Area 6, Area 6 (ventral part), Area 6 (ventral part), Area 7, Area 7a, Area 7b, Area 8, Area 8A, Area 8B, Area 9, Area X (thalamus), Basal amygdaloid nucleus, intermediate part, Basolateral nucleus of amygdala, CA1 subfield of Ammon`s horn, CA3 subfield of Ammons horn, Caudal auditory parakoniocortex, Caudal inferior parietal lobule, Caudal limiting field of entorhinal cortex, Caudal parietal operculum, Caudomedial lobule, Central amygdaloid nucleus, lateral part, Central inferotemporal area, Central inferotemporal area (dorsal), Central inferotemporal area (ventral), Centrum medianum thalami, Claustrum, Corpus geniculatum mediale, Cortical amygdaloid nucleus, Cortical area 29a-c, Cortical area 44, Cortical area 45, Cortical area 45A, Cortical area 45B, Cortical area 46, Cortical area 9\/46d, Cortical area 9\/46v, Cortical area PGa, Cortical area TEm, Dorsal area 10, Dorsal area 46, Dorsal dysgranular area of temporal polar cortex, Dorsal portion of area 8A, Dorsal prelunate gyrus, Dorsal visual area 3, Dysgranular Temporopolar Cortex, Dysgranular insular cortex, Entorhinal cortex, Entorhinal cortex, Extrastriate area OA, Floor of superior temporal sulcus, Frontal eye field, Granular area of temporal polar cortex, Granular insular cortex, Gustatory cortex, Hippocampus, Hypothalamus, Inferior parietal lobule (lateral posterior cortex below the intraparietal sulcus), Inferotemporal area TE, Insula, Insular proisocortex, Intermediate agranula insular cortex, Intermediate field of entorhinal cortex, Intralaminar nuclei of the thalamus, Intraparietal sulcus associated area in the superior temporal sulcus, LGN external magnocellular layer, LGN layer 2, Lateral agranular insular cortex, Lateral area 11, Lateral area 12, Lateral area 9, Lateral auditory field, Lateral auditory field, Lateral auditory parakoniocortex, Lateral field (caudal part) of entorhinal cortex, Lateral field (rostral part) of entorhinal cortex, Lateral field of entorhinal cortex, Lateral intraparietal area, Lateral intraparietal area (external part), Lateral intraparietal area (internal part), Medial agranular insular cortex, Medial area 10, Medial area 11, Medial area 12, Medial area 9, Medial basal nucleus of the amygdala, Medial intraparietal area, Medial premotor area 6M, Medial superior temporal area, Medial superior temporal area (dorsal), Medial superior temporal area (posterior), Middle temporal area, Midline nuclei of the thalamus, Midpart of the inferior parietal lobule, Motor area 4c, Nucleus anterior ventralis thalami, Nucleus basalis thalami, Nucleus centralis densocellularis thalami, Nucleus centralis inferior thalami, Nucleus centralis intermedialis thalami, Nucleus centralis latocellularis thalami, Nucleus centralis superior lateralis thalami, Nucleus centralis superior thalami, Nucleus limitans thalami, Nucleus medialis dorsalis thalami, Nucleus medialis dorsalis thalami, pars caudodorsalis, Nucleus medialis dorsalis thalami, pars densocellularis, Nucleus medialis dorsalis thalami, pars fibrosa, Nucleus medialis dorsalis thalami, pars lateralis, Nucleus medialis dorsalis thalami, pars magnocellularis, Nucleus medialis dorsalis thalami, pars multiformis, Nucleus medialis dorsalis thalami, pars paramediana, Nucleus medialis dorsalis thalami, pars parvocellularis, Nucleus paracentralis thalami, Nucleus parafascicularis thalami, Nucleus parataenialis thalami, Nucleus paraventricularis thalami, Nucleus paraventricularis

thalami, pars anterior, Nucleus pulvinaris inferior thalami, Nucleus pulvinaris inferior thalami, Nucleus pulvinaris medialis thalami, Nucleus pulvinaris thalami, Nucleus pulvinaris thalami, pars oralis, Nucleus reuniens thalami, Nucleus subthalamicus, Nucleus suprageniculatus thalami, Nucleus ventralis anterior thalami, pars magnocellularis, Nucleus ventralis anterior thalami, pars parvocellularis, Nucleus ventralis lateralis thalami, pars medialis, Nucleus ventralis lateralis thalami, pars oralis, Nucleus ventralis lateralis thalami, pars postrema, Nucleus ventralis posterior medialis thalami, Occipitoparietal area, Olfactory Complex, Olfactory field of entorhinal cortex, Orbital area 10, Orbital area 12, Orbital part of area 14, Orbital prefrontal cortex, Orbitofrontal area 13, Orbitofrontal area 13, lateral part, Orbitofrontal area 13, medial part, Orbitofrontal area 13a, Orbitofrontal area 14, Orbitofrontal cortex, agranular periallocortical, Parahippocampal cortex, Parasubiculum, Parietal area PG, medial part, Periamygdaloid cortex 2, Peripheral part of area MT, Piriform cortex, Postcentral area 3a, Postcentral area 3b, Posterior Nucleii of Thalamus, Posterior inferotemporal area, Posterior inferotemporal area (dorsal), Posteromedial agranular insular cortex, Precentral opercular area, Prefrontal area 47\/12, Premotor area 6 (dorsal part), Premotor area 6Va, Premotor area 6Vb, Presubiculum, Primary auditory cortex, Primary sensory cortex, Primary somatosensory cortex, Principal Sulcus, Pro motor area, Retroinsular area, Retrosplenial area 30, Rostral area 12, Rostral area 14, Rostral field of entorhinal cortex, Rostral inferior parietal lobule, Rostral superior parietal lobule, SMA - rostral part, Secondary auditory cortex, Secondary somatosensory cortex, Subiculum, body portion, Subiculum, uncal portion, Superior temporal area 1, Superior temporal area 2, Superior temporal area 3, Superior temporal sulcus, Superior temporal sulcus, dorsal, Supratemporal cortex, granular, Temporal area TA, Temporal area TAa, Temporal area TF, Temporal area TH, Temporal parietooccipital associated area in superior temporal sulcus, Temporal proisocortex, Temporoparietal asscociated area (caudal part), Temporoparietal associated area (rostral part), Temporoparietal cortex, Temporopolar area TG, V4 transitional area, Ventral area 10, Ventral area 46, Ventral dysgranular area of temporal polar cortex, Ventral intraparietal area, Ventral posterior lateral nucleus (thalamus), Ventral visual area 3, Visual area 2, Visual area 3, Visual area 3A, Visual area 4, Visual area V6A, accessory basal nucleus (amygdala), magnocellular subdivision, amygdalohippocampal area, anterior amygdaloid area, anterior lateral auditory belt, area 24, area dentata (dentate gyrus), auditory prokoniocortex, belt line of the sensory system according to CP99, belt line of the sensorymotor system according to CP99, caudal lateral auditory (belt), cortical nucleus, anterior division, dorsal area 9, periamygdaloid cortex, posterior lateral auditory area, prosubiculum, rostroventral parietal area as defined in DLRPK03, superior parietal lobule (posterior dorsomedial parietal cortex above the intraparietal sulcus), temporal visual association area in the lower bank of the superior temporal sulcus, ventral anterior nucleus (thalamus), ventral lateral nucleus (thalamus), ventral striatal shell

Descendant targets:

Accessory basal amygdaloid nucleus, parvicellular part, Agranular area of temporal polar cortex, Agranular frontal area 2 (= caudal dorsolateral premotor area), Agranular frontal area 4 (= caudal ventrolateral premotor area), Agranular frontal area 5 (= rostral ventrolateral premotor area), Agranular frontal area 6 (= pre-SMA), Agranular frontal area 7 (= rostral dorsolateral premotor area), Anterior inferotemporal area (dorsal), Anterior medial nucleus, Area 10, Area 11, Area 12, Area 23, Area 23a, Area 23b, Area 23c, Area 24a, Area 24b, Area 24c (rostral part of the cingulate sulcus), Area 24d (rostral part of the cingulate sulcus), Area 25, Area 29, Area 29d, Area 3, Area 31, Area 32, Area 35, Area 36, Area 46 (dorsal rim of the principal sulcus), Area 46 (fundus of the principal sulcus), Area 46 (ventral rim of the principal sulcus), Area 6 (ventral part), Area 7, Area 7a, Area 7b, Area 8A, Area 8B, Area 9, Area X (thalamus), Basal amygdaloid nucleus, intermediate part, Caudal auditory parakoniocortex, Caudal inferior parietal lobule, Caudal limiting field of entorhinal cortex, Caudal parietal operculum, Caudal part of area 36, Caudomedial lobule, Central amygdaloid nucleus, lateral part, Central inferotemporal area, Central inferotemporal area (ventral), Centrum medianum thalami, Claustrum, Cortical area 29a-c, Cortical area 45, Cortical area 46, Cortical area 9\/46d, Cortical area 9\/46v, Cortical area OAa, Cortical area PGa, Cortical area TEm, Dorsal area 10, Dorsal area 46, Dorsal dysgranular area of temporal polar cortex, Dorsal portion of area 8A, Dorsal prelunate gyrus, Dysgranular insular cortex, Entorhinal cortex, Entorhinal

cortex, Extrastriate area OA, Floor of superior temporal sulcus, Frontal eye field, Granular area of temporal polar cortex, Gustatory cortex, Hypothalamus, Inferior parietal lobule (lateral posterior cortex below the intraparietal sulcus), Inferotemporal area TE, Intermediate agranula insular cortex, Intermediate field of entorhinal cortex, Intraparietal sulcus associated area in the superior temporal sulcus, LGN external magnocellular layer, LGN layer 2, Lateral agranular insular cortex, Lateral area 11, Lateral area 12, Lateral area 9, Lateral auditory field, Lateral auditory field, Lateral auditory parakoniocortex, Lateral field (caudal part) of entorhinal cortex, Lateral field (rostral part) of entorhinal cortex, Lateral intraparietal area, Lateral intraparietal area (external part), Lateral intraparietal area (internal part), Lateral nucleus (amygdala), dorsal division, Lateral nucleus (amygdala), dorsal intermediate division, Lateral nucleus (amygdala), ventral division, Medial agranular insular cortex, Medial area 10, Medial area 11, Medial area 12, Medial area 9, Medial basal nucleus of the amygdala, Medial premotor area 6M, Medial superior temporal area, Medial superior temporal area (dorsal), Medial superior temporal area (posterior), Nucleus basalis thalami, Nucleus caudatus, Nucleus caudatus; genu, Nucleus caudatus; tail, Nucleus centralis inferior thalami, Nucleus centralis intermedialis thalami, Nucleus centralis superior lateralis thalami, Nucleus centralis superior thalami, Nucleus limitans thalami, Nucleus medialis dorsalis thalami, Nucleus medialis dorsalis thalami, pars caudodorsalis, Nucleus medialis dorsalis thalami, pars densocellularis, Nucleus medialis dorsalis thalami, pars fibrosa, Nucleus medialis dorsalis thalami, pars magnocellularis, Nucleus medialis dorsalis thalami, pars multiformis, Nucleus medialis dorsalis thalami, pars paramediana, Nucleus medialis dorsalis thalami, pars parvocellularis, Nucleus paracentralis thalami, Nucleus parafascicularis thalami, Nucleus parataenialis thalami, Nucleus paraventricularis thalami, Nucleus paraventricularis thalami, pars anterior, Nucleus pulvinaris lateralis thalami, dorsal division, Nucleus pulvinaris medialis thalami, Nucleus pulvinaris medialis thalami, lateral division, Nucleus pulvinaris medialis thalami, medial division, Nucleus pulvinaris thalami, Nucleus pulvinaris thalami, pars oralis, Nucleus reticularis thalami, Nucleus reuniens thalami, Nucleus supragenicularus thalami, Nucleus ventralis anterior thalami, pars magnocellularis, Nucleus ventralis lateralis thalami, pars caudalis, Nucleus ventralis lateralis thalami, pars medialis, Nucleus ventralis lateralis thalami, pars oralis, Nucleus ventralis posterior lateralis thalami, pars oralis, Occipitoparietal area, Olfactory field of entorhinal cortex, Orbital area 10, Orbital area 12, Orbital part of area 14, Orbitofrontal area 13, Orbitofrontal area 13, lateral part, Orbitofrontal area 13, medial part, Orbitofrontal area 13a, Orbitofrontal area 14, Parahippocampal cortex, Parietal area PE (cingulate part), Parietal area PG, medial part, Posterior inferotemporal area, Posteromedial agranular insular cortex, Precentral opercular area, Prefrontal area 47\/12, Premotor area 6 (dorsal part), Premotor area 6Va, Premotor area 6Vb, Presubiculum, Primary auditory cortex, Primary sensory cortex, Principal Sulcus, Pro motor area, Putamen, Putamen; caudal, Putamen; rostral, Retrosplenial area 30, Rostral area 12, Rostral area 14, Rostral field of entorhinal cortex, Rostral part of area 36, SMA - rostral part, Secondary somatosensory cortex, Subiculum, body portion, Subiculum, uncal portion, Superior temporal area 1, Superior temporal area 2, Superior temporal area 3, Superior temporal sulcus, Superior temporal sulcus, dorsal, Temporal area TAa, Temporal area TF, Temporal area TF (lateral part), Temporal area TF (medial part), Temporal area TH, Temporal parietooccipital associated area in superior temporal sulcus, Temporal proisocortex, Temporoparietal asscociated area (caudal part), Temporoparietal associated area (intermediate part), Temporoparietal associated area (rostral part), Temporoparietal cortex, Temporopolar area TG, Transitional sensory area, Ventral area 10, Ventral area 46, Ventral dysgranular area of temporal polar cortex, Ventral intraparietal area, Visual area 4, Visual area V6A, accessory basal nucleus (amygdala), magnocellular subdivision, anterior lateral auditory belt, area 24, area dentata (dentate gyrus), belt line of the sensory system according to CP99, belt line of the sensorymotor system according to CP99, caudal lateral auditory (belt), central nucleus of the amygdala, dorsal area 9, lateral nucleus (amygdala), ventrolateral subdivision, orofacial representation in MI, periamygdaloid cortex, posterior lateral auditory area, prosubiculum, rostroventral parietal area as defined in DLRPK03, substantia nigra, temporal visual association area in the lower bank of the superior temporal sulcus, ventral anterior nucleus (thalamus), ventral striatal shell

Sub-regions:
Area 32, Area 8, Fascia dentata hippocampi, Orbital prefrontal

cortex

Region: Orbital prefrontal cortex (PFCorb)

Super-regions:
Orbital prefrontal cortex < Prefrontal Cortex <
Cortical area FL < GM-CerebralCortex < Brain

Sources:
Insula, Secondary somatosensory cortex

Descendant sources:
Accessor basal nucleus (amygdala), ventromedial division, Accessory basal amygdaloid nucleus, parvicellular part, Agranular area of temporal polar cortex, Agranular frontal area 5 (= rostral ventrolateral premotor area), Agranular insula, Amygdala, Anterior medial nucleus, Anterior nuclei of the thalamus, Area 1, Area 10, Area 11, Area 12, Area 23, Area 24a, Area 24b, Area 24c (rostral part of the cingulate sulcus), Area 24d (rostral part of the cingulate sulcus), Area 25, Area 3, Area 32, Area 35, Area 36, Area 6, Area 6 (ventral part), Area 7b, Area 8, Area 9, Area X (thalamus), Basal amygdaloid nucleus, intermediate part, Basolateral nucleus of amygdala, CA1 subfield of Ammon`s horn, CA3 subfield of Ammons horn, Caudal limiting field of entorhinal cortex, Central inferotemporal area (ventral), Centrum medianum thalami, Cortical area 29a-c, Cortical area 44, Cortical area 45, Cortical area 46, Dorsal area 46, Dorsal dysgranular area of temporal polar cortex, Dysgranular Temporopolar Cortex, Dysgranular insular cortex, Entorhinal cortex, Entorhinal cortex, Granular area of temporal polar cortex, Granular insular cortex, Gustatory cortex, Hippocampus, Hypothalamus, Inferotemporal area TE, Insula, Insular proisocortex, Intermediate agranula insular cortex, Intermediate field of entorhinal cortex, Intralaminar nuclei of the thalamus, LGN external magnocellular layer, LGN layer 2, Lateral agranular insular cortex, Lateral area 11, Lateral area 12, Lateral auditory field, Lateral field (caudal part) of entorhinal cortex, Lateral field (rostral part) of entorhinal cortex, Lateral field of entorhinal cortex, Medial agranular insular cortex, Medial area 10, Medial area 11, Medial area 12, Medial area 9, Medial basal nucleus of the amygdala, Medial premotor area 6M, Midline nuclei of the thalamus, Nucleus basalis thalami, Nucleus centralis densocellularis thalami, Nucleus centralis inferior thalami, Nucleus centralis intermedialis thalami, Nucleus centralis latocellularis thalami, Nucleus centralis superior lateralis thalami, Nucleus centralis superior thalami, Nucleus limitans thalami, Nucleus medialis dorsalis thalami, Nucleus medialis dorsalis thalami, pars caudodorsalis, Nucleus medialis dorsalis thalami, pars densocellularis, Nucleus medialis dorsalis thalami, pars fibrosa, Nucleus medialis dorsalis thalami, pars magnocellularis, Nucleus medialis dorsalis thalami, pars paramediana, Nucleus medialis dorsalis thalami, pars parvocellularis, Nucleus paracentralis thalami, Nucleus parafascicularis thalami, Nucleus parataenialis thalami, Nucleus paraventricularis thalami, pars anterior, Nucleus pulvinaris medialis thalami, Nucleus pulvinaris thalami, Nucleus reuniens thalami, Nucleus ventralis anterior thalami, pars magnocellularis, Nucleus ventralis anterior thalami, pars parvocellularis, Nucleus ventralis lateralis thalami, pars medialis, Nucleus ventralis posterior medialis thalami, Olfactory Complex, Olfactory field of entorhinal cortex, Orbital area 10, Orbital area 12, Orbitofrontal area 13, Orbitofrontal area 13, lateral part, Orbitofrontal area 13, medial part, Orbitofrontal area 13a, Orbitofrontal cortex, agranular periallocortical, Periamygdaloid cortex 2, Piriform cortex, Postcentral area 3b, Posterior Nucleii of Thalamus, Posteromedial agranular insular cortex, Precentral opercular area, Premotor area 6 (dorsal part), Premotor area 6Va, Premotor area 6Vb, Presubiculum, Primary auditory cortex, Primary sensory cortex, Primary somatosensory cortex, Rostral area 12, Rostral area 14, Rostral field of entorhinal cortex, Rostral inferior parietal lobule, Secondary somatosensory cortex, Subiculum, body portion, Subiculum, uncal portion, Superior temporal area 1, Superior temporal area 2, Superior temporal area 3, Superior temporal sulcus, Temporal area TA, Temporal area TF, Temporal area TH, Temporopolar area TG, Ventral area 46, Ventral dysgranular area of temporal polar cortex, accessory basal nucleus (amygdala), magnocellular subdivision, amygdalohippocampal

area, anterior amygdaloid area, area 24, area dentata (dentate gyrus), belt line of the sensory system according to CP99, belt line of the sensorymotor system according to CP99, cortical nucleus, anterior division, dorsal area 9, periamygdaloid cortex, prosubiculum, ventral anterior nucleus (thalamus), ventral lateral nucleus (thalamus), ventral striatal shell

Targets:
Area 10, Area 11, Area 32, Lateral area 12, Medial area 9, Orbital area 12, Secondary somatosensory cortex, Temporopolar area TG

Descendant targets:
Agranular area of temporal polar cortex, Anterior medial nucleus, Area 10, Area 11, Area 23, Area 23b, Area 23c, Area 24a, Area 24b, Area 24c (rostral part of the cingulate sulcus), Area 25, Area 3, Area 31, Area 32, Area 35, Area 36, Area 6 (ventral part), Area 7b, Area 8B, Area 9, Basal amygdaloid nucleus, intermediate part, Caudal limiting field of entorhinal cortex, Caudal part of area 36, Central inferotemporal area (ventral), Cortical area 46, Cortical area 9\/46d, Cortical area 9\/46v, Dorsal dysgranular area of temporal polar cortex, Entorhinal cortex, Entorhinal cortex, Granular area of temporal polar cortex, Gustatory cortex, Inferotemporal area TE, Intermediate agranula insular cortex, Intermediate field of entorhinal cortex, LGN external magnocellular layer, Lateral agranular insular cortex, Lateral area 11, Lateral area 12, Lateral auditory field, Lateral field (caudal part) of entorhinal cortex, Lateral field (rostral part) of entorhinal cortex, Lateral nucleus (amygdala), dorsal division, Lateral nucleus (amygdala), dorsal intermediate division, Lateral nucleus (amygdala), ventral division, Medial agranular insular cortex, Medial area 10, Medial area 11, Medial area 12, Medial area 9, Nucleus caudatus, Nucleus centralis inferior thalami, Nucleus centralis intermedialis thalami, Nucleus centralis superior thalami, Nucleus limitans thalami, Nucleus medialis dorsalis thalami, Nucleus medialis dorsalis thalami, pars fibrosa, Nucleus medialis dorsalis thalami, pars magnocellularis, Nucleus medialis dorsalis thalami, pars paramediana, Nucleus parataenialis thalami, Nucleus paraventricularis thalami, pars anterior, Nucleus pulvinaris medialis thalami, Nucleus pulvinaris thalami, Nucleus reuniens thalami, Nucleus suprageniculatus thalami, Nucleus ventralis anterior thalami, pars magnocellularis, Nucleus ventralis lateralis thalami, pars medialis, Olfactory field of entorhinal cortex, Orbital area 10, Orbital area 12, Orbital part of area 14, Orbitofrontal area 13, Orbitofrontal area 13, lateral part, Orbitofrontal area 13, medial part, Orbitofrontal area 13a, Orbitofrontal area 14, Posteromedial agranular insular cortex, Precentral opercular area, Prefrontal area 47\/12, Premotor area 6Va, Primary auditory cortex, Primary sensory cortex, Pro motor area, Putamen; rostral, Rostral area 12, Rostral area 14, Rostral field of entorhinal cortex, Rostral part of area 36, Secondary somatosensory cortex, Subiculum, body portion, Subiculum, uncal portion, Superior temporal area 1, Superior temporal area 2, Superior temporal sulcus, Superior temporal sulcus, dorsal, Temporal area TF, Temporal area TF (lateral part), Temporal area TF (medial part), Temporal area TH, Temporal proisocortex, Temporopolar area TG, Ventral dysgranular area of temporal polar cortex, accessory basal nucleus (amygdala), magnocellular subdivision, area 24, area dentata (dentate gyrus), belt line of the sensory system according to CP99, belt line of the sensorymotor system according to CP99, central nucleus of the amygdala, dorsal area 9, lateral nucleus (amygdala), ventrolateral subdivision, orofacial representation in MI, periamygdaloid cortex, posterior lateral auditory area, prosubiculum, ventral striatal shell

Sub-regions:
Orbitofrontal area 13, Orbitofrontal area 14, Orbitofrontal cortex, agranular periallocortical, Orbitofrontal opercular area

---
Region: Orbitofrontal area 14 (14)

Super-regions:
Orbitofrontal area 14 < Orbital prefrontal cortex < Prefrontal Cortex < Cortical area FL < GM-CerebralCortex < Brain

Sources:
Accessor basal nucleus (amygdala), ventromedial division, Accessory basal amygdaloid nucleus, parvicellular part, Agranular insula, Amygdala, Anterior medial nucleus, Anterior nuclei of the thalamus, Area 10, Area 11, Area 12, Area 25, Area 32, Area 35, Area 36, Area 8, Area 9, Area X (thalamus), Basal amygdaloid nucleus, intermediate part, Basolateral nucleus of amygdala, CA1 subfield of Ammon`s horn, Cortical area 29a-c, Cortical area 46, Dorsal area 46, Dysgranular Temporopolar Cortex, Dysgranular insular cortex, Entorhinal cortex, Inferotemporal area TE, Intralaminar nuclei of the thalamus, Lateral area 12, Lateral auditory field, Medial area 9, Medial basal nucleus of the amygdala, Midline nuclei of the thalamus, Nucleus basalis thalami, Nucleus centralis densocellularis thalami, Nucleus centralis inferior thalami, Nucleus centralis intermedialis thalami, Nucleus centralis latocellularis thalami, Nucleus centralis superior lateralis thalami, Nucleus centralis superior thalami, Nucleus limitans thalami, Nucleus medialis dorsalis thalami, Nucleus medialis dorsalis thalami, pars caudodorsalis, Nucleus medialis dorsalis thalami, pars densocellularis, Nucleus medialis dorsalis thalami, pars magnocellularis, Nucleus medialis dorsalis thalami, pars paramediana, Nucleus medialis dorsalis thalami, pars parvocellularis, Nucleus paracentralis thalami, Nucleus parafascicularis thalami, Nucleus parataenialis thalami, Nucleus paraventricularis thalami, pars anterior, Nucleus pulvinaris medialis thalami, Nucleus reuniens thalami, Nucleus ventralis anterior thalami, pars magnocellularis, Nucleus ventralis lateralis thalami, pars medialis, Olfactory Complex, Orbital area 12, Orbitofrontal area 13, Orbitofrontal cortex, agranular periallocortical, Piriform cortex, Presubiculum, Primary auditory cortex, Superior temporal area 1, Superior temporal area 2, Superior temporal area 3, Superior temporal sulcus, Temporopolar area TG, Ventral area 46, accessory basal nucleus (amygdala), magnocellular subdivision, amygdalohippocampal area, area 24, dorsal area 9, prosubiculum, ventral anterior nucleus (thalamus), ventral lateral nucleus (thalamus), ventral striatal shell

Descendant sources:
Accessory basal amygdaloid nucleus, parvicellular part, Agranular area of temporal polar cortex, Anterior medial nucleus, Area 10, Area 24a, Area 24b, Area 25, Area 32, Area 9, Basal amygdaloid nucleus, intermediate part, CA3 subfield of Ammons horn, Caudal limiting field of entorhinal cortex, Cortical area 45, Cortical area 46, Dorsal dysgranular area of temporal polar cortex, Entorhinal cortex, Granular area of temporal polar cortex, Intermediate agranula insular cortex, Intermediate field of entorhinal cortex, Lateral agranular insular cortex, Lateral area 11, Lateral area 12, Lateral auditory field, Medial agranular insular cortex, Medial area 10, Medial area 11, Medial area 12, Nucleus ventralis anterior thalami, pars magnocellularis, Nucleus ventralis anterior thalami, pars parvocellularis, Orbital area 10, Orbital area 12, Orbitofrontal area 13, Orbitofrontal area 13a, Posteromedial agranular insular cortex, Rostral area 12, Rostral field of entorhinal cortex, Subiculum, body portion, Subiculum, uncal portion, Temporal area TA, Temporal area TF, Temporal area TH, accessory basal nucleus (amygdala), magnocellular subdivision, area dentata (dentate gyrus), ventral striatal shell

Targets:
Area 10, Area 11, Area 23, Area 23b, Area 23c, Area 24c (rostral part of the cingulate sulcus), Area 25, Area 32, Area 36, Area 8B, Area 9, Cortical area 46, Cortical area 9\/46d, Entorhinal cortex, Entorhinal cortex, Lateral area 12, Lateral nucleus (amygdala), dorsal division, Lateral nucleus (amygdala), dorsal intermediate division, Lateral nucleus (amygdala), ventral division, Medial area 9, Nucleus caudatus, Nucleus medialis dorsalis thalami, Nucleus medialis dorsalis thalami, pars magnocellularis, Nucleus ventralis anterior thalami, pars magnocellularis, Primary auditory cortex, Rostral part of area 36, Superior temporal area 1, Superior temporal area 2, Superior temporal sulcus,

Superior temporal sulcus, dorsal, Temporal area TF (lateral part), Temporal area TF (medial part), Temporopolar area TG, area 24, dorsal area 9, lateral nucleus (amygdala), ventrolateral subdivision

Descendant targets:
Agranular area of temporal polar cortex, Area 24a, Area 24b, Area 25, Area 32, Area 9, Cortical area 46, Dorsal dysgranular area of temporal polar cortex, Granular area of temporal polar cortex, Intermediate agranula insular cortex, Lateral area 11, Medial agranular insular cortex, Medial area 10, Medial area 11, Nucleus caudatus, Orbital area 10, Orbital area 12, Orbitofrontal area 13, lateral part, Orbitofrontal area 13, medial part, Orbitofrontal area 13a, Posteromedial agranular insular cortex, Primary sensory cortex, Putamen; rostral, Rostral area 12

Sub-regions:
Orbital part of area 14, Rostral area 14

Region: Orbital part of area 14 (14O)

Super-regions:
Orbital part of area 14 < Orbitofrontal area 14 < Orbital prefrontal cortex < Prefrontal Cortex < Cortical area FL < GM-CerebralCortex < Brain

Sources:
Area 10, Area 32, Orbital area 12, Orbitofrontal area 13

Targets:
Area 32

Region: Rostral area 14 (14r)

Super-regions:
Rostral area 14 < Orbitofrontal area 14 < Orbital prefrontal cortex < Prefrontal Cortex < Cortical area FL < GM-CerebralCortex < Brain

Sources:
Accessory basal amygdaloid nucleus, parvicellular part, Agranular area of temporal polar cortex, Anterior medial nucleus, Area 24a, Area 24b, Area 25, Area 32, Area 9, Basal amygdaloid nucleus, intermediate part, CA3 subfield of Ammons horn, Caudal limiting field of entorhinal cortex, Cortical area 45, Cortical area 46, Dorsal dysgranular area of temporal polar cortex, Entorhinal cortex, Granular area of temporal polar cortex, Intermediate agranula insular cortex, Intermediate field of entorhinal cortex, Lateral agranular insular cortex, Lateral area 11, Lateral area 12, Lateral auditory field, Medial agranular insular cortex, Medial area 10, Medial area 11, Medial area 12, Nucleus ventralis anterior thalami, pars magnocellularis, Nucleus ventralis anterior thalami, pars parvocellularis, Orbital area 10, Orbital area 12, Orbitofrontal area 13a, Posteromedial agranular insular cortex, Rostral area 12, Rostral field of entorhinal cortex, Subiculum, body portion, Subiculum, uncal portion, Temporal area TA, Temporal area TF, Temporal area TH, accessory basal nucleus (amygdala), magnocellular subdivision, area dentata (dentate gyrus), ventral striatal shell

Targets:
Agranular area of temporal polar cortex, Area 24a, Area 24b, Area 25, Area 32, Area 9, Cortical area 46, Dorsal dysgranular area of temporal polar cortex, Granular area of temporal polar cortex, Intermediate agranula insular cortex, Lateral area 11, Medial agranular insular cortex, Medial area 10, Medial area 11, Nucleus caudatus, Orbital area 10, Orbital area 12, Orbitofrontal area 13, lateral part,

Orbitofrontal area 13, medial part, Orbitofrontal area 13a, Posteromedial agranular insular cortex, Primary sensory cortex, Putamen; rostral, Rostral area 12

Region: Orbitofrontal cortex, agranular periallocortical (OFap)

Super-regions:
Orbitofrontal cortex, agranular periallocortical < Orbital prefrontal cortex < Prefrontal Cortex < Cortical area FL < GM-CerebralCortex < Brain

Sources:
Insula, area 24

Targets:
Area 32, Nucleus medialis dorsalis thalami, Orbitofrontal area 14, Temporal proisocortex, Temporopolar area TG, area 24

Region: Orbitofrontal opercular area (OFO)

Super-regions:
Orbitofrontal opercular area < Orbital prefrontal cortex < Prefrontal Cortex < Cortical area FL < GM-CerebralCortex < Brain

Sources:
area 24

Descendant sources:
Agranular frontal area 5 (= rostral ventrolateral premotor area), Agranular insula, Area 1, Area 12, Area 23, Area 24d (rostral part of the cingulate sulcus), Area 3, Area 6, Area 6 (ventral part), Area 7b, Cortical area 44, Cortical area 46, Dysgranular insular cortex, Granular insular cortex, Gustatory cortex, Insular proisocortex, LGN layer 2, Lateral agranular insular cortex, Lateral auditory field, Medial agranular insular cortex, Medial premotor area 6M, Nucleus medialis dorsalis thalami, Nucleus ventralis posterior medialis thalami, Orbitofrontal area 13, Orbitofrontal area 13, lateral part, Rostral inferior parietal lobule, Secondary somatosensory cortex, Ventral area 46, belt line of the sensory system according to CP99, belt line of the sensorymotor system according to CP99

Targets:
area 24

Descendant targets:
Area 10, Area 3, Area 6 (ventral part), Area 7b, Cortical area 9\/46v, Medial area 12, Nucleus medialis dorsalis thalami, Orbital area 12, Orbitofrontal area 13, Orbitofrontal area 13, lateral part, Orbitofrontal area 13, medial part, Posteromedial agranular insular cortex, Pro motor area, Secondary somatosensory cortex, belt line of the sensory system according to CP99, belt line of the sensorymotor system according to CP99

Sub-regions:
Gustatory cortex, Pro motor area

Region: Pro motor area (ProM#2)

Super-regions:
Pro motor area < Orbitofrontal opercular area < Orbital prefrontal cortex < Prefrontal Cortex < Cortical area FL < GM-CerebralCortex < Brain

Sources:
Agranular frontal area 5 (= rostral ventrolateral premotor area), Agranular insula, Area 1, Area 12, Area 23, Area 24d (rostral part of the cingulate sulcus), Area 3, Area 6, Area 6 (ventral part), Area 7b, Cortical area 44,

Cortical area 46, Dysgranular insular cortex, Granular insular cortex, Gustatory cortex, Insular proisocortex, LGN layer 2, Medial premotor area 6M, Orbitofrontal area 13, Secondary somatosensory cortex, Ventral area 46, belt line of the sensory system according to CP99, belt line of the sensorymotor system according to CP99

Targets:
Area 3, Area 6 (ventral part), Area 7b, Cortical area 9\/46v, Nucleus medialis dorsalis thalami, Secondary somatosensory cortex, belt line of the sensory system according to CP99, belt line of the sensorymotor system according to CP99

Region: Gustatory cortex (Gu)

Super-regions:
Gustatory cortex < Orbitofrontal opercular area < Orbital prefrontal cortex < Prefrontal Cortex < Cortical area FL < GM-CerebralCortex < Brain

Sources:
Agranular frontal area 5 (= rostral ventrolateral premotor area), Lateral agranular insular cortex, Lateral auditory field, Medial agranular insular cortex, Nucleus medialis dorsalis thalami, Nucleus ventralis posterior medialis thalami, Orbitofrontal area 13, lateral part, Rostral inferior parietal lobule, belt line of the sensory system according to CP99, belt line of the sensorymotor system according to CP99

Targets:
Area 10, Medial area 12, Nucleus medialis dorsalis thalami, Orbital area 12, Orbitofrontal area 13, Orbitofrontal area 13, lateral part, Orbitofrontal area 13, medial part, Posteromedial agranular insular cortex, Pro motor area, Secondary somatosensory cortex, belt line of the sensory system according to CP99, belt line of the sensorymotor system according to CP99

Region: Orbitofrontal area 13 (13)

Super-regions:
Orbitofrontal area 13 < Orbital prefrontal cortex < Prefrontal Cortex < Cortical area FL < GM-CerebralCortex < Brain

Sources:
Accessor basal nucleus (amygdala), ventromedial division, Accessory basal amygdaloid nucleus, parvicellular part, Agranular area of temporal polar cortex, Agranular insula, Amygdala, Anterior medial nucleus, Area 32, Area 35, Area 36, Basal amygdaloid nucleus, intermediate part, Basolateral nucleus of amygdala, CA1 subfield of Ammon`s horn, Central inferotemporal area (ventral), Centrum medianum thalami, Cortical area 29a-c, Cortical area 46, Dysgranular insular cortex, Granular area of temporal polar cortex, Gustatory cortex, Hippocampus, Hypothalamus, Inferotemporal area TE, Intermediate agranula insular cortex, LGN external magnocellular layer, Lateral agranular insular cortex, Lateral auditory field, Medial basal nucleus of the amygdala, Nucleus basalis thalami, Nucleus centralis densocellularis thalami, Nucleus centralis latocellularis thalami, Nucleus limitans thalami, Nucleus medialis dorsalis thalami, Nucleus medialis dorsalis thalami, pars fibrosa, Nucleus medialis dorsalis thalami, pars magnocellularis, Nucleus medialis dorsalis thalami, pars paramediana, Nucleus paracentralis thalami, Nucleus parafascicularis thalami, Nucleus parataenialis thalami, Nucleus pulvinaris medialis thalami, Nucleus pulvinaris thalami, Nucleus reuniens thalami, Nucleus ventralis anterior thalami, pars magnocellularis, Olfactory Complex, Orbital area 12, Periamygdaloid cortex 2,

Posteromedial agranular insular cortex, Precentral opercular area, Premotor area 6Vb, Presubiculum, Primary sensory cortex, Primary somatosensory cortex, Superior temporal sulcus, Temporal area TA, Temporopolar area TG, Ventral area 46, Ventral dysgranular area of temporal polar cortex, accessory basal nucleus (amygdala), magnocellular subdivision, anterior amygdaloid area, area 24, periamygdaloid cortex, prosubiculum, ventral anterior nucleus (thalamus), ventral striatal shell

Descendant sources:

Accessory basal amygdaloid nucleus, parvicellular part, Agranular area of temporal polar cortex, Anterior medial nucleus, Area 24a, Area 24b, Area 24c (rostral part of the cingulate sulcus), Area 25, Area 32, Area 35, Area 36, Area 9, Basal amygdaloid nucleus, intermediate part, CA1 subfield of Ammon`s horn, CA3 subfield of Ammons horn, Caudal limiting field of entorhinal cortex, Cortical area 45, Cortical area 46, Dysgranular insular cortex, Entorhinal cortex, Entorhinal cortex, Granular area of temporal polar cortex, Gustatory cortex, Inferotemporal area TE, Intermediate agranula insular cortex, Intermediate field of entorhinal cortex, Lateral agranular insular cortex, Lateral area 11, Lateral area 12, Lateral auditory field, Lateral field (caudal part) of entorhinal cortex, Lateral field (rostral part) of entorhinal cortex, Lateral field of entorhinal cortex, Medial agranular insular cortex, Medial area 10, Medial area 11, Medial area 12, Nucleus basalis thalami, Nucleus centralis superior lateralis thalami, Nucleus medialis dorsalis thalami, Nucleus medialis dorsalis thalami, pars fibrosa, Nucleus medialis dorsalis thalami, pars paramediana, Olfactory Complex, Olfactory field of entorhinal cortex, Orbital area 10, Orbital area 12, Orbitofrontal area 13, lateral part, Orbitofrontal area 13, medial part, Orbitofrontal area 13a, Piriform cortex, Postcentral area 3b, Posterior Nucleii of Thalamus, Posteromedial agranular insular cortex, Precentral opercular area, Premotor area 6 (dorsal part), Premotor area 6Va, Premotor area 6Vb, Primary somatosensory cortex, Rostral area 12, Rostral area 14, Rostral field of entorhinal cortex, Subiculum, body portion, Subiculum, uncal portion, Temporal area TA, Temporal area TF, Temporal area TH, Ventral dysgranular area of temporal polar cortex, accessory basal nucleus (amygdala), magnocellular subdivision, cortical nucleus, anterior division, periamygdaloid cortex, prosubiculum, ventral striatal shell

Targets:

Area 10, Area 11, Area 23b, Area 23c, Area 24c (rostral part of the cingulate sulcus), Area 25, Area 31, Area 32, Area 35, Area 36, Area 8B, Area 9, Basal amygdaloid nucleus, intermediate part, Caudal limiting field of entorhinal cortex, Caudal part of area 36, Central inferotemporal area (ventral), Cortical area 9\/46d, Cortical area 9\/46v, Entorhinal cortex, Entorhinal cortex, Lateral area 12, Lateral field (caudal part) of entorhinal cortex, Lateral field (rostral part) of entorhinal cortex, Lateral nucleus (amygdala), dorsal division, Lateral nucleus (amygdala), dorsal intermediate division, Lateral nucleus (amygdala), ventral division, Medial area 9, Nucleus caudatus, Nucleus centralis intermedialis thalami, Nucleus centralis superior thalami, Nucleus limitans thalami, Nucleus medialis dorsalis thalami, Nucleus medialis dorsalis thalami, pars fibrosa, Nucleus medialis dorsalis thalami, pars magnocellularis, Nucleus medialis dorsalis thalami, pars paramediana, Nucleus parataenialis thalami, Nucleus paraventricularis thalami, pars anterior, Nucleus pulvinaris medialis thalami, Nucleus pulvinaris thalami, Nucleus reuniens thalami, Nucleus suprageniculatus thalami, Nucleus ventralis lateralis thalami, pars medialis, Olfactory field of entorhinal cortex, Orbital area 12, Orbital part of area 14, Orbitofrontal area 14, Prefrontal area 47\/12, Primary auditory cortex, Pro motor area, Rostral field of entorhinal cortex, Rostral part of area 36, Superior temporal area 1, Superior temporal area 2, Temporal area TF (lateral part), Temporal area TF (medial part), Temporal area TH, Temporal proisocortex, Temporopolar area TG, accessory basal nucleus (amygdala), magnocellular subdivision, area

24, belt line of the sensory system according to CP99, belt line of the sensorymotor system according to CP99, dorsal area 9, lateral nucleus (amygdala), ventrolateral subdivision, orofacial representation in MI, posterior lateral auditory area

Descendant targets:
Agranular area of temporal polar cortex, Anterior medial nucleus, Area 11, Area 24a, Area 24b, Area 24c (rostral part of the cingulate sulcus), Area 25, Area 32, Area 35, Area 36, Area 9, Basal amygdaloid nucleus, intermediate part, Caudal limiting field of entorhinal cortex, Caudal part of area 36, Cortical area 46, Entorhinal cortex, Entorhinal cortex, Granular area of temporal polar cortex, Gustatory cortex, Inferotemporal area TE, Intermediate agranula insular cortex, Intermediate field of entorhinal cortex, LGN external magnocellular layer, Lateral agranular insular cortex, Lateral area 11, Lateral area 12, Lateral auditory field, Lateral field (caudal part) of entorhinal cortex, Lateral field (rostral part) of entorhinal cortex, Lateral nucleus (amygdala), dorsal division, Lateral nucleus (amygdala), dorsal intermediate division, Lateral nucleus (amygdala), ventral division, Medial agranular insular cortex, Medial area 10, Medial area 11, Medial area 12, Nucleus caudatus, Nucleus centralis inferior thalami, Nucleus medialis dorsalis thalami, Nucleus medialis dorsalis thalami, pars magnocellularis, Nucleus ventralis anterior thalami, pars magnocellularis, Olfactory field of entorhinal cortex, Orbital area 10, Orbital area 12, Orbitofrontal area 13, lateral part, Orbitofrontal area 13, medial part, Orbitofrontal area 13a, Posteromedial agranular insular cortex, Precentral opercular area, Premotor area 6Va, Primary sensory cortex, Putamen; rostral, Rostral area 12, Rostral area 14, Rostral field of entorhinal cortex, Subiculum, body portion, Subiculum, uncal portion, Temporal area TF, Temporal area TH, Ventral dysgranular area of temporal polar cortex, accessory basal nucleus (amygdala), magnocellular subdivision, area dentata (dentate gyrus), central nucleus of the amygdala, lateral nucleus (amygdala), ventrolateral subdivision, periamygdaloid cortex, prosubiculum, ventral striatal shell

Sub-regions:
Orbitofrontal area 13, lateral part, Orbitofrontal area 13, medial part, Orbitofrontal area 13a

---
Region: Orbitofrontal area 13, lateral part (13L)

Super-regions:
Orbitofrontal area 13, lateral part < Orbitofrontal area 13 < Orbital prefrontal cortex < Prefrontal Cortex < Cortical area FL < GM-CerebralCortex < Brain

Sources:
Area 24b, Area 25, Area 32, Area 36, Area 9, Cortical area 45, Cortical area 46, Dysgranular insular cortex, Gustatory cortex, Inferotemporal area TE, Intermediate agranula insular cortex, Lateral agranular insular cortex, Lateral area 11, Lateral area 12, Medial agranular insular cortex, Medial area 10, Medial area 11, Medial area 12, Orbital area 10, Orbital area 12, Orbitofrontal area 13, medial part, Orbitofrontal area 13a, Postcentral area 3b, Posteromedial agranular insular cortex, Precentral opercular area, Premotor area 6 (dorsal part), Premotor area 6Va, Premotor area 6Vb, Primary somatosensory cortex, Rostral area 12, Rostral area 14, Temporal area TA

Targets:
Area 32, Gustatory cortex, Intermediate agranula insular cortex, Lateral area 11, Lateral area 12, Medial area 12, Nucleus caudatus, Orbital area 10, Orbital area 12, Orbitofrontal area 13, medial part, Orbitofrontal area 13a, Posteromedial agranular insular cortex, Primary sensory cortex, Putamen; rostral, Rostral area 12

Region: Orbitofrontal area 13, medial part (13M)

Super-regions:
Orbitofrontal area 13, medial part < Orbitofrontal area 13 < Orbital prefrontal cortex < Prefrontal Cortex < Cortical area FL < GM-CerebralCortex < Brain

Sources:
Agranular area of temporal polar cortex, Area 24b, Area 24c (rostral part of the cingulate sulcus), Area 25, Area 32, Area 35, Granular area of temporal polar cortex, Gustatory cortex, Intermediate agranula insular cortex, Lateral agranular insular cortex, Lateral area 11, Lateral area 12, Medial agranular insular cortex, Medial area 10, Medial area 11, Medial area 12, Orbital area 12, Orbitofrontal area 13, lateral part, Orbitofrontal area 13a, Posteromedial agranular insular cortex, Precentral opercular area, Rostral area 12, Rostral area 14, Ventral dysgranular area of temporal polar cortex

Targets:
Area 11, Intermediate agranula insular cortex, Lateral area 11, Lateral area 12, Medial area 11, Medial area 12, Nucleus caudatus, Orbital area 10, Orbital area 12, Orbitofrontal area 13, lateral part, Orbitofrontal area 13a, Posteromedial agranular insular cortex, Primary sensory cortex, Putamen; rostral, Rostral area 12

Region: Orbitofrontal area 13a (13a)

Super-regions:
Orbitofrontal area 13a < Orbitofrontal area 13 < Orbital prefrontal cortex < Prefrontal Cortex < Cortical area FL < GM-CerebralCortex < Brain

Sources:
Accessory basal amygdaloid nucleus, parvicellular part, Agranular area of temporal polar cortex, Anterior medial nucleus, Area 24a, Area 24b, Area 24c (rostral part of the cingulate sulcus), Area 25, Area 32, Area 35, Area 36, Area 9, Basal amygdaloid nucleus, intermediate part, CA1 subfield of Ammon`s horn, CA3 subfield of Ammons horn, Caudal limiting field of entorhinal cortex, Cortical area 45, Cortical area 46, Entorhinal cortex, Entorhinal cortex, Granular area of temporal polar cortex, Inferotemporal area TE, Intermediate agranula insular cortex, Intermediate field of entorhinal cortex, Lateral agranular insular cortex, Lateral area 11, Lateral area 12, Lateral auditory field, Lateral field (caudal part) of entorhinal cortex, Lateral field (rostral part) of entorhinal cortex, Lateral field of entorhinal cortex, Medial agranular insular cortex, Medial area 10, Medial area 11, Medial area 12, Nucleus basalis thalami, Nucleus centralis superior lateralis thalami, Nucleus medialis dorsalis thalami, Nucleus medialis dorsalis thalami, pars fibrosa, Nucleus medialis dorsalis thalami, pars paramediana, Olfactory Complex, Olfactory field of entorhinal cortex, Orbital area 10, Orbital area 12, Orbitofrontal area 13, lateral part, Orbitofrontal area 13, medial part, Piriform cortex, Posterior Nucleii of Thalamus, Posteromedial agranular insular cortex, Premotor area 6 (dorsal part), Premotor area 6Va, Premotor area 6Vb, Rostral area 12, Rostral area 14, Rostral field of entorhinal cortex, Subiculum, body portion, Subiculum, uncal portion, Temporal area TA, Temporal area TF, Temporal area TH, Ventral dysgranular area of temporal polar cortex, accessory basal nucleus (amygdala), magnocellular subdivision, cortical nucleus, anterior division, periamygdaloid

cortex, prosubiculum, ventral striatal shell

Targets:
Agranular area of temporal polar cortex, Anterior medial nucleus, Area 11, Area 24a, Area 24b, Area 24c (rostral part of the cingulate sulcus), Area 25, Area 32, Area 35, Area 36, Area 9, Basal amygdaloid nucleus, intermediate part, Caudal limiting field of entorhinal cortex, Caudal part of area 36, Cortical area 46, Entorhinal cortex, Entorhinal cortex, Granular area of temporal polar cortex, Inferotemporal area TE, Intermediate agranula insular cortex, Intermediate field of entorhinal cortex, LGN external magnocellular layer, Lateral agranular insular cortex, Lateral area 11, Lateral area 12, Lateral auditory field, Lateral field (caudal part) of entorhinal cortex, Lateral field (rostral part) of entorhinal cortex, Lateral nucleus (amygdala), dorsal division, Lateral nucleus (amygdala), dorsal intermediate division, Lateral nucleus (amygdala), ventral division, Medial agranular insular cortex, Medial area 10, Medial area 11, Medial area 12, Nucleus caudatus, Nucleus centralis inferior thalami, Nucleus medialis dorsalis thalami, Nucleus medialis dorsalis thalami, pars magnocellularis, Nucleus ventralis anterior thalami, pars magnocellularis, Olfactory field of entorhinal cortex, Orbital area 10, Orbital area 12, Orbitofrontal area 13, lateral part, Orbitofrontal area 13, medial part, Posteromedial agranular insular cortex, Precentral opercular area, Premotor area 6Va, Primary sensory cortex, Putamen; rostral, Rostral area 12, Rostral area 14, Rostral field of entorhinal cortex, Subiculum, body portion, Subiculum, uncal portion, Temporal area TF, Temporal area TH, Ventral dysgranular area of temporal polar cortex, accessory basal nucleus (amygdala), magnocellular subdivision, area dentata (dentate gyrus), central nucleus of the amygdala, lateral nucleus (amygdala), ventrolateral subdivision, periamygdaloid cortex, prosubiculum, ventral striatal shell

---
Region: Area 32 (32)

Super-regions:
Area 32 < Prefrontal Cortex < Cortical area FL < GM-CerebralCortex < Brain

Sources:
Agranular insula, Anterior medial nucleus, Anterior nuclei of the thalamus, Area 10, Area 11, Area 12, Area 23, Area 23a, Area 23b, Area 24a, Area 24b, Area 24c (rostral part of the cingulate sulcus), Area 25, Area 35, Area 8B, Area 9, Area X (thalamus), Basolateral nucleus of amygdala, CA1 subfield of Ammon`s horn, Caudal inferior parietal lobule, Centrum medianum thalami, Cortical area 29a-c, Cortical area 46, Cortical area PGa, Dorsal area 10, Dorsal area 46, Dorsal dysgranular area of temporal polar cortex, Dysgranular Temporopolar Cortex, Dysgranular insular cortex, Entorhinal cortex, Granular area of temporal polar cortex, Granular insular cortex, Inferotemporal area TE, Intermediate agranula insular cortex, Intralaminar nuclei of the thalamus, Lateral area 9, Lateral auditory field, Lateral auditory parakoniocortex, Medial agranular insular cortex, Medial area 10, Medial area 11, Medial area 9, Medial basal nucleus of the amygdala, Midline nuclei of the thalamus, Nucleus anterior ventralis thalami, Nucleus basalis thalami, Nucleus centralis densocellularis thalami, Nucleus centralis inferior thalami, Nucleus centralis intermedialis thalami, Nucleus centralis latocellularis thalami, Nucleus centralis superior lateralis thalami, Nucleus centralis superior thalami, Nucleus limitans thalami, Nucleus medialis dorsalis thalami, Nucleus medialis dorsalis thalami, pars caudodorsalis, Nucleus medialis dorsalis thalami, pars densocellularis, Nucleus medialis dorsalis thalami, pars magnocellularis, Nucleus medialis dorsalis thalami, pars parvocellularis, Nucleus paracentralis thalami, Nucleus parafascicularis thalami, Nucleus paraventricularis thalami, pars anterior, Nucleus pulvinaris medialis thalami, Nucleus pulvinaris thalami,

pars oralis, Nucleus reuniens thalami, Nucleus suprageniculatus thalami, Nucleus ventralis anterior thalami, pars magnocellularis, Orbital area 10, Orbital area 12, Orbital part of area 14, Orbital prefrontal cortex, Orbitofrontal area 13, Orbitofrontal area 13, lateral part, Orbitofrontal area 13a, Orbitofrontal area 14, Orbitofrontal cortex, agranular periallocortical, Piriform cortex, Presubiculum, Primary auditory cortex, Rostral area 14, Secondary auditory cortex, Superior temporal area 1, Superior temporal area 2, Superior temporal area 3, Superior temporal sulcus, Supratemporal cortex, granular, Temporal area TA, Temporal area TF, Temporal area TH, Temporal parietooccipital associated area in superior temporal sulcus, Temporal proisocortex, Temporopolar area TG, Ventral area 10, Ventral area 46, Visual area 2, amygdalohippocampal area, anterior amygdaloid area, area 24, area dentata (dentate gyrus), auditory prokoniocortex, dorsal area 9, periamygdaloid cortex, prosubiculum, ventral anterior nucleus (thalamus), ventral lateral nucleus (thalamus), ventral striatal shell

Targets:
Area 10, Area 11, Area 23, Area 23c, Area 24c (rostral part of the cingulate sulcus), Area 25, Area 36, Area 8B, Area 9, Cortical area 46, Cortical area 9\/46d, Dorsal area 10, Dorsal area 46, Entorhinal cortex, Intermediate agranula insular cortex, Lateral area 11, Lateral area 12, Lateral area 9, Lateral nucleus (amygdala), dorsal division, Lateral nucleus (amygdala), dorsal intermediate division, Lateral nucleus (amygdala), ventral division, Medial area 11, Medial area 9, Nucleus caudatus, Nucleus medialis dorsalis thalami, Nucleus medialis dorsalis thalami, pars caudodorsalis, Nucleus medialis dorsalis thalami, pars magnocellularis, Nucleus medialis dorsalis thalami, pars parvocellularis, Nucleus ventralis anterior thalami, pars magnocellularis, Orbital area 10, Orbital area 12, Orbital part of area 14, Orbitofrontal area 13, Orbitofrontal area 13, lateral part, Orbitofrontal area 13, medial part, Orbitofrontal area 13a, Orbitofrontal area 14, Prefrontal area 47\/12, Primary sensory cortex, Putamen; rostral, Rostral area 14, Rostral part of area 36, Superior temporal area 1, Superior temporal area 2, Superior temporal area 3, Superior temporal sulcus, Superior temporal sulcus, dorsal, Temporal area TF (lateral part), Temporal parietooccipital associated area in superior temporal sulcus, Temporal proisocortex, Ventral area 10, area 24, dorsal area 9, lateral nucleus (amygdala), ventrolateral subdivision

---
Region: Fascia dentata hippocampi (FD#1)

Super-regions:
Fascia dentata hippocampi < Prefrontal Cortex < Cortical area FL < GM-CerebralCortex < Brain

Sources:
Accessory basal amygdaloid nucleus, parvicellular part, Agranular frontal area 6 (= pre-SMA), Area 23a, Area 23b, Area 23c, Area 24a, Area 24b, Area 24c (rostral part of the cingulate sulcus), Basal amygdaloid nucleus, intermediate part, Centrum medianum thalami, Hypothalamus, Lateral auditory field, Medial premotor area 6M, Nucleus centralis densocellularis thalami, Nucleus limitans thalami, Nucleus medialis dorsalis thalami, pars densocellularis, Nucleus medialis dorsalis thalami, pars magnocellularis, Nucleus medialis dorsalis thalami, pars parvocellularis, Nucleus paracentralis thalami, Nucleus parafascicularis thalami, Nucleus pulvinaris medialis thalami, Premotor area 6 (dorsal part), Primary sensory cortex, accessory basal nucleus (amygdala), magnocellular subdivision, ventral anterior nucleus (thalamus)

Descendant sources:
Accessor basal nucleus (amygdala), ventromedial division, Accessory basal amygdaloid nucleus, parvicellular part, Agranular area of temporal polar cortex, Agranular frontal area 4 (= caudal ventrolateral premotor area), Agranular frontal area 5 (= rostral ventrolateral premotor area), Agranular frontal area 6 (= pre-SMA), Agranular frontal area 7 (= rostral dorsolateral premotor area), Agranular insula, Amygdala, Anterior inferotemporal area (dorsal), Anterior inferotemporal area (ventral), Anterior intraparietal area, Anterior medial nucleus, Anterior nuclei of the thalamus, Area 1, Area 10, Area 11, Area 12, Area 23, Area 23a, Area 23b, Area 23c, Area 24a,

Area 24b, Area 24c (rostral part of the cingulate sulcus), Area 24d (rostral part of the cingulate sulcus), Area 25, Area 29, Area 29d, Area 31, Area 32, Area 35, Area 36, Area 46 (dorsal rim of the principal sulcus), Area 46 (fundus of the principal sulcus), Area 46 (ventral rim of the principal sulcus), Area 6, Area 6 (ventral part), Area 7, Area 7a, Area 7b, Area 8, Area 8A, Area 8B, Area 9, Area X (thalamus), Basal amygdaloid nucleus, intermediate part, Basolateral nucleus of amygdala, CA1 subfield of Ammon`s horn, CA3 subfield of Ammons horn, Caudal auditory parakoniocortex, Caudal inferior parietal lobule, Caudal limiting field of entorhinal cortex, Caudomedial lobule, Central amygdaloid nucleus, lateral part, Central inferotemporal area, Central inferotemporal area (dorsal), Central inferotemporal area (ventral), Centrum medianum thalami, Claustrum, Corpus geniculatum mediale, Cortical amygdaloid nucleus, Cortical area 29a-c, Cortical area 44, Cortical area 45, Cortical area 45A, Cortical area 45B, Cortical area 46, Cortical area 9\/46d, Cortical area 9\/46v, Cortical area PGa, Cortical area TEm, Dorsal area 46, Dorsal dysgranular area of temporal polar cortex, Dorsal portion of area 8A, Dorsal prelunate gyrus, Dysgranular Temporopolar Cortex, Dysgranular insular cortex, Entorhinal cortex, Entorhinal cortex, Extrastriate area OA, Frontal eye field, Granular area of temporal polar cortex, Granular insular cortex, Gustatory cortex, Hypothalamus, Inferior parietal lobule (lateral posterior cortex below the intraparietal sulcus), Inferotemporal area TE, Insula, Intermediate agranula insular cortex, Intermediate field of entorhinal cortex, Intralaminar nuclei of the thalamus, Intraparietal sulcus associated area in the superior temporal sulcus, LGN layer 2, Lateral agranular insular cortex, Lateral area 11, Lateral area 12, Lateral auditory field, Lateral auditory field, Lateral auditory parakoniocortex, Lateral intraparietal area, Lateral intraparietal area (external part), Lateral intraparietal area (internal part), Medial agranular insular cortex, Medial area 10, Medial area 11, Medial area 12, Medial area 9, Medial basal nucleus of the amygdala, Medial premotor area 6M, Middle temporal area, Midline nuclei of the thalamus, Midpart of the inferior parietal lobule, Nucleus anterior ventralis thalami, Nucleus basalis thalami, Nucleus centralis densocellularis thalami, Nucleus centralis inferior thalami, Nucleus centralis intermedialis thalami, Nucleus centralis latocellularis thalami, Nucleus centralis superior lateralis thalami, Nucleus centralis superior thalami, Nucleus limitans thalami, Nucleus medialis dorsalis thalami, Nucleus medialis dorsalis thalami, pars densocellularis, Nucleus medialis dorsalis thalami, pars fibrosa, Nucleus medialis dorsalis thalami, pars lateralis, Nucleus medialis dorsalis thalami, pars magnocellularis, Nucleus medialis dorsalis thalami, pars multiformis, Nucleus medialis dorsalis thalami, pars paramediana, Nucleus medialis dorsalis thalami, pars parvocellularis, Nucleus paracentralis thalami, Nucleus parafascicularis thalami, Nucleus parataenialis thalami, Nucleus paraventricularis thalami, pars anterior, Nucleus pulvinaris inferior thalami, Nucleus pulvinaris inferior thalami, Nucleus pulvinaris medialis thalami, Nucleus pulvinaris thalami, Nucleus reuniens thalami, Nucleus suprageniculatus thalami, Nucleus ventralis anterior thalami, pars magnocellularis, Nucleus ventralis anterior thalami, pars parvocellularis, Nucleus ventralis lateralis thalami, pars medialis, Nucleus ventralis lateralis thalami, pars postrema, Occipitoparietal area, Olfactory Complex, Orbital area 10, Orbital area 12, Orbital prefrontal cortex, Orbitofrontal area 13, Orbitofrontal area 13, lateral part, Orbitofrontal area 13, medial part, Orbitofrontal area 13a, Orbitofrontal area 14, Parahippocampal cortex, Parasubiculum, Parietal area PG, medial part, Piriform cortex, Postcentral area 3a, Postcentral area 3b, Posterior inferotemporal area, Posteromedial agranular insular cortex, Precentral opercular area, Prefrontal area 47\/12, Premotor area 6 (dorsal part), Premotor area 6Va, Premotor area 6Vb, Presubiculum, Primary auditory cortex, Primary sensory cortex, Primary somatosensory cortex, Principal Sulcus, Pro motor area, Retroinsular area, Retrosplenial area 30, Rostral area 12, Rostral area 14, Rostral field of entorhinal cortex, Rostral inferior parietal lobule, Rostral superior parietal lobule, SMA - rostral part, Secondary auditory cortex, Secondary somatosensory cortex, Subiculum, body portion, Subiculum, uncal portion, Superior temporal area 1, Superior temporal area 2, Superior temporal area 3, Superior temporal sulcus, Superior temporal sulcus, dorsal, Supratemporal cortex, granular, Temporal area TA, Temporal area TAa, Temporal

area TF, Temporal area TH, Temporal parietooccipital associated area in superior temporal sulcus, Temporal proisocortex, Temporoparietal asscociated area (caudal part), Temporoparietal associated area (rostral part), Temporoparietal cortex, Temporopolar area TG, Ventral area 10, Ventral area 46, Ventral dysgranular area of temporal polar cortex, Ventral posterior lateral nucleus (thalamus), Visual area 2, Visual area 4, Visual area V6A, accessory basal nucleus (amygdala), magnocellular subdivision, anterior lateral auditory belt, area 24, auditory prokoniocortex, caudal lateral auditory (belt), dorsal area 9, periamygdaloid cortex, posterior lateral auditory area, prosubiculum, temporal visual association area in the lower bank of the superior temporal sulcus, ventral anterior nucleus (thalamus), ventral lateral nucleus (thalamus), ventral striatal shell

Targets:

Area 23a, Area 23b, Area 23c, Area 24a, Area 24b, Area 24c (rostral part of the cingulate sulcus), Medial premotor area 6M, Nucleus caudatus; tail

Descendant targets:

Accessory basal amygdaloid nucleus, parvicellular part, Agranular frontal area 2 (= caudal dorsolateral premotor area), Agranular frontal area 4 (= caudal ventrolateral premotor area), Agranular frontal area 5 (= rostral ventrolateral premotor area), Agranular frontal area 6 (= pre-SMA), Agranular frontal area 7 (= rostral dorsolateral premotor area), Anterior inferotemporal area (dorsal), Area 10, Area 11, Area 12, Area 23, Area 23a, Area 23b, Area 23c, Area 24a, Area 24b, Area 24c (rostral part of the cingulate sulcus), Area 24d (rostral part of the cingulate sulcus), Area 25, Area 29, Area 29d, Area 31, Area 32, Area 36, Area 46 (dorsal rim of the principal sulcus), Area 46 (fundus of the principal sulcus), Area 46 (ventral rim of the principal sulcus), Area 6 (ventral part), Area 7, Area 7a, Area 7b, Area 8A, Area 8B, Area 9, Area X (thalamus), Caudal auditory parakoniocortex, Caudal inferior parietal lobule, Caudal parietal operculum, Caudomedial lobule, Central inferotemporal area, Central inferotemporal area (ventral), Cortical area 29a-c, Cortical area 45, Cortical area 46, Cortical area 9\/46d, Cortical area 9\/46v, Cortical area OAa, Cortical area PGa, Cortical area TEm, Dorsal area 10, Dorsal area 46, Dorsal portion of area 8A, Dorsal prelunate gyrus, Dysgranular insular cortex, Entorhinal cortex, Entorhinal cortex, Extrastriate area OA, Frontal eye field, Granular area of temporal polar cortex, Hypothalamus, Inferior parietal lobule (lateral posterior cortex below the intraparietal sulcus), Inferotemporal area TE, Intermediate agranula insular cortex, Intermediate field of entorhinal cortex, Intraparietal sulcus associated area in the superior temporal sulcus, LGN layer 2, Lateral area 11, Lateral area 12, Lateral area 9, Lateral auditory field, Lateral auditory field, Lateral auditory parakoniocortex, Lateral field (rostral part) of entorhinal cortex, Lateral intraparietal area, Lateral intraparietal area (external part), Lateral intraparietal area (internal part), Lateral nucleus (amygdala), dorsal division, Lateral nucleus (amygdala), dorsal intermediate division, Lateral nucleus (amygdala), ventral division, Medial area 11, Medial area 12, Medial area 9, Medial premotor area 6M, Medial superior temporal area, Medial superior temporal area (dorsal), Nucleus basalis thalami, Nucleus caudatus, Nucleus caudatus; genu, Nucleus caudatus; tail, Nucleus limitans thalami, Nucleus medialis dorsalis thalami, Nucleus medialis dorsalis thalami, pars densocellularis, Nucleus medialis dorsalis thalami, pars fibrosa, Nucleus medialis dorsalis thalami, pars magnocellularis, Nucleus medialis dorsalis thalami, pars parvocellularis, Nucleus paracentralis thalami, Nucleus pulvinaris lateralis thalami, dorsal division, Nucleus pulvinaris medialis thalami, lateral division, Nucleus pulvinaris medialis thalami, medial division, Nucleus pulvinaris thalami, Nucleus reticularis thalami, Nucleus ventralis anterior thalami, pars magnocellularis, Nucleus ventralis lateralis thalami, pars caudalis, Nucleus ventralis lateralis thalami, pars medialis, Nucleus ventralis lateralis thalami, pars oralis, Occipitoparietal area, Orbital area 10, Orbital area 12, Orbital part of area 14, Orbitofrontal area 13, Orbitofrontal area 13, lateral part, Orbitofrontal area 13, medial part, Orbitofrontal area 13a, Orbitofrontal area 14, Parahippocampal cortex, Parietal area PE (cingulate part), Parietal area PG, medial part, Posterior inferotemporal area, Posteromedial agranular insular cortex, Prefrontal area 47\/12, Premotor area 6 (dorsal part), Premotor area

6Va, Premotor area 6Vb, Presubiculum, Primary auditory cortex, Primary sensory cortex, Principal Sulcus, Pro motor area, Putamen, Putamen; caudal, Putamen; rostral, Retrosplenial area 30, Rostral area 12, Rostral area 14, Rostral field of entorhinal cortex, Rostral part of area 36, SMA - rostral part, Secondary somatosensory cortex, Subiculum, body portion, Subiculum, uncal portion, Superior temporal area 1, Superior temporal area 2, Superior temporal area 3, Superior temporal sulcus, Superior temporal sulcus, dorsal, Temporal area TAa, Temporal area TF, Temporal area TF (lateral part), Temporal area TF (medial part), Temporal area TH, Temporal parietooccipital associated area in superior temporal sulcus, Temporal proisocortex, Temporoparietal asscociated area (caudal part), Temporoparietal associated area (intermediate part), Temporoparietal associated area (rostral part), Temporoparietal cortex, Temporopolar area TG, Transitional sensory area, Ventral area 10, Ventral area 46, Visual area 4, Visual area V6A, anterior lateral auditory belt, area 24, belt line of the sensory system according to CP99, belt line of the sensorymotor system according to CP99, caudal lateral auditory (belt), dorsal area 9, lateral nucleus (amygdala), ventrolateral subdivision, orofacial representation in MI, prosubiculum, temporal visual association area in the lower bank of the superior temporal sulcus, ventral anterior nucleus (thalamus), ventral striatal shell

Sub-regions:
Area 10, Area 11, Area 12, Area 9, Cortical area 46

Region: Area 10 (10)

Super-regions:
Area 10 < Fascia dentata hippocampi < Prefrontal Cortex < Cortical area FL < GM-CerebralCortex < Brain

Sources:
Anterior inferotemporal area (ventral), Anterior medial nucleus, Area 11, Area 12, Area 23, Area 25, Area 29, Area 32, Area 35, Area 7, Area 8, Area 8B, Area 9, Central inferotemporal area (ventral), Corpus geniculatum mediale, Cortical area 46, Dorsal area 46, Dysgranular Temporopolar Cortex, Dysgranular insular cortex, Entorhinal cortex, Granular insular cortex, Gustatory cortex, Inferotemporal area TE, Lateral auditory field, Nucleus basalis thalami, Nucleus centralis latocellularis thalami, Nucleus limitans thalami, Nucleus medialis dorsalis thalami, Nucleus medialis dorsalis thalami, pars fibrosa, Nucleus paracentralis thalami, Nucleus parataenialis thalami, Nucleus pulvinaris medialis thalami, Nucleus pulvinaris thalami, Nucleus suprageniculatus thalami, Orbital area 12, Orbital prefrontal cortex, Orbitofrontal area 13, Orbitofrontal area 14, Postcentral area 3a, Principal Sulcus, Secondary auditory cortex, Superior temporal area 1, Superior temporal area 2, Superior temporal area 3, Superior temporal sulcus, Superior temporal sulcus, dorsal, Supratemporal cortex, granular, Temporopolar area TG, Ventral area 46, Visual area 2, anterior lateral auditory belt, area 24, temporal visual association area in the lower bank of the superior temporal sulcus, ventral anterior nucleus (thalamus)

Descendant sources:
Agranular area of temporal polar cortex, Area 24b, Area 24c (rostral part of the cingulate sulcus), Area 32, Area 9, Cortical area 45, Cortical area 46, Dorsal dysgranular area of temporal polar cortex, Granular area of temporal polar cortex, Intermediate agranula insular cortex, Lateral agranular insular cortex, Lateral area 11, Lateral area 12, Medial agranular insular cortex, Medial area 10, Medial area 11, Medial area 12, Orbital area 12, Orbitofrontal area 13, lateral part, Orbitofrontal area 13, medial part, Orbitofrontal area 13a, Posteromedial agranular insular cortex, Precentral opercular area, Premotor area 6Va, Rostral area 14, Temporal area TA, Ventral dysgranular area of temporal polar cortex, ventral striatal shell

Targets:
Area 11, Area 23, Area 23c, Area 24c (rostral part

of the cingulate sulcus), Area 31, Area 32, Area 6 (ventral part), Area 8A, Area 8B, Area 9, Cortical area 46, Cortical area 9\/46d, Dorsal area 46, Entorhinal cortex, Granular area of temporal polar cortex, Lateral area 12, Lateral area 9, Lateral auditory field, Lateral nucleus (amygdala), dorsal division, Lateral nucleus (amygdala), dorsal intermediate division, Lateral nucleus (amygdala), ventral division, Medial area 9, Nucleus caudatus, Nucleus medialis dorsalis thalami, Nucleus medialis dorsalis thalami, pars magnocellularis, Nucleus medialis dorsalis thalami, pars parvocellularis, Orbital area 12, Orbital part of area 14, Orbitofrontal area 14, Prefrontal area 47\/12, Primary auditory cortex, Principal Sulcus, Putamen; rostral, Rostral part of area 36, Superior temporal area 1, Superior temporal area 2, Superior temporal sulcus, Superior temporal sulcus, dorsal, Temporal area TF (lateral part), Temporal area TF (medial part), Temporal area TH, Temporopolar area TG, anterior lateral auditory belt, area 24, dorsal area 9, lateral nucleus (amygdala), ventrolateral subdivision

Descendant targets:
Area 11, Area 24a, Area 24b, Area 32, Area 8A, Intermediate agranula insular cortex, Lateral area 11, Lateral area 12, Medial area 11, Medial area 12, Nucleus caudatus, Orbital area 10, Orbital area 12, Orbitofrontal area 13, lateral part, Orbitofrontal area 13, medial part, Orbitofrontal area 13a, Primary sensory cortex, Putamen; rostral, Rostral area 12, Rostral area 14

Sub-regions:
Dorsal area 10, Medial area 10, Orbital area 10, Ventral area 10

Region: Medial area 10 (10m)

Super-regions:
Medial area 10 < Area 10 < Fascia dentata hippocampi < Prefrontal Cortex < Cortical area FL < GM-CerebralCortex < Brain

Sources:
Intermediate agranula insular cortex, Medial agranular insular cortex, Orbitofrontal area 13a, Rostral area 14

Targets:
Area 11, Area 32, Intermediate agranula insular cortex, Lateral area 11, Lateral area 12, Medial area 11, Medial area 12, Nucleus caudatus, Orbital area 10, Orbital area 12, Orbitofrontal area 13, lateral part, Orbitofrontal area 13, medial part, Orbitofrontal area 13a, Primary sensory cortex, Putamen; rostral, Rostral area 12, Rostral area 14

Region: Ventral area 10 (10v)

Super-regions:
Ventral area 10 < Area 10 < Fascia dentata hippocampi < Prefrontal Cortex < Cortical area FL < GM-CerebralCortex < Brain

Sources:
Area 32, Cortical area 46, Orbital area 12

Targets:
Area 11, Area 32, Area 8A, Lateral area 12

Region: Dorsal area 10 (10d)

Super-regions:
Dorsal area 10 < Area 10 < Fascia dentata hippocampi < Prefrontal Cortex < Cortical area FL < GM-CerebralCortex < Brain

Sources:
Area 32, Cortical area 46

Targets:
Area 32

Region: Orbital area 10 (10o)

Super-regions:
Orbital area 10 < Area 10 < Fascia dentata hippocampi < Prefrontal Cortex < Cortical area FL < GM-CerebralCortex < Brain

Sources:
Agranular area of temporal polar cortex, Area 24b, Area 24c (rostral part of the cingulate sulcus), Area 32, Area 9, Cortical area 45, Cortical area 46, Dorsal dysgranular area of temporal polar cortex, Granular area of temporal polar cortex, Intermediate agranula insular cortex, Lateral agranular insular cortex, Lateral area 11, Lateral area 12, Medial agranular insular cortex, Medial area 10, Medial area 11, Medial area 12, Orbital area 12, Orbitofrontal area 13, lateral part, Orbitofrontal area 13, medial part, Orbitofrontal area 13a, Posteromedial agranular insular cortex, Precentral opercular area, Premotor area 6Va, Rostral area 14, Temporal area TA, Ventral dysgranular area of temporal polar cortex, ventral striatal shell

Targets:
Area 11, Area 24a, Area 24b, Area 32, Intermediate agranula insular cortex, Lateral area 11, Lateral area 12, Medial area 11, Medial area 12, Nucleus caudatus, Orbital area 12, Orbitofrontal area 13, lateral part, Orbitofrontal area 13a, Primary sensory cortex, Putamen; rostral, Rostral area 14

Region: Area 12 (12)

Super-regions:
Area 12 < Fascia dentata hippocampi < Prefrontal Cortex < Cortical area FL < GM-CerebralCortex < Brain

Sources:
Accessory basal amygdaloid nucleus, parvicellular part, Agranular frontal area 7 (= rostral dorsolateral premotor area), Anterior medial nucleus, Area 24a, Area 24b, Area 24c (rostral part of the cingulate sulcus), Area 6 (ventral part), Area 7b, Basal amygdaloid nucleus, intermediate part, Central inferotemporal area (ventral), Centrum medianum thalami, Cortical area 29a-c, Hypothalamus, Inferotemporal area TE, Lateral auditory field, Lateral intraparietal area, Medial premotor area 6M, Nucleus basalis thalami, Nucleus centralis densocellularis thalami, Nucleus limitans thalami, Nucleus medialis dorsalis thalami, Nucleus medialis dorsalis thalami, pars fibrosa, Nucleus medialis dorsalis thalami, pars lateralis, Nucleus medialis dorsalis thalami, pars magnocellularis, Nucleus medialis dorsalis thalami, pars multiformis, Nucleus medialis dorsalis thalami, pars parvocellularis, Nucleus paracentralis thalami, Nucleus parafascicularis thalami, Nucleus pulvinaris medialis thalami, Presubiculum, Primary sensory cortex, Principal Sulcus, Secondary auditory cortex, Superior temporal area 3, Superior temporal sulcus, Superior temporal sulcus, dorsal, Supratemporal cortex, granular, Temporopolar area TG, accessory basal nucleus (amygdala), magnocellular subdivision, area 24, ventral anterior nucleus (thalamus), ventral striatal shell

Descendant sources:
Accessor basal nucleus (amygdala), ventromedial division, Accessory basal amygdaloid nucleus,

parvicellular part, Agranular area of temporal polar cortex, Agranular frontal area 5 (= rostral ventrolateral premotor area), Agranular frontal area 7 (= rostral dorsolateral premotor area), Agranular insula, Anterior inferotemporal area (ventral), Anterior intraparietal area, Anterior medial nucleus, Anterior nuclei of the thalamus, Area 10, Area 11, Area 23, Area 24a, Area 24b, Area 24c (rostral part of the cingulate sulcus), Area 25, Area 32, Area 35, Area 36, Area 46 (ventral rim of the principal sulcus), Area 6, Area 7a, Area 7b, Area 8, Area 8B, Area 9, Area X (thalamus), Basal amygdaloid nucleus, intermediate part, Basolateral nucleus of amygdala, Caudal inferior parietal lobule, Central amygdaloid nucleus, lateral part, Central inferotemporal area (dorsal), Central inferotemporal area (ventral), Centrum medianum thalami, Cortical area 44, Cortical area 45, Cortical area 45A, Cortical area 45B, Cortical area 46, Cortical area 9\/46v, Cortical area PGa, Cortical area TEm, Dorsal area 46, Dorsal dysgranular area of temporal polar cortex, Dysgranular insular cortex, Granular area of temporal polar cortex, Granular insular cortex, Gustatory cortex, Inferotemporal area TE, Intermediate agranula insular cortex, Intralaminar nuclei of the thalamus, Intraparietal sulcus associated area in the superior temporal sulcus, Lateral agranular insular cortex, Lateral area 11, Lateral area 12, Lateral auditory field, Lateral auditory parakoniocortex, Lateral intraparietal area (external part), Lateral intraparietal area (internal part), Medial agranular insular cortex, Medial area 10, Medial area 11, Medial area 12, Medial basal nucleus of the amygdala, Medial premotor area 6M, Midline nuclei of the thalamus, Nucleus basalis thalami, Nucleus centralis densocellularis thalami, Nucleus centralis inferior thalami, Nucleus centralis intermedialis thalami, Nucleus centralis latocellularis thalami, Nucleus limitans thalami, Nucleus medialis dorsalis thalami, Nucleus medialis dorsalis thalami, pars densocellularis, Nucleus medialis dorsalis thalami, pars fibrosa, Nucleus medialis dorsalis thalami, pars magnocellularis, Nucleus medialis dorsalis thalami, pars multiformis, Nucleus medialis dorsalis thalami, pars paramediana, Nucleus medialis dorsalis thalami, pars parvocellularis, Nucleus paracentralis thalami, Nucleus parafascicularis thalami, Nucleus paraventricularis thalami, pars anterior, Nucleus pulvinaris inferior thalami, Nucleus pulvinaris medialis thalami, Nucleus pulvinaris thalami, Nucleus reuniens thalami, Nucleus suprageniculatus thalami, Nucleus ventralis anterior thalami, pars magnocellularis, Olfactory Complex, Orbital area 10, Orbital area 12, Orbital prefrontal cortex, Orbitofrontal area 13, Orbitofrontal area 13, lateral part, Orbitofrontal area 13, medial part, Orbitofrontal area 13a, Orbitofrontal area 14, Piriform cortex, Postcentral area 3b, Posterior inferotemporal area, Posteromedial agranular insular cortex, Precentral opercular area, Premotor area 6 (dorsal part), Premotor area 6Va, Premotor area 6Vb, Primary auditory cortex, Primary somatosensory cortex, Rostral area 12, Rostral area 14, Rostral inferior parietal lobule, Secondary somatosensory cortex, Superior temporal area 1, Superior temporal area 2, Superior temporal area 3, Temporal area TA, Temporal area TF, Temporal area TH, Temporal parietooccipital associated area in superior temporal sulcus, Temporal proisocortex, Ventral area 10, Ventral area 46, Ventral dysgranular area of temporal polar cortex, accessory basal nucleus (amygdala), magnocellular subdivision, anterior lateral auditory belt, area 24, auditory prokoniocortex, temporal visual association area in the lower bank of the superior temporal sulcus, ventral anterior nucleus (thalamus), ventral lateral nucleus (thalamus)

Targets:

Agranular frontal area 7 (= rostral dorsolateral premotor area), Anterior inferotemporal area (dorsal), Area 10, Area 11, Area 23c, Area 24a, Area 24b, Area 24c (rostral part of the cingulate sulcus), Area 32, Area 36, Area 6 (ventral part), Area 7a, Area 7b, Area 8A, Central inferotemporal area (ventral), Entorhinal cortex, Entorhinal cortex, Inferotemporal area TE, Lateral intraparietal area, Lateral nucleus (amygdala), dorsal division, Lateral nucleus

(amygdala), dorsal intermediate division, Lateral nucleus (amygdala), ventral division, Medial area 9, Medial premotor area 6M, Nucleus caudatus, Nucleus medialis dorsalis thalami, Nucleus medialis dorsalis thalami, pars magnocellularis, Orbitofrontal area 14, Posterior inferotemporal area, Principal Sulcus, Pro motor area, Putamen, Putamen; caudal, Putamen; rostral, Rostral part of area 36, Superior temporal sulcus, Superior temporal sulcus, dorsal, Temporal area TF (lateral part), Temporal area TF (medial part), Temporal area TH, Temporopolar area TG, Ventral area 46, area 24, belt line of the sensory system according to CP99, belt line of the sensorymotor system according to CP99, dorsal area 9, lateral nucleus (amygdala), ventrolateral subdivision, orofacial representation in MI

Descendant targets:
Accessory basal amygdaloid nucleus, parvicellular part, Area 10, Area 11, Area 23c, Area 24c (rostral part of the cingulate sulcus), Area 25, Area 32, Area 6 (ventral part), Area 8A, Area 8B, Area 9, Caudal auditory parakoniocortex, Cortical area 46, Cortical area 9\/46d, Cortical area 9\/46v, Dorsal portion of area 8A, Hypothalamus, Intermediate agranula insular cortex, Lateral area 11, Lateral area 12, Lateral auditory field, Lateral auditory field, Medial area 11, Medial area 12, Medial area 9, Medial premotor area 6M, Nucleus caudatus, Nucleus caudatus; tail, Nucleus pulvinaris thalami, Nucleus reticularis thalami, Nucleus ventralis anterior thalami, pars magnocellularis, Nucleus ventralis lateralis thalami, pars oralis, Orbital area 10, Orbital area 12, Orbital part of area 14, Orbitofrontal area 13, Orbitofrontal area 13, lateral part, Orbitofrontal area 13, medial part, Orbitofrontal area 13a, Orbitofrontal area 14, Posteromedial agranular insular cortex, Primary auditory cortex, Primary sensory cortex, Putamen; rostral, Rostral area 12, Rostral area 14, Superior temporal area 1, Superior temporal area 2, Temporal proisocortex, Ventral area 10, Ventral area 46, anterior lateral auditory belt, area 24, dorsal area 9, ventral anterior nucleus (thalamus)

Sub-regions:
Lateral area 12, Medial area 12, Orbital area 12, Prefrontal area 47\/12, Rostral area 12

Region: Orbital area 12 (12o)

Super-regions:
Orbital area 12 < Area 12 < Fascia dentata hippocampi < Prefrontal Cortex < Cortical area FL < GM-CerebralCortex < Brain

Sources:
Accessor basal nucleus (amygdala), ventromedial division, Accessory basal amygdaloid nucleus, parvicellular part, Agranular area of temporal polar cortex, Agranular frontal area 7 (= rostral dorsolateral premotor area), Agranular insula, Anterior inferotemporal area (ventral), Anterior medial nucleus, Anterior nuclei of the thalamus, Area 10, Area 23, Area 24b, Area 24c (rostral part of the cingulate sulcus), Area 25, Area 32, Area 35, Area 36, Area 7b, Area 8, Area 9, Area X (thalamus), Basal amygdaloid nucleus, intermediate part, Basolateral nucleus of amygdala, Caudal inferior parietal lobule, Central inferotemporal area (ventral), Cortical area 45, Cortical area 46, Cortical area PGa, Cortical area TEm, Dorsal dysgranular area of temporal polar cortex, Dysgranular insular cortex, Granular area of temporal polar cortex, Granular insular cortex, Gustatory cortex, Inferotemporal area TE, Intermediate agranula insular cortex, Intralaminar nuclei of the thalamus, Intraparietal sulcus associated area in the superior temporal sulcus, Lateral agranular insular cortex, Lateral area 11, Lateral area 12, Lateral auditory field, Medial agranular insular cortex, Medial area 10, Medial area 11, Medial area 12, Medial basal nucleus of the amygdala, Medial premotor area 6M, Midline

nuclei of the thalamus, Nucleus basalis thalami, Nucleus centralis densocellularis thalami, Nucleus centralis inferior thalami, Nucleus centralis intermedialis thalami, Nucleus centralis latocellularis thalami, Nucleus medialis dorsalis thalami, Nucleus medialis dorsalis thalami, pars densocellularis, Nucleus medialis dorsalis thalami, pars fibrosa, Nucleus medialis dorsalis thalami, pars magnocellularis, Nucleus medialis dorsalis thalami, pars paramediana, Nucleus medialis dorsalis thalami, pars parvocellularis, Nucleus paracentralis thalami, Nucleus parafascicularis thalami, Nucleus paraventricularis thalami, pars anterior, Nucleus pulvinaris inferior thalami, Nucleus pulvinaris medialis thalami, Nucleus pulvinaris thalami, Nucleus reuniens thalami, Nucleus suprageniculatus thalami, Nucleus ventralis anterior thalami, pars magnocellularis, Orbital area 10, Orbital prefrontal cortex, Orbitofrontal area 13, Orbitofrontal area 13, lateral part, Orbitofrontal area 13, medial part, Orbitofrontal area 13a, Piriform cortex, Posteromedial agranular insular cortex, Precentral opercular area, Premotor area 6 (dorsal part), Premotor area 6Va, Premotor area 6Vb, Primary auditory cortex, Primary somatosensory cortex, Rostral area 12, Rostral area 14, Rostral inferior parietal lobule, Secondary somatosensory cortex, Temporal area TA, Temporal area TF, Temporal area TH, Temporal parietooccipital associated area in superior temporal sulcus, Temporal proisocortex, Ventral area 46, Ventral dysgranular area of temporal polar cortex, accessory basal nucleus (amygdala), magnocellular subdivision, anterior lateral auditory belt, area 24, temporal visual association area in the lower bank of the superior temporal sulcus, ventral anterior nucleus (thalamus), ventral lateral nucleus (thalamus)

Targets:
Area 10, Area 11, Area 23c, Area 24c (rostral part of the cingulate sulcus), Area 25, Area 32, Area 6 (ventral part), Intermediate agranula insular cortex, Lateral area 11, Lateral area 12, Lateral auditory field, Medial area 11, Medial area 12, Medial area 9, Medial premotor area 6M, Nucleus caudatus, Nucleus ventralis anterior thalami, pars magnocellularis, Nucleus ventralis lateralis thalami, pars oralis, Orbital area 10, Orbital part of area 14, Orbitofrontal area 13, Orbitofrontal area 13, lateral part, Orbitofrontal area 13, medial part, Orbitofrontal area 13a, Orbitofrontal area 14, Posteromedial agranular insular cortex, Primary sensory cortex, Putamen; rostral, Rostral area 12, Rostral area 14, Temporal proisocortex, Ventral area 10, Ventral area 46, anterior lateral auditory belt, area 24, dorsal area 9

Region: Medial area 12 (12m)

Super-regions:
Medial area 12 < Area 12 < Fascia dentata hippocampi < Prefrontal Cortex < Cortical area FL < GM-CerebralCortex < Brain

Sources:
Anterior intraparietal area, Area 24a, Area 24b, Area 24c (rostral part of the cingulate sulcus), Area 46 (ventral rim of the principal sulcus), Area 7a, Area 7b, Area 8, Cortical area 45, Cortical area 46, Dorsal dysgranular area of temporal polar cortex, Granular area of temporal polar cortex, Granular insular cortex, Gustatory cortex, Inferotemporal area TE, Intermediate agranula insular cortex, Lateral agranular insular cortex, Lateral area 11, Lateral area 12, Medial agranular insular cortex, Medial area 10, Olfactory Complex, Orbital area 10, Orbital area 12, Orbitofrontal area 13, lateral part, Orbitofrontal area 13, medial part, Orbitofrontal area 13a, Postcentral area 3b, Posteromedial agranular insular cortex, Precentral opercular

area, Premotor area 6 (dorsal part), Premotor area 6Va, Premotor area 6Vb, Primary somatosensory cortex, Rostral area 12, Secondary somatosensory cortex, Temporal area TA

Targets:
Area 11, Lateral area 11, Lateral area 12, Nucleus caudatus, Nucleus caudatus; tail, Nucleus reticularis thalami, Orbital area 10, Orbital area 12, Orbitofrontal area 13, lateral part, Orbitofrontal area 13, medial part, Orbitofrontal area 13a, Posteromedial agranular insular cortex, Primary sensory cortex, Putamen; rostral, Rostral area 12, Rostral area 14, ventral anterior nucleus (thalamus)

Region: Prefrontal area 47\/12 (47/12)

Super-regions:
Prefrontal area 47\/12 < Area 12 < Fascia dentata hippocampi < Prefrontal Cortex < Cortical area FL < GM-CerebralCortex < Brain

Sources:
Agranular frontal area 5 (= rostral ventrolateral premotor area), Anterior inferotemporal area (ventral), Area 10, Area 11, Area 32, Area 36, Area 6, Area 9, Central inferotemporal area (ventral), Cortical area 44, Cortical area 45A, Cortical area 45B, Cortical area 46, Cortical area 9\/46v, Orbitofrontal area 13, area 24, temporal visual association area in the lower bank of the superior temporal sulcus

Targets:
Area 8A, Area 8B, Area 9, Cortical area 46, Cortical area 9\/46d, Cortical area 9\/46v, Dorsal portion of area 8A

Region: Rostral area 12 (12r)

Super-regions:
Rostral area 12 < Area 12 < Fascia dentata hippocampi < Prefrontal Cortex < Cortical area FL < GM-CerebralCortex < Brain

Sources:
Agranular frontal area 7 (= rostral dorsolateral premotor area), Area 24b, Area 24c (rostral part of the cingulate sulcus), Area 8, Area 9, Cortical area 45, Cortical area 46, Inferotemporal area TE, Lateral agranular insular cortex, Lateral area 11, Lateral area 12, Medial agranular insular cortex, Medial area 10, Medial area 11, Medial area 12, Orbital area 12, Orbitofrontal area 13, lateral part, Orbitofrontal area 13, medial part, Orbitofrontal area 13a, Precentral opercular area, Premotor area 6 (dorsal part), Premotor area 6Va, Premotor area 6Vb, Primary somatosensory cortex, Rostral area 14, Temporal area TA

Targets:
Area 11, Lateral area 11, Lateral area 12, Medial area 12, Nucleus caudatus, Orbital area 12, Orbitofrontal area 13, lateral part, Orbitofrontal area 13, medial part, Orbitofrontal area 13a, Primary sensory cortex, Putamen; rostral, Rostral area 14

Region: Lateral area 12 (12l)

Super-regions:
Lateral area 12 < Area 12 < Fascia dentata hippocampi < Prefrontal Cortex < Cortical area FL < GM-CerebralCortex < Brain

Sources:

Agranular frontal area 7 (= rostral dorsolateral premotor area), Anterior inferotemporal area (ventral), Anterior medial nucleus, Anterior nuclei of the thalamus, Area 10, Area 11, Area 23, Area 24a, Area 24b, Area 24c (rostral part of the cingulate sulcus), Area 32, Area 36, Area 8, Area 8B, Area 9, Caudal inferior parietal lobule, Central amygdaloid nucleus, lateral part, Central inferotemporal area (dorsal), Central inferotemporal area (ventral), Centrum medianum thalami, Cortical area 45, Cortical area 46, Cortical area PGa, Cortical area TEm, Dorsal area 46, Dorsal dysgranular area of temporal polar cortex, Granular area of temporal polar cortex, Inferotemporal area TE, Intermediate agranula insular cortex, Intralaminar nuclei of the thalamus, Intraparietal sulcus associated area in the superior temporal sulcus, Lateral agranular insular cortex, Lateral area 11, Lateral auditory field, Lateral auditory parakoniocortex, Lateral intraparietal area (external part), Lateral intraparietal area (internal part), Medial agranular insular cortex, Medial area 10, Medial area 11, Medial area 12, Midline nuclei of the thalamus, Nucleus basalis thalami, Nucleus centralis densocellularis thalami, Nucleus centralis inferior thalami, Nucleus centralis intermedialis thalami, Nucleus limitans thalami, Nucleus medialis dorsalis thalami, Nucleus medialis dorsalis thalami, pars densocellularis, Nucleus medialis dorsalis thalami, pars magnocellularis, Nucleus medialis dorsalis thalami, pars multiformis, Nucleus medialis dorsalis thalami, pars parvocellularis, Nucleus paracentralis thalami, Nucleus parafascicularis thalami, Nucleus pulvinaris medialis thalami, Nucleus pulvinaris thalami, Nucleus reuniens thalami, Nucleus supragenicularus thalami, Nucleus ventralis anterior thalami, pars magnocellularis, Orbital area 10, Orbital area 12, Orbital prefrontal cortex, Orbitofrontal area 13, Orbitofrontal area 13, lateral part, Orbitofrontal area 13, medial part, Orbitofrontal area 13a, Orbitofrontal area 14, Piriform cortex, Posterior inferotemporal area, Premotor area 6 (dorsal part), Premotor area 6Va, Premotor area 6Vb, Primary auditory cortex, Primary somatosensory cortex, Rostral area 12, Secondary somatosensory cortex, Superior temporal area 1, Superior temporal area 2, Superior temporal area 3, Temporal area TA, Temporal area TF, Temporal parietooccipital associated area in superior temporal sulcus, Temporal proisocortex, Ventral area 10, Ventral area 46, anterior lateral auditory belt, area 24, auditory prokoniocortex, temporal visual association area in the lower bank of the superior temporal sulcus, ventral anterior nucleus (thalamus), ventral lateral nucleus (thalamus)

Targets:

Accessory basal amygdaloid nucleus, parvicellular part, Area 24c (rostral part of the cingulate sulcus), Area 8B, Caudal auditory parakoniocortex, Hypothalamus, Intermediate agranula insular cortex, Lateral area 11, Lateral auditory field, Lateral auditory field, Medial area 12, Medial area 9, Medial premotor area 6M, Nucleus caudatus, Nucleus pulvinaris thalami, Nucleus ventralis anterior thalami, pars magnocellularis, Nucleus ventralis lateralis thalami, pars oralis, Orbital area 10, Orbital area 12, Orbitofrontal area 13, lateral part, Orbitofrontal area 13, medial part, Orbitofrontal area 13a, Orbitofrontal area 14, Primary auditory cortex, Primary sensory cortex, Putamen; rostral, Rostral area 12, Rostral area 14, Superior temporal area 1, Superior temporal area 2, Ventral area 46, anterior lateral auditory belt, dorsal area 9

Region: Area 11 (11)

Super-regions:
Area 11 < Fascia dentata hippocampi < Prefrontal Cortex < Cortical area FL < GM-CerebralCortex < Brain

Sources:
Amygdala, Anterior inferotemporal area (ventral), Anterior medial nucleus, Anterior nuclei of the thalamus, Area 10, Area 12, Area 23, Area 23a, Area 23b, Area 24a, Area 24b, Area 25, Area 29d, Area 32, Area 7b, Area 8B, Area 9, Basolateral nucleus of amygdala, CA1 subfield of Ammon`s horn, Caudal inferior parietal lobule, Central inferotemporal area (ventral), Cortical area 29a-c, Cortical area 45, Cortical area 46, Cortical area PGa, Dorsal area 46, Dorsal dysgranular area of temporal polar cortex, Dysgranular insular cortex, Granular area of temporal polar cortex, Granular insular cortex, Inferotemporal area TE, Intermediate agranula insular cortex, Intralaminar nuclei of the thalamus, Intraparietal sulcus associated area in the superior temporal sulcus, Lateral agranular insular cortex, Lateral auditory field, Lateral intraparietal area, Medial agranular insular cortex, Medial area 10, Medial area 12, Medial basal nucleus of the amygdala, Midline nuclei of the thalamus, Nucleus basalis thalami, Nucleus centralis densocellularis thalami, Nucleus centralis inferior thalami, Nucleus centralis latocellularis thalami, Nucleus centralis superior lateralis thalami, Nucleus centralis superior thalami, Nucleus limitans thalami, Nucleus medialis dorsalis thalami, Nucleus medialis dorsalis thalami, pars densocellularis, Nucleus medialis dorsalis thalami, pars fibrosa, Nucleus medialis dorsalis thalami, pars magnocellularis, Nucleus medialis dorsalis thalami, pars multiformis, Nucleus medialis dorsalis thalami, pars parvocellularis, Nucleus paracentralis thalami, Nucleus parafascicularis thalami, Nucleus paraventricularis thalami, pars anterior, Nucleus pulvinaris medialis thalami, Nucleus pulvinaris thalami, Nucleus reuniens thalami, Nucleus ventralis anterior thalami, pars magnocellularis, Orbital area 10, Orbital area 12, Orbital prefrontal cortex, Orbitofrontal area 13, Orbitofrontal area 13, medial part, Orbitofrontal area 13a, Orbitofrontal area 14, Presubiculum, Primary somatosensory cortex, Principal Sulcus, Rostral area 12, Secondary somatosensory cortex, Superior temporal area 1, Superior temporal sulcus, Temporal parietooccipital associated area in superior temporal sulcus, Temporal proisocortex, Temporopolar area TG, Ventral area 10, Ventral area 46, anterior lateral auditory belt, area 24, periamygdaloid cortex, posterior lateral auditory area, prosubiculum, temporal visual association area in the lower bank of the superior temporal sulcus, ventral anterior nucleus (thalamus), ventral lateral nucleus (thalamus), ventral striatal shell

Descendant sources:
Anterior medial nucleus, Area 23a, Area 23b, Area 24a, Area 24b, Area 25, Area 29d, Area 32, Area 35, Area 9, Basal amygdaloid nucleus, intermediate part, CA3 subfield of Ammons horn, Caudal limiting field of entorhinal cortex, Cortical area 29a-c, Cortical area 45, Cortical area 46, Entorhinal cortex, Entorhinal cortex, Granular area of temporal polar cortex, Intermediate agranula insular cortex, Intermediate field of entorhinal cortex, Lateral agranular insular cortex, Lateral area 11, Lateral area 12, Lateral auditory field, Medial agranular insular cortex, Medial area 10, Medial area 11, Medial area 12, Orbital area 10, Orbital area 12, Orbitofrontal area 13, lateral part, Orbitofrontal area 13, medial part, Orbitofrontal area 13a, Precentral opercular area, Premotor area 6Va, Premotor area 6Vb, Retrosplenial area 30, Rostral area 12, Rostral area 14, Rostral field of entorhinal cortex, Subiculum, body portion, Subiculum, uncal portion, Temporal area TA, Temporal area TF, Temporal area TH, accessory basal nucleus (amygdala), magnocellular subdivision, prosubiculum

Targets:
Area 10, Area 23, Area 23c, Area 24c (rostral part of the cingulate sulcus), Area 25, Area 31, Area 32, Area 36, Area 7b, Area 9, Cortical area 46, Cortical area 9\/46d, Cortical area 9\/46v,

Entorhinal cortex, Lateral area 12, Lateral auditory field, Lateral intraparietal area, Lateral nucleus (amygdala), dorsal division, Lateral nucleus (amygdala), dorsal intermediate division, Medial area 9, Nucleus caudatus, Nucleus medialis dorsalis thalami, Nucleus medialis dorsalis thalami, pars fibrosa, Orbitofrontal area 14, Prefrontal area 47\/12, Principal Sulcus, Putamen; rostral, Rostral part of area 36, Superior temporal sulcus, Superior temporal sulcus, dorsal, Temporal area TF (lateral part), Temporal area TF (medial part), Temporal area TH, Temporopolar area TG, anterior lateral auditory belt, area 24, lateral nucleus (amygdala), ventrolateral subdivision

Descendant targets:
Area 24a, Area 24b, Area 32, Area 36, Granular area of temporal polar cortex, Intermediate agranula insular cortex, Intermediate field of entorhinal cortex, Lateral area 11, Lateral area 12, Lateral field (rostral part) of entorhinal cortex, Medial area 11, Medial area 12, Nucleus basalis thalami, Nucleus caudatus, Orbital area 10, Orbital area 12, Orbitofrontal area 13, lateral part, Orbitofrontal area 13, medial part, Orbitofrontal area 13a, Posteromedial agranular insular cortex, Primary sensory cortex, Putamen, Putamen; rostral, Rostral area 12, Rostral area 14, Rostral field of entorhinal cortex, Subiculum, body portion, Subiculum, uncal portion, prosubiculum, ventral striatal shell

Sub-regions:
Lateral area 11, Medial area 11

Region: Lateral area 11 (11l)

Super-regions:
Lateral area 11 < Area 11 < Fascia dentata hippocampi < Prefrontal Cortex < Cortical area FL < GM-CerebralCortex < Brain

Sources:
Area 24b, Area 25, Area 32, Area 35, Cortical area 45, Cortical area 46, Granular area of temporal polar cortex, Intermediate agranula insular cortex, Lateral agranular insular cortex, Lateral area 12, Medial agranular insular cortex, Medial area 10, Medial area 11, Medial area 12, Orbital area 10, Orbital area 12, Orbitofrontal area 13, lateral part, Orbitofrontal area 13, medial part, Orbitofrontal area 13a, Precentral opercular area, Premotor area 6Va, Premotor area 6Vb, Rostral area 12, Rostral area 14

Targets:
Lateral area 12, Medial area 11, Medial area 12, Nucleus caudatus, Orbital area 10, Orbital area 12, Orbitofrontal area 13, lateral part, Orbitofrontal area 13, medial part, Orbitofrontal area 13a, Posteromedial agranular insular cortex, Primary sensory cortex, Putamen, Putamen; rostral, Rostral area 12, Rostral area 14

Region: Medial area 11 (11m)

Super-regions:
Medial area 11 < Area 11 < Fascia dentata hippocampi < Prefrontal Cortex < Cortical area FL < GM-CerebralCortex < Brain

Sources:
Anterior medial nucleus, Area 23a, Area 23b, Area 24a, Area 24b, Area 25, Area 29d, Area 32, Area 9, Basal amygdaloid nucleus, intermediate part, CA3 subfield of Ammons horn, Caudal limiting field of entorhinal cortex, Cortical area 29a-c, Cortical area 46, Entorhinal cortex, Entorhinal cortex, Granular area of temporal polar cortex, Intermediate agranula insular cortex, Intermediate field of entorhinal cortex, Lateral area 11, Lateral auditory field, Medial agranular insular cortex,

Medial area 10, Orbital area 10, Orbital area 12, Orbitofrontal area 13, medial part, Orbitofrontal area 13a, Retrosplenial area 30, Rostral area 14, Rostral field of entorhinal cortex, Subiculum, body portion, Subiculum, uncal portion, Temporal area TA, Temporal area TF, Temporal area TH, accessory basal nucleus (amygdala), magnocellular subdivision, prosubiculum

Targets:
Area 24a, Area 24b, Area 32, Area 36, Granular area of temporal polar cortex, Intermediate agranula insular cortex, Intermediate field of entorhinal cortex, Lateral area 11, Lateral area 12, Lateral field (rostral part) of entorhinal cortex, Nucleus basalis thalami, Nucleus caudatus, Orbital area 10, Orbital area 12, Orbitofrontal area 13, lateral part, Orbitofrontal area 13, medial part, Orbitofrontal area 13a, Primary sensory cortex, Putamen; rostral, Rostral area 12, Rostral area 14, Rostral field of entorhinal cortex, Subiculum, body portion, Subiculum, uncal portion, prosubiculum, ventral striatal shell

---
Region: Area 9 (9)

Super-regions:
Area 9 < Fascia dentata hippocampi < Prefrontal Cortex < Cortical area FL < GM-CerebralCortex < Brain

Sources:
Agranular frontal area 7 (= rostral dorsolateral premotor area), Amygdala, Area 10, Area 11, Area 23, Area 23a, Area 23b, Area 24a, Area 24b, Area 24c (rostral part of the cingulate sulcus), Area 29, Area 32, Area 7, Area 8B, Basolateral nucleus of amygdala, Cortical area 29a-c, Cortical area 46, Cortical area 9\/46d, Dorsal portion of area 8A, Inferior parietal lobule (lateral posterior cortex below the intraparietal sulcus), Inferotemporal area TE, Lateral auditory field, Medial premotor area 6M, Nucleus basalis thalami, Nucleus limitans thalami, Nucleus medialis dorsalis thalami, Nucleus medialis dorsalis thalami, pars fibrosa, Nucleus medialis dorsalis thalami, pars lateralis, Nucleus medialis dorsalis thalami, pars magnocellularis, Nucleus medialis dorsalis thalami, pars parvocellularis, Nucleus pulvinaris medialis thalami, Nucleus suprageniculatus thalami, Nucleus ventralis anterior thalami, pars magnocellularis, Nucleus ventralis anterior thalami, pars parvocellularis, Orbitofrontal area 13, Orbitofrontal area 13a, Orbitofrontal area 14, Parietal area PG, medial part, Prefrontal area 47\/12, Presubiculum, Principal Sulcus, Retrosplenial area 30, Rostral area 14, Secondary auditory cortex, Superior temporal area 1, Superior temporal area 2, Superior temporal area 3, Superior temporal sulcus, Superior temporal sulcus, dorsal, Supratemporal cortex, granular, Temporal area TAa, Temporal area TH, Temporal parietooccipital associated area in superior temporal sulcus, Temporopolar area TG, area 24, ventral anterior nucleus (thalamus)

Descendant sources:
Area 10, Area 11, Area 12, Area 23, Area 24d (rostral part of the cingulate sulcus), Area 25, Area 29, Area 31, Area 32, Area 35, Area 6 (ventral part), Area 8, Area 8B, Cortical area 45, Cortical area 46, Dorsal area 46, Dysgranular Temporopolar Cortex, Dysgranular insular cortex, Lateral area 12, Medial area 9, Medial premotor area 6M, Orbital area 12, Orbital prefrontal cortex, Orbitofrontal area 13, Orbitofrontal area 14, Piriform cortex, Premotor area 6 (dorsal part), Primary auditory cortex, Rostral superior parietal lobule, Superior temporal area 1, Superior temporal area 2, Superior temporal area 3, Temporal area TF, Temporal area TH, Ventral area 46, area 24, auditory prokoniocortex, dorsal area 9

Targets:
Agranular frontal area 7 (= rostral dorsolateral premotor area), Area 10, Area 11, Area 23, Area

23a, Area 23b, Area 23c, Area 24a, Area 24b, Area 24c (rostral part of the cingulate sulcus), Area 25, Area 29d, Area 31, Area 32, Area 8A, Area 8B, Cortical area 29a-c, Cortical area 46, Cortical area 9\/46d, Dorsal area 46, Dorsal portion of area 8A, Entorhinal cortex, Intermediate agranula insular cortex, Lateral area 12, Lateral auditory field, Lateral intraparietal area, Lateral nucleus (amygdala), dorsal division, Lateral nucleus (amygdala), dorsal intermediate division, Lateral nucleus (amygdala), ventral division, Medial area 11, Medial premotor area 6M, Nucleus caudatus, Nucleus caudatus; genu, Nucleus limitans thalami, Nucleus medialis dorsalis thalami, Nucleus medialis dorsalis thalami, pars densocellularis, Nucleus medialis dorsalis thalami, pars parvocellularis, Nucleus pulvinaris lateralis thalami, dorsal division, Nucleus pulvinaris medialis thalami, lateral division, Nucleus pulvinaris medialis thalami, medial division, Nucleus ventralis anterior thalami, pars magnocellularis, Nucleus ventralis lateralis thalami, pars medialis, Nucleus ventralis lateralis thalami, pars oralis, Orbital area 10, Orbital area 12, Orbitofrontal area 13, lateral part, Orbitofrontal area 13a, Orbitofrontal area 14, Parietal area PE (cingulate part), Parietal area PG, medial part, Prefrontal area 47\/12, Presubiculum, Primary sensory cortex, Principal Sulcus, Putamen, Putamen; caudal, Putamen; rostral, Retrosplenial area 30, Rostral area 12, Rostral area 14, Rostral part of area 36, Superior temporal sulcus, Superior temporal sulcus, dorsal, Temporal area TF, Temporal area TF (lateral part), Temporal area TF (medial part), Temporal area TH, area 24, ventral anterior nucleus (thalamus)

Descendant targets:
Area 32, Area 8B, Cortical area 45, Medial area 9, Orbitofrontal area 14, Superior temporal area 2, Temporal parietooccipital associated area in superior temporal sulcus, dorsal area 9

Sub-regions:
Lateral area 9, Medial area 9, dorsal area 9

Region: Lateral area 9 (L9)

Super-regions:
Lateral area 9 < Area 9 < Fascia dentata hippocampi < Prefrontal Cortex < Cortical area FL < GM-CerebralCortex < Brain

Sources:
Area 10, Area 32, Area 8B, Cortical area 46, Ventral area 46

Targets:
Area 32, Area 8B

Region: Medial area 9 (M9)

Super-regions:
Medial area 9 < Area 9 < Fascia dentata hippocampi < Prefrontal Cortex < Cortical area FL < GM-CerebralCortex < Brain

Sources:
Area 10, Area 11, Area 12, Area 23, Area 24d (rostral part of the cingulate sulcus), Area 25, Area 29, Area 31, Area 32, Area 35, Area 6 (ventral part), Area 8, Area 8B, Cortical area 45, Cortical area 46, Dorsal area 46, Dysgranular Temporopolar Cortex, Dysgranular insular cortex, Lateral area 12, Medial premotor area 6M, Orbital area 12, Orbital prefrontal cortex, Orbitofrontal area 13, Orbitofrontal area 14, Piriform cortex, Premotor area 6 (dorsal part), Rostral superior parietal lobule, Superior temporal area 1, Superior temporal area 2, Superior temporal area 3, Temporal area TF, Temporal area TH, Ventral area 46, area 24, auditory prokoniocortex, dorsal area 9

Targets:
Area 32, Area 8B, Cortical area 45, Orbitofrontal area 14, Superior temporal area 2, Temporal parietooccipital associated area in superior temporal sulcus, dorsal area 9

Region: dorsal area 9 (D9)

Super-regions:
dorsal area 9 < Area 9 < Fascia dentata hippocampi < Prefrontal Cortex < Cortical area FL < GM-CerebralCortex < Brain

Sources:
Area 10, Area 12, Area 24d (rostral part of the cingulate sulcus), Area 25, Area 32, Area 8, Area 8B, Cortical area 46, Dorsal area 46, Dysgranular Temporopolar Cortex, Lateral area 12, Medial area 9, Orbital area 12, Orbitofrontal area 13, Orbitofrontal area 14, Premotor area 6 (dorsal part), Primary auditory cortex, Superior temporal area 1, Superior temporal area 2, Superior temporal area 3, Temporal area TH, Ventral area 46, area 24

Targets:
Area 32, Medial area 9, Orbitofrontal area 14

Region: Cortical area 46 (46)

Super-regions:
Cortical area 46 < Fascia dentata hippocampi < Prefrontal Cortex < Cortical area FL < GM-CerebralCortex < Brain

Sources:
Agranular frontal area 6 (= pre-SMA), Agranular frontal area 7 (= rostral dorsolateral premotor area), Agranular insula, Anterior inferotemporal area (dorsal), Anterior nuclei of the thalamus, Area 1, Area 10, Area 11, Area 23, Area 23a, Area 23b, Area 23c, Area 24a, Area 24b, Area 24c (rostral part of the cingulate sulcus), Area 24d (rostral part of the cingulate sulcus), Area 29, Area 31, Area 32, Area 6 (ventral part), Area 7a, Area 7b, Area 8A, Area 8B, Area 9, Area X (thalamus), Basolateral nucleus of amygdala, Caudal inferior parietal lobule, Central inferotemporal area, Centrum medianum thalami, Claustrum, Cortical area 29a-c, Cortical area 45, Cortical area 45B, Dorsal portion of area 8A, Dorsal prelunate gyrus, Dysgranular insular cortex, Extrastriate area OA, Frontal eye field, Granular insular cortex, Hypothalamus, Inferior parietal lobule (lateral posterior cortex below the intraparietal sulcus), Inferotemporal area TE, Insula, LGN layer 2, Lateral auditory field, Lateral intraparietal area, Medial premotor area 6M, Middle temporal area, Midline nuclei of the thalamus, Nucleus anterior ventralis thalami, Nucleus centralis densocellularis thalami, Nucleus limitans thalami, Nucleus medialis dorsalis thalami, Nucleus medialis dorsalis thalami, pars densocellularis, Nucleus medialis dorsalis thalami, pars fibrosa, Nucleus medialis dorsalis thalami, pars lateralis, Nucleus medialis dorsalis thalami, pars magnocellularis, Nucleus medialis dorsalis thalami, pars parvocellularis, Nucleus paracentralis thalami, Nucleus parafascicularis thalami, Nucleus pulvinaris medialis thalami, Nucleus ventralis anterior thalami, pars magnocellularis, Nucleus ventralis lateralis thalami, pars medialis, Nucleus ventralis lateralis thalami, pars postrema, Occipitoparietal area, Orbitofrontal area 13a, Orbitofrontal area 14, Parasubiculum, Parietal area PG, medial part, Posterior inferotemporal area, Prefrontal area 47\/12, Presubiculum, Primary sensory cortex, Primary somatosensory cortex, Retroinsular area, Retrosplenial area 30, Rostral area 14, Rostral inferior parietal lobule, Rostral superior parietal lobule, Secondary auditory cortex, Secondary somatosensory cortex, Superior temporal area 1, Superior temporal area 2, Superior temporal area 3,

Superior temporal sulcus, Superior temporal sulcus, dorsal, Supratemporal cortex, granular, Temporal area TAa, Temporal area TF, Temporal area TH, Temporal parietooccipital associated area in superior temporal sulcus, Temporoparietal asscociated area (caudal part), Temporoparietal associated area (rostral part), Temporoparietal cortex, Ventral posterior lateral nucleus (thalamus), Visual area 4, Visual area V6A, anterior lateral auditory belt, area 24, caudal lateral auditory (belt), ventral anterior nucleus (thalamus)

Descendant sources:
Agranular frontal area 4 (= caudal ventrolateral premotor area), Agranular frontal area 5 (= rostral ventrolateral premotor area), Agranular frontal area 7 (= rostral dorsolateral premotor area), Area 10, Area 11, Area 12, Area 23, Area 24a, Area 25, Area 29, Area 31, Area 32, Area 46 (dorsal rim of the principal sulcus), Area 46 (fundus of the principal sulcus), Area 46 (ventral rim of the principal sulcus), Area 6, Area 6 (ventral part), Area 8A, Area 8B, Area 9, Area X (thalamus), Basolateral nucleus of amygdala, Caudal auditory parakoniocortex, Caudal inferior parietal lobule, Caudomedial lobule, Central amygdaloid nucleus, lateral part, Central inferotemporal area (dorsal), Central inferotemporal area (ventral), Corpus geniculatum mediale, Cortical amygdaloid nucleus, Cortical area 44, Cortical area 45, Cortical area 45A, Cortical area 45B, Cortical area PGa, Cortical area TEm, Dorsal area 46, Dorsal portion of area 8A, Dysgranular insular cortex, Extrastriate area OA, Intralaminar nuclei of the thalamus, Intraparietal sulcus associated area in the superior temporal sulcus, Lateral area 12, Lateral auditory field, Lateral auditory parakoniocortex, Lateral intraparietal area, Lateral intraparietal area (external part), Lateral intraparietal area (internal part), Medial basal nucleus of the amygdala, Middle temporal area, Midline nuclei of the thalamus, Midpart of the inferior parietal lobule, Nucleus centralis inferior thalami, Nucleus centralis superior lateralis thalami, Nucleus limitans thalami, Nucleus medialis dorsalis thalami, Nucleus medialis dorsalis thalami, pars densocellularis, Nucleus medialis dorsalis thalami, pars magnocellularis, Nucleus medialis dorsalis thalami, pars multiformis, Nucleus medialis dorsalis thalami, pars parvocellularis, Nucleus paracentralis thalami, Nucleus parafascicularis thalami, Nucleus pulvinaris inferior thalami, Nucleus pulvinaris medialis thalami, Nucleus pulvinaris thalami, Nucleus reuniens thalami, Nucleus suprageniculatus thalami, Nucleus ventralis anterior thalami, pars magnocellularis, Orbital area 12, Orbitofrontal area 13, Orbitofrontal area 14, Parahippocampal cortex, Parietal area PG, medial part, Prefrontal area 47\/12, Premotor area 6 (dorsal part), Premotor area 6Va, Premotor area 6Vb, Primary auditory cortex, Primary somatosensory cortex, Principal Sulcus, Pro motor area, Retrosplenial area 30, Rostral inferior parietal lobule, SMA - rostral part, Secondary auditory cortex, Secondary somatosensory cortex, Superior temporal area 2, Superior temporal area 3, Temporal area TAa, Temporal area TH, Temporal parietooccipital associated area in superior temporal sulcus, Temporoparietal cortex, Ventral area 46, Ventral posterior lateral nucleus (thalamus), anterior lateral auditory belt, area 24, caudal lateral auditory (belt), posterior lateral auditory area, temporal visual association area in the lower bank of the superior temporal sulcus, ventral anterior nucleus (thalamus), ventral lateral nucleus (thalamus)

Targets:
Agranular frontal area 2 (= caudal dorsolateral premotor area), Agranular frontal area 5 (= rostral ventrolateral premotor area), Agranular frontal area 6 (= pre-SMA), Agranular frontal area 7 (= rostral dorsolateral premotor area), Anterior inferotemporal area (dorsal), Area 10, Area 11, Area 23, Area 23a, Area 23b, Area 23c, Area 24a, Area 24b, Area 24c (rostral part of the cingulate sulcus), Area 24d (rostral part of the cingulate sulcus), Area 31, Area 32, Area 36, Area 6 (ventral part), Area 7a, Area 7b, Area 8A, Area 8B, Area 9, Area X (thalamus), Caudal inferior parietal lobule, Caudal parietal operculum, Central inferotemporal area, Cortical area

29a-c, Cortical area 45, Cortical area OAa, Cortical area TEm, Dorsal area 10, Dorsal portion of area 8A, Dorsal prelunate gyrus, Entorhinal cortex, Entorhinal cortex, Frontal eye field, Inferior parietal lobule (lateral posterior cortex below the intraparietal sulcus), Inferotemporal area TE, Intraparietal sulcus associated area in the superior temporal sulcus, LGN layer 2, Lateral area 11, Lateral area 12, Lateral area 9, Lateral auditory field, Lateral intraparietal area, Lateral nucleus (amygdala), dorsal division, Lateral nucleus (amygdala), dorsal intermediate division, Lateral nucleus (amygdala), ventral division, Medial area 11, Medial area 12, Medial area 9, Medial premotor area 6M, Medial superior temporal area, Medial superior temporal area (dorsal), Nucleus caudatus, Nucleus caudatus; genu, Nucleus caudatus; tail, Nucleus limitans thalami, Nucleus medialis dorsalis thalami, Nucleus medialis dorsalis thalami, pars parvocellularis, Nucleus paracentralis thalami, Nucleus pulvinaris lateralis thalami, dorsal division, Nucleus pulvinaris medialis thalami, lateral division, Nucleus pulvinaris medialis thalami, medial division, Nucleus ventralis anterior thalami, pars magnocellularis, Nucleus ventralis lateralis thalami, pars caudalis, Nucleus ventralis lateralis thalami, pars medialis, Occipitoparietal area, Orbital area 10, Orbital area 12, Orbitofrontal area 13, Orbitofrontal area 13, lateral part, Orbitofrontal area 13a, Orbitofrontal area 14, Parietal area PE (cingulate part), Parietal area PG, medial part, Posterior inferotemporal area, Prefrontal area 47\/12, Premotor area 6 (dorsal part), Primary sensory cortex, Pro motor area, Putamen; caudal, Putamen; rostral, Rostral area 12, Rostral area 14, Rostral part of area 36, Secondary somatosensory cortex, Superior temporal sulcus, Superior temporal sulcus, dorsal, Temporal area TF, Temporal area TF (lateral part), Temporal area TF (medial part), Temporal area TH, Temporoparietal asscociated area (caudal part), Temporoparietal associated area (intermediate part), Temporoparietal associated area (rostral part), Temporopolar area TG, Transitional sensory area, Ventral area 10, Visual area 4, Visual area V6A, anterior lateral auditory belt, area 24, caudal lateral auditory (belt), dorsal area 9, temporal visual association area in the lower bank of the superior temporal sulcus, ventral anterior nucleus (thalamus)

Descendant targets:
Agranular frontal area 4 (= caudal ventrolateral premotor area), Agranular frontal area 5 (= rostral ventrolateral premotor area), Agranular frontal area 6 (= pre-SMA), Agranular frontal area 7 (= rostral dorsolateral premotor area), Area 10, Area 11, Area 12, Area 23, Area 25, Area 29, Area 29d, Area 31, Area 32, Area 46 (dorsal rim of the principal sulcus), Area 46 (fundus of the principal sulcus), Area 46 (ventral rim of the principal sulcus), Area 6 (ventral part), Area 7, Area 8A, Area 8B, Area 9, Caudal auditory parakoniocortex, Caudal inferior parietal lobule, Caudomedial lobule, Cortical area 29a-c, Cortical area 45, Cortical area PGa, Dorsal area 46, Dorsal portion of area 8A, Dysgranular insular cortex, Extrastriate area OA, Inferior parietal lobule (lateral posterior cortex below the intraparietal sulcus), Lateral area 12, Lateral area 9, Lateral auditory field, Lateral auditory parakoniocortex, Lateral intraparietal area (external part), Lateral intraparietal area (internal part), Medial area 12, Medial area 9, Medial superior temporal area (dorsal), Nucleus pulvinaris thalami, Orbital area 12, Orbitofrontal area 13, Orbitofrontal area 14, Parahippocampal cortex, Parietal area PG, medial part, Prefrontal area 47\/12, Premotor area 6 (dorsal part), Premotor area 6Va, Premotor area 6Vb, Presubiculum, Primary auditory cortex, Principal Sulcus, Pro motor area, Retrosplenial area 30, SMA - rostral part, Superior temporal area 2, Superior temporal area 3, Temporal area TAa, Temporal parietooccipital associated area in superior temporal sulcus, Temporoparietal cortex, Ventral area 46, anterior lateral auditory belt, area 24, caudal lateral auditory (belt), dorsal area 9

Sub-regions:
Area 46 (dorsal rim of the principal sulcus), Area 46 (fundus of the principal sulcus), Area 46 (ventral rim

of the principal sulcus), Cortical area 9\/46, Dorsal area 46, Principal Sulcus, Ventral area 46

Region: Ventral area 46 (46v)

Super-regions:
Ventral area 46 < Cortical area 46 < Fascia dentata hippocampi < Prefrontal Cortex < Cortical area FL < GM-CerebralCortex < Brain

Sources:
Agranular frontal area 4 (= caudal ventrolateral premotor area), Agranular frontal area 5 (= rostral ventrolateral premotor area), Agranular frontal area 7 (= rostral dorsolateral premotor area), Area 12, Area 23, Area 6 (ventral part), Area 8B, Area X (thalamus), Basolateral nucleus of amygdala, Caudal inferior parietal lobule, Central amygdaloid nucleus, lateral part, Central inferotemporal area (dorsal), Central inferotemporal area (ventral), Corpus geniculatum mediale, Cortical amygdaloid nucleus, Cortical area 45, Cortical area PGa, Cortical area TEm, Dorsal area 46, Intralaminar nuclei of the thalamus, Intraparietal sulcus associated area in the superior temporal sulcus, Lateral area 12, Lateral auditory field, Lateral intraparietal area (external part), Lateral intraparietal area (internal part), Medial basal nucleus of the amygdala, Middle temporal area, Midline nuclei of the thalamus, Nucleus centralis inferior thalami, Nucleus limitans thalami, Nucleus medialis dorsalis thalami, Nucleus medialis dorsalis thalami, pars magnocellularis, Nucleus medialis dorsalis thalami, pars multiformis, Nucleus medialis dorsalis thalami, pars parvocellularis, Nucleus paracentralis thalami, Nucleus parafascicularis thalami, Nucleus pulvinaris inferior thalami, Nucleus pulvinaris medialis thalami, Nucleus pulvinaris thalami, Nucleus reuniens thalami, Nucleus suprageniculatus thalami, Nucleus ventralis anterior thalami, pars magnocellularis, Orbital area 12, Premotor area 6 (dorsal part), Premotor area 6Va, Premotor area 6Vb, Primary somatosensory cortex, Principal Sulcus, SMA - rostral part, Secondary somatosensory cortex, Temporal parietooccipital associated area in superior temporal sulcus, Temporoparietal cortex, Ventral posterior lateral nucleus (thalamus), anterior lateral auditory belt, area 24, caudal lateral auditory (belt), posterior lateral auditory area, temporal visual association area in the lower bank of the superior temporal sulcus, ventral anterior nucleus (thalamus), ventral lateral nucleus (thalamus)

Targets:
Agranular frontal area 4 (= caudal ventrolateral premotor area), Agranular frontal area 5 (= rostral ventrolateral premotor area), Agranular frontal area 6 (= pre-SMA), Area 10, Area 11, Area 32, Area 6 (ventral part), Area 7, Area 8A, Cortical area 45, Dorsal area 46, Inferior parietal lobule (lateral posterior cortex below the intraparietal sulcus), Lateral area 12, Lateral area 9, Lateral auditory field, Medial area 9, Medial superior temporal area (dorsal), Nucleus pulvinaris thalami, Orbital area 12, Orbitofrontal area 13, Orbitofrontal area 14, Premotor area 6 (dorsal part), Principal Sulcus, Pro motor area, SMA - rostral part, anterior lateral auditory belt, area 24, caudal lateral auditory (belt), dorsal area 9

Region: Dorsal area 46 (46d)

Super-regions:
Dorsal area 46 < Cortical area 46 < Fascia dentata hippocampi < Prefrontal Cortex < Cortical area FL < GM-CerebralCortex <

Brain

Sources:
Area 10, Area 32, Area 8A, Area 8B, Area 9, Caudal auditory parakoniocortex, Intralaminar nuclei of the thalamus, Lateral auditory field, Nucleus centralis superior lateralis thalami, Nucleus medialis dorsalis thalami, Nucleus medialis dorsalis thalami, pars densocellularis, Nucleus medialis dorsalis thalami, pars parvocellularis, Nucleus paracentralis thalami, Nucleus pulvinaris medialis thalami, Nucleus ventralis anterior thalami, pars magnocellularis, Premotor area 6 (dorsal part), Primary auditory cortex, Principal Sulcus, SMA - rostral part, Secondary auditory cortex, Superior temporal area 3, Temporoparietal cortex, Ventral area 46, anterior lateral auditory belt, caudal lateral auditory (belt), ventral anterior nucleus (thalamus)

Targets:
Agranular frontal area 6 (= pre-SMA), Area 10, Area 11, Area 32, Area 8A, Area 8B, Caudal auditory parakoniocortex, Lateral area 12, Lateral auditory field, Medial area 9, Orbitofrontal area 14, Primary auditory cortex, Principal Sulcus, SMA - rostral part, Superior temporal area 2, Ventral area 46, anterior lateral auditory belt, caudal lateral auditory (belt), dorsal area 9

Region: Principal Sulcus (PS)

Super-regions:
Principal Sulcus < Cortical area 46 < Fascia dentata hippocampi < Prefrontal Cortex < Cortical area FL < GM-CerebralCortex < Brain

Sources:
Agranular frontal area 7 (= rostral dorsolateral premotor area), Area 10, Area 11, Area 12, Area 23, Area 25, Area 29, Area 31, Area 46 (dorsal rim of the principal sulcus), Area 46 (fundus of the principal sulcus), Area 46 (ventral rim of the principal sulcus), Area 8A, Area 8B, Area 9, Caudal inferior parietal lobule, Caudomedial lobule, Cortical area 45, Cortical area PGa, Dorsal area 46, Dysgranular insular cortex, Extrastriate area OA, Lateral auditory parakoniocortex, Parahippocampal cortex, Parietal area PG, medial part, Premotor area 6Va, Premotor area 6Vb, Retrosplenial area 30, SMA - rostral part, Superior temporal area 3, Temporal area TAa, Temporal parietooccipital associated area in superior temporal sulcus, Temporoparietal cortex, Ventral area 46, area 24

Targets:
Agranular frontal area 7 (= rostral dorsolateral premotor area), Area 10, Area 11, Area 12, Area 23, Area 25, Area 29, Area 31, Area 46 (dorsal rim of the principal sulcus), Area 46 (fundus of the principal sulcus), Area 46 (ventral rim of the principal sulcus), Area 8A, Area 8B, Area 9, Caudal inferior parietal lobule, Caudomedial lobule, Cortical area 45, Cortical area PGa, Dorsal area 46, Dysgranular insular cortex, Extrastriate area OA, Lateral auditory parakoniocortex, Lateral intraparietal area (external part), Lateral intraparietal area (internal part), Parahippocampal cortex, Parietal area PG, medial part, Premotor area 6Va, Premotor area 6Vb, Retrosplenial area 30, SMA - rostral part, Superior temporal area 3, Temporal area TAa, Temporal parietooccipital associated area in superior temporal sulcus, Temporoparietal cortex, Ventral area 46, area 24

Region: Area 46 (fundus of the principal sulcus) (46f)

Super-regions:
Area 46 (fundus of the principal sulcus) < Cortical area 46 < Fascia dentata hippocampi < Prefrontal Cortex < Cortical area FL < GM-CerebralCortex < Brain

Sources:
Principal Sulcus

Targets:
Principal Sulcus

Region: Area 46 (ventral rim of the principal sulcus) (46vr)

Super-regions:
Area 46 (ventral rim of the principal sulcus) < Cortical area 46 < Fascia dentata hippocampi < Prefrontal Cortex < Cortical area FL < GM-CerebralCortex < Brain

Sources:
Principal Sulcus, SMA - rostral part

Targets:
Medial area 12, Principal Sulcus, SMA - rostral part

Region: Area 46 (dorsal rim of the principal sulcus) (46dr)

Super-regions:
Area 46 (dorsal rim of the principal sulcus) < Cortical area 46 < Fascia dentata hippocampi < Prefrontal Cortex < Cortical area FL < GM-CerebralCortex < Brain

Sources:
Principal Sulcus, SMA - rostral part

Targets:
Principal Sulcus, SMA - rostral part

Region: Cortical area 9\/46 (9/46)

Super-regions:
Cortical area 9\/46 < Cortical area 46 < Fascia dentata hippocampi < Prefrontal Cortex < Cortical area FL < GM-CerebralCortex < Brain

Descendant sources:
Agranular frontal area 7 (= rostral dorsolateral premotor area), Area 10, Area 11, Area 23, Area 24a, Area 29, Area 32, Area 6, Area 8B, Area 9, Caudal inferior parietal lobule, Cortical area 44, Cortical area 45A, Cortical area 45B, Dorsal portion of area 8A, Extrastriate area OA, Lateral intraparietal area, Midpart of the inferior parietal lobule, Orbitofrontal area 13, Orbitofrontal area 14, Parietal area PG, medial part, Prefrontal area 47\/12, Pro motor area, Retrosplenial area 30, Rostral inferior parietal lobule, Superior temporal area 2, Temporal area TH, Temporal parietooccipital associated area in superior temporal sulcus, area 24

Descendant targets:
Area 23, Area 29d, Area 31, Area 8B, Area 9, Cortical area 29a-c, Dorsal portion of area 8A, Prefrontal area 47\/12, Presubiculum, Retrosplenial area 30

Sub-regions:
Cortical area 9\/46d, Cortical area 9\/46v

Region: Cortical area 9\/46v (9/46v)

Super-regions:
Cortical area 9\/46v < Cortical area 9\/46 < Cortical area 46 < Fascia dentata hippocampi < Prefrontal Cortex < Cortical area FL < GM-CerebralCortex < Brain

Sources:
Area 11, Area 24a, Area 6, Cortical area 44, Cortical area 45B, Lateral intraparietal area, Midpart of the inferior parietal lobule, Orbitofrontal area 13, Prefrontal area 47\/12, Pro motor area, Rostral inferior parietal lobule

Targets:
Dorsal portion of area 8A, Prefrontal area 47\/12

Region: Cortical area 9\/46d (9/46d)

Super-regions:
Cortical area 9\/46d < Cortical area 9\/46 < Cortical area 46 < Fascia dentata hippocampi < Prefrontal Cortex < Cortical area FL < GM-CerebralCortex < Brain

Sources:
Agranular frontal area 7 (= rostral dorsolateral premotor area), Area 10, Area 11, Area 23, Area 29, Area 32, Area 8B, Area 9, Caudal inferior parietal lobule, Cortical area 45A, Dorsal portion of area 8A, Extrastriate area OA, Orbitofrontal area 13, Orbitofrontal area 14, Parietal area PG, medial part, Prefrontal area 47\/12, Retrosplenial area 30, Superior temporal area 2, Temporal area TH, Temporal parietooccipital associated area in superior temporal sulcus, area 24

Targets:
Area 23, Area 29d, Area 31, Area 8B, Area 9, Cortical area 29a-c, Dorsal portion of area 8A, Presubiculum, Retrosplenial area 30

Region: Area 8 (8)

Super-regions:
Area 8 < Prefrontal Cortex < Cortical area FL < GM-CerebralCortex < Brain

Sources:
Agranular frontal area 7 (= rostral dorsolateral premotor area), Area 7, Basolateral nucleus of amygdala, Cortical area 29a-c, Inferior parietal lobule (lateral posterior cortex below the intraparietal sulcus), Nucleus medialis dorsalis thalami, pars fibrosa, Nucleus medialis dorsalis thalami, pars magnocellularis, Nucleus pulvinaris thalami, Parasubiculum, Presubiculum, Rostral superior parietal lobule, Secondary auditory cortex, Superior temporal sulcus, Superior temporal sulcus, dorsal, Supratemporal cortex, granular, Temporopolar area TG, Visual area 2, area 24

Descendant sources:
Agranular frontal area 5 (= rostral ventrolateral premotor area), Agranular frontal area 7 (= rostral dorsolateral premotor area), Amygdala, Anterior inferotemporal area (dorsal), Anterior inferotemporal area (ventral), Area 1, Area 10, Area 12, Area 23, Area 23a, Area 23b, Area 23c, Area 24a, Area 24b, Area 31, Area 32, Area 6 (ventral part), Area 6 (ventral part), Area 7a, Area 7b, Area 8B, Area 9, Area X (thalamus), Caudal auditory parakoniocortex, Caudal inferior parietal lobule, Caudal parietal operculum, Central amygdaloid nucleus, lateral part, Central inferotemporal area, Central inferotemporal area (dorsal), Central inferotemporal area (ventral), Centrum medianum thalami, Claustrum, Corpus geniculatum

mediale, Cortical area 45, Cortical area 45A, Cortical area 45B, Cortical area 46, Cortical area 9\/46d, Cortical area 9\/46v, Cortical area PGa, Cortical area TEm, Dorsal area 46, Dorsal visual area 3, Extrastriate area OA, Floor of superior temporal sulcus, Hypothalamus, Inferotemporal area TE, Intralaminar nuclei of the thalamus, Intraparietal sulcus associated area in the superior temporal sulcus, Lateral area 12, Lateral area 9, Lateral auditory field, Lateral auditory parakoniocortex, Lateral intraparietal area, Lateral intraparietal area (external part), Lateral intraparietal area (internal part), Medial agranular insular cortex, Medial area 9, Medial intraparietal area, Medial premotor area 6M, Medial superior temporal area, Medial superior temporal area (dorsal), Medial superior temporal area (posterior), Middle temporal area, Midline nuclei of the thalamus, Motor area 4c, Nucleus centralis densocellularis thalami, Nucleus centralis inferior thalami, Nucleus centralis latocellularis thalami, Nucleus centralis superior lateralis thalami, Nucleus limitans thalami, Nucleus medialis dorsalis thalami, Nucleus medialis dorsalis thalami, pars densocellularis, Nucleus medialis dorsalis thalami, pars fibrosa, Nucleus medialis dorsalis thalami, pars lateralis, Nucleus medialis dorsalis thalami, pars multiformis, Nucleus medialis dorsalis thalami, pars parvocellularis, Nucleus paracentralis thalami, Nucleus parafascicularis thalami, Nucleus paraventricularis thalami, Nucleus pulvinaris inferior thalami, Nucleus pulvinaris medialis thalami, Nucleus pulvinaris thalami, Nucleus pulvinaris thalami, pars oralis, Nucleus subthalamicus, Nucleus suprageniculatus thalami, Nucleus ventralis anterior thalami, pars magnocellularis, Nucleus ventralis anterior thalami, pars parvocellularis, Nucleus ventralis lateralis thalami, pars medialis, Nucleus ventralis lateralis thalami, pars oralis, Occipitoparietal area, Orbitofrontal area 13, Orbitofrontal area 14, Parietal area PG, medial part, Peripheral part of area MT, Postcentral area 3a, Posterior inferotemporal area, Posterior inferotemporal area (dorsal), Prefrontal area 47\/12, Premotor area 6 (dorsal part), Primary auditory cortex, Primary sensory cortex, Principal Sulcus, Retroinsular area, Retrosplenial area 30, SMA - rostral part, Secondary auditory cortex, Superior temporal area 3, Temporal area TAa, Temporal area TF, Temporal area TH, Temporal parietooccipital associated area in superior temporal sulcus, Temporoparietal asscociated area (caudal part), Temporoparietal cortex, V4 transitional area, Ventral area 10, Ventral area 46, Ventral intraparietal area, Ventral posterior lateral nucleus (thalamus), Ventral visual area 3, Visual area 2, Visual area 3, Visual area 3A, Visual area 4, anterior lateral auditory belt, area 24, caudal lateral auditory (belt), posterior lateral auditory area, rostroventral parietal area as defined in DLRPK03, superior parietal lobule (posterior dorsomedial parietal cortex above the intraparietal sulcus), temporal visual association area in the lower bank of the superior temporal sulcus, ventral anterior nucleus (thalamus), ventral lateral nucleus (thalamus)

Targets:

Agranular frontal area 7 (= rostral dorsolateral premotor area), Anterior inferotemporal area (dorsal), Area 10, Area 23b, Area 36, Area 6 (ventral part), Claustrum, Entorhinal cortex, Inferotemporal area TE, Lateral area 12, Lateral nucleus (amygdala), dorsal intermediate division, Medial area 12, Medial area 9, Medial basal nucleus of the amygdala, Medial superior temporal area (dorsal), Nucleus basalis thalami, Nucleus caudatus, Nucleus caudatus; genu, Nucleus medialis dorsalis thalami, Nucleus medialis dorsalis thalami, pars multiformis, Nucleus paracentralis thalami, Nucleus parafascicularis thalami, Nucleus ventralis anterior thalami, pars magnocellularis, Nucleus ventralis lateralis thalami, pars oralis, Nucleus ventralis posterior lateralis thalami, pars oralis, Orbital area 12, Orbitofrontal area 14, Putamen, Putamen; caudal, Rostral area 12, Rostral part of area 36, Superior temporal sulcus, Superior temporal sulcus, dorsal, Temporal area TF (lateral part), Temporal area TF (medial part), dorsal area 9

Descendant targets:

Agranular frontal area 2 (= caudal dorsolateral premotor area), Agranular frontal area 6 (= pre-SMA), Agranular frontal area 7 (= rostral dorsolateral premotor area), Anterior inferotemporal area (dorsal), Area 10, Area 11, Area 23, Area 23a, Area 23b, Area 23c, Area 24a, Area 24b, Area 24c (rostral part of the cingulate sulcus), Area 24d (rostral part of the cingulate sulcus), Area 31, Area

32, Area 36, Area 6 (ventral part), Area 7a, Area 7b, Area 8A, Area 8B, Area 9, Caudal auditory parakoniocortex, Central amygdaloid nucleus, lateral part, Central inferotemporal area, Central inferotemporal area (ventral), Centrum medianum thalami, Claustrum, Cortical area 45, Cortical area 46, Cortical area 9\/46d, Cortical area 9\/46v, Dorsal area 46, Dorsal portion of area 8A, Dorsal prelunate gyrus, Floor of superior temporal sulcus, Inferior parietal lobule (lateral posterior cortex below the intraparietal sulcus), Inferotemporal area TE, Intermediate agranula insular cortex, Lateral area 11, Lateral area 12, Lateral area 9, Lateral auditory field, Lateral intraparietal area, Lateral nucleus (amygdala), dorsal division, Lateral nucleus (amygdala), dorsal intermediate division, Medial area 12, Medial area 9, Medial premotor area 6M, Medial superior temporal area (dorsal), Medial superior temporal area (posterior), Nucleus caudatus, Nucleus centralis superior lateralis thalami, Nucleus medialis dorsalis thalami, Nucleus medialis dorsalis thalami, pars magnocellularis, Nucleus medialis dorsalis thalami, pars multiformis, Nucleus medialis dorsalis thalami, pars parvocellularis, Nucleus parafascicularis thalami, Nucleus paraventricularis thalami, Nucleus pulvinaris medialis thalami, Nucleus pulvinaris thalami, Nucleus pulvinaris thalami, pars oralis, Nucleus reticularis thalami, Nucleus ventralis anterior thalami, pars magnocellularis, Nucleus ventralis lateralis thalami, pars caudalis, Nucleus ventralis lateralis thalami, pars oralis, Orbital area 10, Orbital area 12, Orbitofrontal area 13, lateral part, Orbitofrontal area 13a, Parietal area PE (cingulate part), Parietal area PG, medial part, Posterior inferotemporal area, Prefrontal area 47\/12, Premotor area 6 (dorsal part), Primary auditory cortex, Primary sensory cortex, Principal Sulcus, Putamen, Putamen; caudal, Putamen; rostral, Rostral area 12, Rostral area 14, Rostral part of area 36, SMA - rostral part, Superior temporal area 2, Temporal area TAa, Temporal area TF (lateral part), Temporal area TF (medial part), Temporal parietooccipital associated area in superior temporal sulcus, Temporoparietal asscociated area (caudal part), Transitional sensory area, Ventral area 46, Ventral intraparietal area, Visual area 4, anterior lateral auditory belt, area 24, caudal lateral auditory (belt), dorsal area 9, rostroventral parietal area as defined in DLRPK03, substantia nigra, ventral anterior nucleus (thalamus)

Sub-regions:
Area 8B, Frontal eye field

Region: Frontal eye field (FEF)

Super-regions:
Frontal eye field < Area 8 < Prefrontal Cortex < Cortical area FL < GM-CerebralCortex < Brain

Sources:
Anterior inferotemporal area (dorsal), Area 6 (ventral part), Area 7a, Central amygdaloid nucleus, lateral part, Central inferotemporal area, Claustrum, Cortical area 46, Floor of superior temporal sulcus, Hypothalamus, Lateral intraparietal area, Medial superior temporal area (dorsal), Medial superior temporal area (posterior), Middle temporal area, Nucleus centralis latocellularis thalami, Nucleus centralis superior lateralis thalami, Nucleus medialis dorsalis thalami, Nucleus paracentralis thalami, Nucleus pulvinaris medialis thalami, Nucleus subthalamicus, Nucleus ventralis anterior thalami, pars magnocellularis, Nucleus ventralis anterior thalami, pars parvocellularis, Parietal area PG, medial part, Posterior inferotemporal area, Primary sensory cortex, Temporoparietal asscociated area (caudal part), V4 transitional area, Ventral intraparietal area, Ventral visual area 3, Visual area 2, Visual area 3, Visual area 3A, Visual area 4, rostroventral parietal area as defined in DLRPK03, ventral anterior nucleus (thalamus)

Descendant sources:
Agranular frontal area 5 (= rostral ventrolateral premotor area), Agranular frontal area 7 (= rostral dorsolateral premotor area), Anterior inferotemporal

area (ventral), Area 1, Area 10, Area 12, Area 23, Area 23a, Area 23b, Area 23c, Area 24a, Area 24b, Area 31, Area 6 (ventral part), Area 7a, Area 7b, Area 8B, Area 9, Area X (thalamus), Caudal auditory parakoniocortex, Caudal inferior parietal lobule, Caudal parietal operculum, Central inferotemporal area (dorsal), Central inferotemporal area (ventral), Centrum medianum thalami, Corpus geniculatum mediale, Cortical area 45, Cortical area 45A, Cortical area 45B, Cortical area 46, Cortical area 9\/46d, Cortical area 9\/46v, Cortical area PGa, Cortical area TEm, Dorsal area 46, Dorsal visual area 3, Extrastriate area OA, Floor of superior temporal sulcus, Hypothalamus, Inferotemporal area TE, Intraparietal sulcus associated area in the superior temporal sulcus, Lateral auditory field, Lateral auditory parakoniocortex, Lateral intraparietal area, Lateral intraparietal area (external part), Lateral intraparietal area (internal part), Medial agranular insular cortex, Medial area 9, Medial intraparietal area, Medial premotor area 6M, Medial superior temporal area, Middle temporal area, Motor area 4c, Nucleus limitans thalami, Nucleus medialis dorsalis thalami, Nucleus medialis dorsalis thalami, pars fibrosa, Nucleus medialis dorsalis thalami, pars lateralis, Nucleus medialis dorsalis thalami, pars multiformis, Nucleus medialis dorsalis thalami, pars parvocellularis, Nucleus parafascicularis thalami, Nucleus paraventricularis thalami, Nucleus pulvinaris inferior thalami, Nucleus pulvinaris medialis thalami, Nucleus pulvinaris thalami, Nucleus pulvinaris thalami, pars oralis, Nucleus suprageniculatus thalami, Nucleus ventralis anterior thalami, pars magnocellularis, Nucleus ventralis anterior thalami, pars parvocellularis, Nucleus ventralis lateralis thalami, pars medialis, Nucleus ventralis lateralis thalami, pars oralis, Occipitoparietal area, Parietal area PG, medial part, Peripheral part of area MT, Postcentral area 3a, Posterior inferotemporal area, Posterior inferotemporal area (dorsal), Prefrontal area 47\/12, Premotor area 6 (dorsal part), Primary auditory cortex, Primary sensory cortex, Principal Sulcus, Retroinsular area, SMA - rostral part, Superior temporal area 3, Temporal area TAa, Temporal parietooccipital associated area in superior temporal sulcus, Temporoparietal cortex, V4 transitional area, Ventral area 10, Ventral area 46, Ventral intraparietal area, Ventral posterior lateral nucleus (thalamus), Ventral visual area 3, Visual area 2, Visual area 3, Visual area 3A, Visual area 4, anterior lateral auditory belt, area 24, caudal lateral auditory (belt), posterior lateral auditory area, superior parietal lobule (posterior dorsomedial parietal cortex above the intraparietal sulcus), temporal visual association area in the lower bank of the superior temporal sulcus

Targets:

Agranular frontal area 7 (= rostral dorsolateral premotor area), Anterior inferotemporal area (dorsal), Area 7a, Central amygdaloid nucleus, lateral part, Central inferotemporal area, Centrum medianum thalami, Claustrum, Cortical area 46, Dorsal prelunate gyrus, Floor of superior temporal sulcus, Lateral intraparietal area, Medial superior temporal area (dorsal), Medial superior temporal area (posterior), Nucleus caudatus, Nucleus centralis superior lateralis thalami, Nucleus medialis dorsalis thalami, Nucleus medialis dorsalis thalami, pars parvocellularis, Nucleus parafascicularis thalami, Nucleus pulvinaris medialis thalami, Nucleus pulvinaris thalami, pars oralis, Nucleus reticularis thalami, Nucleus ventralis anterior thalami, pars magnocellularis, Nucleus ventralis lateralis thalami, pars caudalis, Nucleus ventralis lateralis thalami, pars oralis, Parietal area PG, medial part, Posterior inferotemporal area, Putamen; caudal, Temporoparietal asscociated area (caudal part), Ventral intraparietal area, Visual area 4, rostroventral parietal area as defined in DLRPK03, substantia nigra, ventral anterior nucleus (thalamus)

Descendant targets:

Agranular frontal area 7 (= rostral dorsolateral premotor area), Area 11, Area 23, Area 23a, Area 23b, Area 23c, Area 24a, Area 24b, Area 24c (rostral part of the cingulate sulcus), Area 24d (rostral part of the cingulate sulcus), Area 31, Area

36, Area 6 (ventral part), Area 7a, Area 7b, Area 8A, Area 8B, Area 9, Caudal auditory parakoniocortex, Central inferotemporal area (ventral), Cortical area 46, Cortical area 9\/46d, Cortical area 9\/46v, Dorsal area 46, Dorsal portion of area 8A, Inferior parietal lobule (lateral posterior cortex below the intraparietal sulcus), Inferotemporal area TE, Intermediate agranula insular cortex, Lateral area 11, Lateral area 12, Lateral auditory field, Lateral intraparietal area, Lateral nucleus (amygdala), dorsal division, Lateral nucleus (amygdala), dorsal intermediate division, Medial area 12, Medial area 9, Medial premotor area 6M, Medial superior temporal area (dorsal), Nucleus caudatus, Nucleus medialis dorsalis thalami, Nucleus medialis dorsalis thalami, pars magnocellularis, Nucleus medialis dorsalis thalami, pars multiformis, Nucleus paraventricularis thalami, Nucleus pulvinaris thalami, Orbital area 10, Orbital area 12, Orbitofrontal area 13, lateral part, Orbitofrontal area 13a, Parietal area PE (cingulate part), Parietal area PG, medial part, Posterior inferotemporal area, Prefrontal area 47\/12, Premotor area 6 (dorsal part), Primary auditory cortex, Primary sensory cortex, Principal Sulcus, Putamen, Putamen; rostral, Rostral area 12, Rostral area 14, Rostral part of area 36, SMA - rostral part, Superior temporal area 2, Temporal area TAa, Temporal area TF (lateral part), Temporal area TF (medial part), Temporal parietooccipital associated area in superior temporal sulcus, Transitional sensory area, Ventral area 46, Visual area 4, anterior lateral auditory belt, area 24, caudal lateral auditory (belt)

Sub-regions:
Area 8A, Cortical area 45

Region: Cortical area 45 (45)

Super-regions:
Cortical area 45 < Frontal eye field < Area 8 < Prefrontal Cortex < Cortical area FL < GM-CerebralCortex < Brain

Sources:
Area 6 (ventral part), Area 7b, Area 8B, Area X (thalamus), Central inferotemporal area (ventral), Centrum medianum thalami, Cortical area 46, Hypothalamus, Lateral auditory field, Lateral intraparietal area, Medial agranular insular cortex, Medial area 9, Nucleus medialis dorsalis thalami, Nucleus medialis dorsalis thalami, pars fibrosa, Nucleus medialis dorsalis thalami, pars lateralis, Nucleus parafascicularis thalami, Nucleus pulvinaris medialis thalami, Nucleus pulvinaris thalami, Nucleus ventralis anterior thalami, pars magnocellularis, Nucleus ventralis anterior thalami, pars parvocellularis, Nucleus ventralis lateralis thalami, pars medialis, Nucleus ventralis lateralis thalami, pars oralis, Parietal area PG, medial part, Posterior inferotemporal area, Premotor area 6 (dorsal part), Primary sensory cortex, Principal Sulcus, Ventral area 46, anterior lateral auditory belt, area 24, caudal lateral auditory (belt), posterior lateral auditory area

Descendant sources:
Agranular frontal area 5 (= rostral ventrolateral premotor area), Area 23, Area 7a, Cortical area PGa, Cortical area TEm, Floor of superior temporal sulcus, Inferotemporal area TE, Intraparietal sulcus associated area in the superior temporal sulcus, Lateral intraparietal area, Lateral intraparietal area (external part), Lateral intraparietal area (internal part), Medial superior temporal area, Middle temporal area, Nucleus pulvinaris thalami, pars oralis, Parietal area PG, medial part, Posterior inferotemporal area, Posterior inferotemporal area (dorsal), V4 transitional area, Ventral intraparietal area, Visual area 2, Visual area 3, Visual area 3A, Visual area 4, temporal visual association area in the lower bank of the superior temporal sulcus

Targets:
Agranular frontal area 7 (= rostral dorsolateral premotor area), Area 11, Area 24c (rostral part of the cingulate sulcus), Area 36, Area 7a, Area 7b, Area 8A, Area 8B, Central inferotemporal area (ventral), Cortical area 46, Inferior parietal lobule (lateral posterior cortex below the intraparietal sulcus), Intermediate agranula insular cortex, Lateral area 11, Lateral area 12, Lateral auditory field, Lateral intraparietal area, Lateral nucleus (amygdala), dorsal division, Lateral nucleus (amygdala), dorsal intermediate division, Medial area 12, Medial area 9, Medial premotor area 6M, Nucleus caudatus, Nucleus medialis dorsalis thalami, Nucleus medialis dorsalis thalami, pars magnocellularis, Nucleus medialis dorsalis thalami, pars multiformis, Nucleus pulvinaris thalami, Orbital area 10, Orbital area 12, Orbitofrontal area 13, lateral part, Orbitofrontal area 13a, Parietal area PG, medial part, Posterior inferotemporal area, Premotor area 6 (dorsal part), Primary sensory cortex, Principal Sulcus, Putamen, Putamen; rostral, Rostral area 12, Rostral area 14, Rostral part of area 36, Temporal area TF (lateral part), Temporal area TF (medial part), Ventral area 46, Visual area 4, anterior lateral auditory belt, area 24, caudal lateral auditory (belt)

Descendant targets:
Agranular frontal area 7 (= rostral dorsolateral premotor area), Area 7a, Area 8A, Area 8B, Cortical area 46, Cortical area 9\/46d, Cortical area 9\/46v, Dorsal portion of area 8A, Inferotemporal area TE, Lateral intraparietal area, Posterior inferotemporal area, Prefrontal area 47\/12

Sub-regions:
Cortical area 45A, Cortical area 45B

Region: Cortical area 45A (45A)

Super-regions:
Cortical area 45A < Cortical area 45 <
Frontal eye field < Area 8 <
Prefrontal Cortex < Cortical area FL <
GM-CerebralCortex < Brain

Sources:
Agranular frontal area 5 (= rostral ventrolateral premotor area), Area 23, Area 7a, Cortical area PGa, Cortical area TEm, Floor of superior temporal sulcus, Inferotemporal area TE, Intraparietal sulcus associated area in the superior temporal sulcus, Lateral intraparietal area, Lateral intraparietal area (external part), Lateral intraparietal area (internal part), Medial superior temporal area, Middle temporal area, Nucleus pulvinaris thalami, pars oralis, Parietal area PG, medial part, Posterior inferotemporal area, Posterior inferotemporal area (dorsal), V4 transitional area, Ventral intraparietal area, Visual area 2, Visual area 3, Visual area 3A, Visual area 4, temporal visual association area in the lower bank of the superior temporal sulcus

Targets:
Area 7a, Cortical area 9\/46d, Dorsal portion of area 8A, Inferotemporal area TE, Lateral intraparietal area, Posterior inferotemporal area, Prefrontal area 47\/12

Region: Cortical area 45B (45B)

Super-regions:
Cortical area 45B < Cortical area 45 <

Frontal eye field < Area 8 <
Prefrontal Cortex < Cortical area FL <
GM-CerebralCortex < Brain

Sources:
Inferotemporal area TE, Lateral
intraparietal area

Targets:
Agranular frontal area 7 (= rostral
dorsolateral premotor area), Area 7a, Area
8A, Area 8B, Cortical area 46, Cortical
area 9\/46v, Inferotemporal area TE,
Lateral intraparietal area, Posterior
inferotemporal area, Prefrontal area 47\/12

Region: Area 8A (8A)

Super-regions:
Area 8A < Frontal eye field < Area 8 <
Prefrontal Cortex < Cortical area FL < GM-
CerebralCortex < Brain

Sources:
Agranular frontal area 5 (= rostral ventrolateral
premotor area), Agranular frontal area 7 (=
rostral dorsolateral premotor area), Anterior
inferotemporal area (ventral), Area 1, Area 10,
Area 12, Area 23, Area 23a, Area 23b, Area
23c, Area 24a, Area 24b, Area 8B, Area 9,
Caudal auditory parakoniocortex, Caudal inferior
parietal lobule, Central inferotemporal area
(dorsal), Corpus geniculatum mediale, Cortical
area 45, Cortical area 45B, Cortical area 46,
Cortical area PGa, Dorsal area 46, Dorsal visual
area 3, Floor of superior temporal sulcus,
Intraparietal sulcus associated area in the
superior temporal sulcus, Lateral auditory field,
Lateral intraparietal area, Lateral intraparietal
area (external part), Lateral intraparietal area
(internal part), Medial premotor area 6M, Medial
superior temporal area, Middle temporal area,
Motor area 4c, Nucleus limitans thalami, Nucleus
medialis dorsalis thalami, Nucleus medialis
dorsalis thalami, pars lateralis, Nucleus
medialis dorsalis thalami, pars multiformis,
Nucleus medialis dorsalis thalami, pars
parvocellularis, Nucleus paraventricularis
thalami, Nucleus pulvinaris inferior thalami,
Nucleus pulvinaris medialis thalami, Nucleus
pulvinaris thalami, pars oralis, Nucleus
supragenicularus thalami, Occipitoparietal area,
Peripheral part of area MT, Postcentral area 3a,
Posterior inferotemporal area, Prefrontal area
47\/12, Premotor area 6 (dorsal part), Primary
auditory cortex, Principal Sulcus, Retroinsular
area, SMA - rostral part, Temporal area TAa,
Temporal parietooccipital associated area in
superior temporal sulcus, Temporoparietal cortex,
V4 transitional area, Ventral area 10, Ventral
area 46, Ventral intraparietal area, Ventral
posterior lateral nucleus (thalamus), Ventral
visual area 3, Visual area 2, Visual area 3A,
Visual area 4, area 24, caudal lateral auditory
(belt), posterior lateral auditory area,
superior parietal lobule (posterior dorsomedial
parietal cortex above the intraparietal sulcus),
temporal visual association area in the lower bank
of the superior temporal sulcus

Descendant sources:
Agranular frontal area 7 (= rostral dorsolateral
premotor area), Area 23, Area 31, Area 8B,
Area 9, Caudal auditory parakoniocortex, Caudal
parietal operculum, Cortical area 45A, Cortical
area 46, Cortical area 9\/46d, Cortical area
9\/46v, Extrastriate area OA, Lateral auditory
parakoniocortex, Lateral intraparietal area,
Medial intraparietal area, Occipitoparietal area,
Prefrontal area 47\/12, Superior temporal area 3,
Temporal area TAa, Temporal parietooccipital
associated area in superior temporal sulcus,
Temporoparietal cortex

Targets:

Agranular frontal area 7 (= rostral dorsolateral premotor area), Area 23a, Area 23b, Area 23c, Area 24a, Area 24b, Area 24c (rostral part of the cingulate sulcus), Area 24d (rostral part of the cingulate sulcus), Area 6 (ventral part), Area 7a, Caudal auditory parakoniocortex, Cortical area 46, Dorsal area 46, Lateral auditory field, Medial premotor area 6M, Nucleus paraventricularis thalami, Nucleus pulvinaris thalami, Premotor area 6 (dorsal part), Primary auditory cortex, Principal Sulcus, SMA - rostral part, Superior temporal area 2, Temporal area TAa, Temporal parietooccipital associated area in superior temporal sulcus, area 24, caudal lateral auditory (belt)

Descendant targets:
Area 23, Area 23c, Area 31, Area 7a, Area 9, Cortical area 46, Cortical area 9\/46d, Inferior parietal lobule (lateral posterior cortex below the intraparietal sulcus), Lateral intraparietal area, Medial superior temporal area (dorsal), Parietal area PE (cingulate part), Posterior inferotemporal area, Transitional sensory area

Sub-regions:
Caudal area 8A, Dorsal portion of area 8A

Region: Dorsal portion of area 8A (8Ad)

Super-regions:
Dorsal portion of area 8A < Area 8A < Frontal eye field < Area 8 < Prefrontal Cortex < Cortical area FL < GM-CerebralCortex < Brain

Sources:
Agranular frontal area 7 (= rostral dorsolateral premotor area), Area 23, Area 31, Area 8B, Area 9, Caudal auditory parakoniocortex, Caudal parietal operculum, Cortical area 45A, Cortical area 46, Cortical area 9\/46d, Cortical area 9\/46v, Extrastriate area OA, Lateral auditory parakoniocortex, Lateral intraparietal area, Medial intraparietal area, Occipitoparietal area, Prefrontal area 47\/12, Superior temporal area 3, Temporal area TAa, Temporal parietooccipital associated area in superior temporal sulcus, Temporoparietal cortex

Targets:
Area 23, Area 23c, Area 31, Area 9, Cortical area 46, Cortical area 9\/46d, Parietal area PE (cingulate part), Transitional sensory area

---
Region: Caudal area 8A (8Ac)

Super-regions:
Caudal area 8A < Area 8A < Frontal eye field < Area 8 < Prefrontal Cortex < Cortical area FL < GM-CerebralCortex < Brain

Sources:
Lateral intraparietal area

Targets:
Area 7a, Inferior parietal lobule (lateral posterior cortex below the intraparietal sulcus), Lateral intraparietal area, Medial superior temporal area (dorsal), Posterior inferotemporal area

---
Region: Area 8B (8B)

Super-regions:

Area 8B < Area 8 < Prefrontal Cortex <
Cortical area FL < GM-CerebralCortex < Brain

Sources:
Agranular frontal area 5 (= rostral ventrolateral premotor area), Agranular frontal area 7 (= rostral dorsolateral premotor area), Amygdala, Area 10, Area 23, Area 24a, Area 31, Area 32, Area 9, Area X (thalamus), Caudal inferior parietal lobule, Central amygdaloid nucleus, lateral part, Cortical area 45, Cortical area 45B, Cortical area 46, Cortical area 9\/46d, Dorsal area 46, Extrastriate area OA, Intralaminar nuclei of the thalamus, Lateral area 12, Lateral area 9, Lateral auditory field, Lateral intraparietal area, Medial area 9, Medial premotor area 6M, Midline nuclei of the thalamus, Nucleus centralis densocellularis thalami, Nucleus centralis inferior thalami, Nucleus centralis superior lateralis thalami, Nucleus limitans thalami, Nucleus medialis dorsalis thalami, Nucleus medialis dorsalis thalami, pars densocellularis, Nucleus medialis dorsalis thalami, pars lateralis, Nucleus medialis dorsalis thalami, pars multiformis, Nucleus medialis dorsalis thalami, pars parvocellularis, Nucleus paracentralis thalami, Nucleus pulvinaris medialis thalami, Nucleus suprageniculatus thalami, Nucleus ventralis lateralis thalami, pars medialis, Occipitoparietal area, Orbitofrontal area 13, Orbitofrontal area 14, Parietal area PG, medial part, Prefrontal area 47\/12, Premotor area 6 (dorsal part), Principal Sulcus, Retrosplenial area 30, Secondary auditory cortex, Superior temporal area 3, Temporal area TF, Temporal area TH, Temporal parietooccipital associated area in superior temporal sulcus, Temporoparietal cortex, anterior lateral auditory belt, area 24, ventral anterior nucleus (thalamus), ventral lateral nucleus (thalamus)

Targets:
Agranular frontal area 2 (= caudal dorsolateral premotor area), Agranular frontal area 6 (= pre-SMA), Agranular frontal area 7 (= rostral dorsolateral premotor area), Area 10, Area 11, Area 23, Area 23c, Area 24c (rostral part of the cingulate sulcus), Area 31, Area 32, Area 7a, Area 8A, Area 9, Cortical area 45, Cortical area 46, Cortical area 9\/46d, Dorsal area 46, Dorsal portion of area 8A, Lateral area 12, Lateral area 9, Lateral auditory field, Lateral intraparietal area, Medial area 9, Medial premotor area 6M, Parietal area PE (cingulate part), Parietal area PG, medial part, Premotor area 6 (dorsal part), Principal Sulcus, Ventral area 46, anterior lateral auditory belt, area 24, dorsal area 9

Region: Area 6 (6#1)

Super-regions:
Area 6 < Cortical area FL < GM-CerebralCortex < Brain

Sources:
Accessory basal amygdaloid nucleus, parvicellular part, Amygdala, Area 7, Area 7a, Area 7b, Area X (thalamus), Basolateral nucleus of amygdala, Caudal and medial superior parietal lobule, Central amygdaloid nucleus, lateral part, Central inferotemporal area (ventral), Centrum medianum thalami, Inferior parietal lobule (lateral posterior cortex below the intraparietal sulcus), Insula, LGN layer 2, Lateral intraparietal area, Medial intraparietal area, Nucleus medialis dorsalis thalami, Nucleus medialis dorsalis thalami, pars fibrosa, Nucleus medialis dorsalis thalami, pars magnocellularis, Nucleus medialis dorsalis thalami, pars parvocellularis, Nucleus paracentralis thalami, Nucleus pulvinaris medialis thalami, Nucleus pulvinaris thalami, Nucleus pulvinaris thalami, pars oralis, Nucleus ventralis lateralis thalami, pars caudalis, Nucleus ventralis lateralis thalami, pars medialis, Nucleus ventralis posterior lateralis thalami, pars oralis, Parietal area PG, medial part, Primary motor area, Primary motor cortex M1, forelimb area, Rostral inferior parietal lobule, Rostral superior parietal lobule, Secondary auditory cortex, Secondary somatosensory cortex, Superior temporal sulcus, Superior temporal sulcus, dorsal, Temporoparietal cortex, Ventral intraparietal area, accessory basal nucleus (amygdala), magnocellular subdivision, area 24, belt line of the sensory system according to CP99, belt line of

the sensorymotor system according to CP99, rostroventral parietal area as defined in DLRPK03, superior parietal lobule (posterior dorsomedial parietal cortex above the intraparietal sulcus), superior temporal gyrus, ventral anterior nucleus (thalamus)

Descendant sources:
Agranular frontal area 2 (= caudal dorsolateral premotor area), Agranular frontal area 3 (= SMA-proper), Agranular frontal area 4 (= caudal ventrolateral premotor area), Agranular frontal area 5 (= rostral ventrolateral premotor area), Agranular frontal area 6 (= pre-SMA), Agranular frontal area 7 (= rostral dorsolateral premotor area), Anterior intraparietal area, Anterior medial nucleus, Area 1, Area 10, Area 12, Area 23, Area 23c, Area 24a, Area 24b, Area 24c (rostral part of the cingulate sulcus), Area 24d (rostral part of the cingulate sulcus), Area 31, Area 46 (dorsal rim of the principal sulcus), Area 46 (ventral rim of the principal sulcus), Area 6 (ventral part), Area 6 (ventral part), Area 7, Area 7a, Area 7b, Area 8, Area 8A, Area 8B, Area 9, Area X (thalamus), Caudal and medial superior parietal lobule, Caudal inferior parietal lobule, Caudal parietal operculum, Central amygdaloid nucleus, lateral part, Centrum medianum thalami, Claustrum, Corpus geniculatum mediale, Cortical amygdaloid nucleus, Cortical area 45, Cortical area 45B, Cortical area 46, Dorsal area 46, Dysgranular insular cortex, Extrastriate area OA, Fascia dentata hippocampi, Frontal eye field, Granular insular cortex, Hypothalamus, Insula, Intralaminar nuclei of the thalamus, LGN layer 2, Lateral Geniculate Nucleus, Lateral area 12, Lateral intraparietal area, Lateral intraparietal area (external part), Lateral intraparietal area (internal part), Laterodorsal nucleus (thalamus), Medial agranular insular cortex, Medial intraparietal area, Medial premotor area 6M, Medial superior temporal area, Midpart of the inferior parietal lobule, Motor area 4c, Nucleus anterior ventralis thalami, Nucleus centralis densocellularis thalami, Nucleus centralis latocellularis thalami, Nucleus centralis superior lateralis thalami, Nucleus limitans thalami, Nucleus medialis dorsalis thalami, Nucleus medialis dorsalis thalami, pars densocellularis, Nucleus medialis dorsalis thalami, pars fibrosa, Nucleus medialis dorsalis thalami, pars multiformis, Nucleus medialis dorsalis thalami, pars parvocellularis, Nucleus paracentralis thalami, Nucleus parafascicularis thalami, Nucleus pulvinaris medialis thalami, Nucleus pulvinaris oralis thalami, Nucleus pulvinaris thalami, Nucleus pulvinaris thalami, pars oralis, Nucleus reticularis thalami, Nucleus reuniens thalami, Nucleus suprageniculatus thalami, Nucleus ventralis anterior thalami, pars magnocellularis, Nucleus ventralis anterior thalami, pars parvocellularis, Nucleus ventralis lateralis thalami, pars caudalis, Nucleus ventralis lateralis thalami, pars medialis, Nucleus ventralis lateralis thalami, pars oralis, Nucleus ventralis lateralis thalami, pars postrema, Nucleus ventralis posterior inferior thalami, Nucleus ventralis posterior lateralis thalami, pars oralis, Nucleus ventralis posterior medialis thalami, Occipitoparietal area, Orbital area 12, Orbitofrontal area 13a, Parasubiculum, Parietal area PE (cingulate part), Parietal area PG, medial part, Postcentral area 3a, Posterior parietal area, Precentral opercular area, Premotor area 6 (dorsal part), Premotor area 6Va, Premotor area 6Vb, Primary motor area, Primary motor cortex M1, forelimb area, Primary motor cortex M1, hindlimb area, Primary sensory area PC, Primary sensory cortex, Primary somatosensory cortex, Principal Sulcus, Pro motor area, Retroinsular area, Rostral inferior parietal lobule, Rostral parietal operculum, Rostral superior parietal lobule, SMA - caudal part, SMA - rostral part, Secondary somatosensory cortex, Superior temporal sulcus, Temporoparietal cortex, Thalamus, Ventolateral Nucleii of Thalamus, Ventral area 46, Ventral intraparietal area, Ventral posterior lateral nucleus (thalamus), Visual area V6A, area 24, area dentata (dentate gyrus), caudal lateral auditory (belt), orofacial representation in MI, superior parietal lobule (posterior dorsomedial parietal cortex above the intraparietal sulcus), ventral anterior nucleus (thalamus)

Targets:
Area 36, Area 7a, Area 7b, Cortical area 9\/46v, Entorhinal cortex, LGN layer 2, Lateral intraparietal area, Lateral nucleus (amygdala), dorsal intermediate division, Nucleus medialis dorsalis thalami, Prefrontal area 47\/12, Primary motor area, Primary motor cortex M1, forelimb area, Primary motor cortex M1, hindlimb area, Pro motor area, Rostral part of area 36, Secondary somatosensory cortex, Temporal area TF (lateral part), Temporal area TF (medial part), area 24, belt line of the sensory system according to CP99, belt line of the sensorymotor system according to CP99, body representation of MI as defined in KSI03, orofacial representation in MI, rostroventral parietal area as defined in DLRPK03

Descendant targets:
Agranular frontal area 2 (= caudal dorsolateral premotor area), Agranular frontal area 3 (= SMA-proper), Agranular frontal area 4 (= caudal ventrolateral premotor area), Agranular frontal area 5 (= rostral ventrolateral premotor area), Agranular frontal area 6 (= pre-SMA), Agranular frontal area 7 (= rostral dorsolateral premotor area), Agranular insula, Anterior intraparietal area, Area 1, Area 12, Area 23, Area 23c, Area 24a, Area 24b, Area 24c (rostral part of the cingulate sulcus), Area 24d (rostral part of the cingulate sulcus), Area 3, Area 31, Area 36, Area 46 (dorsal rim of the principal sulcus), Area 46 (ventral rim of the principal sulcus), Area 6 (ventral part), Area 7, Area 7a, Area 7b, Area 8, Area 8A, Area 8B, Area 9, Area X (thalamus), Caudal and medial superior parietal lobule, Caudal inferior parietal lobule, Caudal parietal operculum, Central amygdaloid nucleus, lateral part, Centrum medianum thalami, Claustrum, Cortical area 44, Cortical area 45, Cortical area 45A, Cortical area 46, Cortical area 9\/46d, Cortical area 9\/46v, Dorsal area 46, Dorsal portion of area 8A, Dysgranular insular cortex, Fascia dentata hippocampi, Granular insular cortex, Gustatory cortex, Inferior parietal lobule (lateral posterior cortex below the intraparietal sulcus), Insular proisocortex, Intermediate agranula insular cortex, LGN layer 2, Lateral area 11, Lateral area 12, Lateral intraparietal area, Medial area 12, Medial area 9, Medial intraparietal area, Medial premotor area 6M, Medial superior temporal area (dorsal), Midpart of the inferior parietal lobule, Nucleus caudatus, Nucleus centralis superior lateralis thalami, Nucleus medialis dorsalis thalami, Nucleus medialis dorsalis thalami, pars multiformis, Nucleus medialis dorsalis thalami, pars parvocellularis, Nucleus paracentralis thalami, Nucleus parafascicularis thalami, Nucleus pulvinaris medialis thalami, Nucleus pulvinaris thalami, Nucleus reticularis thalami, Nucleus subthalamicus, Nucleus ventralis anterior thalami, pars magnocellularis, Nucleus ventralis anterior thalami, pars parvocellularis, Nucleus ventralis lateralis thalami, pars caudalis, Nucleus ventralis lateralis thalami, pars medialis, Nucleus ventralis lateralis thalami, pars oralis, Nucleus ventralis lateralis thalami, pars postrema, Nucleus ventralis posterior lateralis thalami, pars caudalis, Nucleus ventralis posterior lateralis thalami, pars oralis, Occipitoparietal area, Orbital area 10, Orbital area 12, Orbitofrontal area 13, Orbitofrontal area 13, lateral part, Orbitofrontal area 13, medial part, Orbitofrontal area 13a, Parietal area PE (cingulate part), Parietal area PG, medial part, Postcentral area 3a, Postcentral area 3b, Posteromedial agranular insular cortex, Precentral opercular area, Prefrontal area 47\/12, Premotor area 6Va, Premotor area 6Vb, Primary motor area, Primary motor cortex M1, forelimb area, Primary motor cortex M1, hindlimb area, Primary sensory area PC, Primary sensory cortex, Principal Sulcus, Pro motor area, Putamen, Putamen; caudal, Putamen; rostral, Rostral area 12, Rostral inferior parietal lobule, Rostral parietal operculum, Rostral part of area 36, Rostral superior parietal lobule, SMA - caudal part, SMA - rostral part, Secondary somatosensory cortex, Temporal area TF (lateral part), Temporal area TH, Temporal parietooccipital associated area in superior temporal sulcus, Transitional sensory area, Ventral area 46, Ventral posterior lateral nucleus (thalamus), Visual area V6A, area 24, caudal lateral auditory (belt), dorsal area 9, orofacial representation in MI, rostroventral parietal area as defined in DLRPK03, substantia nigra, superior parietal lobule (posterior dorsomedial parietal cortex above the intraparietal sulcus), ventral anterior nucleus (thalamus)

Sub-regions:
Area 6 (ventral part), Cortical area 44, Medial premotor area 6M, Premotor area 6 (dorsal part), Premotor area 6b-beta

---
Region: Area 6 (ventral part) (6V)

Super-regions:
Area 6 (ventral part) < Area 6 < Cortical area FL < GM-CerebralCortex < Brain

Sources:
Agranular frontal area 3 (= SMA-proper), Agranular frontal area 6 (= pre-SMA), Agranular frontal area 7 (= rostral dorsolateral premotor area), Anterior intraparietal area, Area 1, Area 10, Area 12, Area 23c, Area 24c (rostral part of the cingulate sulcus), Area 7a, Area 7b, Area 8, Area 8A, Area X (thalamus), Caudal parietal operculum, Central amygdaloid nucleus, lateral part, Centrum medianum thalami, Cortical area 46, LGN layer 2, Lateral Geniculate Nucleus, Lateral intraparietal area, Medial

premotor area 6M, Nucleus medialis dorsalis thalami, Nucleus paracentralis thalami, Nucleus pulvinaris oralis thalami, Nucleus pulvinaris thalami, Nucleus ventralis anterior thalami, pars parvocellularis, Nucleus ventralis lateralis thalami, pars caudalis, Nucleus ventralis lateralis thalami, pars medialis, Nucleus ventralis lateralis thalami, pars oralis, Nucleus ventralis posterior lateralis thalami, pars oralis, Nucleus ventralis posterior medialis thalami, Orbital area 12, Postcentral area 3a, Premotor area 6 (dorsal part), Primary motor area, Primary motor cortex M1, forelimb area, Pro motor area, Retroinsular area, Rostral inferior parietal lobule, Rostral parietal operculum, Rostral superior parietal lobule, Secondary somatosensory cortex, Ventral area 46, Ventral posterior lateral nucleus (thalamus), caudal lateral auditory (belt), superior parietal lobule (posterior dorsomedial parietal cortex above the intraparietal sulcus), ventral anterior nucleus (thalamus)

Descendant sources:
Agranular frontal area 3 (= SMA-proper), Agranular frontal area 4 (= caudal ventrolateral premotor area), Agranular frontal area 5 (= rostral ventrolateral premotor area), Anterior intraparietal area, Area 24a, Area 24c (rostral part of the cingulate sulcus), Area 6 (ventral part), Area 7a, Area 7b, Area X (thalamus), Central amygdaloid nucleus, lateral part, Centrum medianum thalami, Cortical area 46, Insula, Lateral intraparietal area, Lateral intraparietal area (external part), Lateral intraparietal area (internal part), Medial agranular insular cortex, Medial intraparietal area, Nucleus medialis dorsalis thalami, Nucleus medialis dorsalis thalami, pars fibrosa, Nucleus medialis dorsalis thalami, pars parvocellularis, Nucleus paracentralis thalami, Nucleus parafascicularis thalami, Nucleus pulvinaris medialis thalami, Nucleus pulvinaris oralis thalami, Nucleus ventralis anterior thalami, pars magnocellularis, Nucleus ventralis anterior thalami, pars parvocellularis, Nucleus ventralis lateralis thalami, pars caudalis, Nucleus ventralis lateralis thalami, pars medialis, Nucleus ventralis lateralis thalami, pars oralis, Nucleus ventralis posterior inferior thalami, Nucleus ventralis posterior lateralis thalami, pars oralis, Nucleus ventralis posterior medialis thalami, Orbitofrontal area 13a, Parasubiculum, Precentral opercular area, Primary motor area, Primary motor cortex M1, forelimb area, Primary sensory area PC, Primary somatosensory cortex, Principal Sulcus, Rostral inferior parietal lobule, Rostral parietal operculum, SMA - rostral part, Secondary somatosensory cortex, Ventolateral Nucleii of Thalamus, Ventral area 46, Ventral intraparietal area, Ventral posterior lateral nucleus (thalamus), Visual area V6A, area 24, caudal lateral auditory (belt), orofacial representation in MI, superior parietal lobule (posterior dorsomedial parietal cortex above the intraparietal sulcus)

Targets:
Agranular frontal area 2 (= caudal dorsolateral premotor area), Agranular frontal area 3 (= SMA-proper), Agranular frontal area 7 (= rostral dorsolateral premotor area), Area 1, Area 12, Area 24a, Area 24b, Area 24c (rostral part of the cingulate sulcus), Area 7b, Cortical area 45, Cortical area 46, LGN layer 2, Lateral intraparietal area, Medial area 9, Medial premotor area 6M, Postcentral area 3a, Primary motor area, Primary motor cortex M1, forelimb area, Pro motor area, Rostral inferior parietal lobule, Rostral parietal operculum, Rostral superior parietal lobule, Secondary somatosensory cortex, Ventral area 46, area 24, orofacial representation in MI

Descendant targets:
Agranular frontal area 2 (= caudal dorsolateral premotor area), Agranular frontal area 3 (= SMA-proper), Agranular frontal area 4 (= caudal ventrolateral premotor area), Agranular frontal area 5 (= rostral ventrolateral premotor area), Agranular frontal area 6 (= pre-SMA), Agranular frontal area 7 (= rostral dorsolateral premotor area), Agranular insula, Anterior intraparietal area, Area 1, Area 23c, Area 24a, Area 24b, Area 24c (rostral part of the cingulate sulcus), Area 24d (rostral part of the cingulate sulcus), Area 36, Area 7, Area 7b, Area 8A, Area 8B, Caudal and medial superior parietal lobule, Caudal inferior parietal lobule, Caudal parietal operculum, Cortical area 44, Cortical area 45A, Dysgranular insular cortex, Granular insular cortex, Gustatory cortex, Inferior parietal lobule (lateral posterior cortex below the intraparietal sulcus), Insular proisocortex, Intermediate agranula insular cortex, LGN layer 2, Lateral area 11, Lateral area 12, Lateral intraparietal area, Medial area

12, Medial intraparietal area, Medial premotor area 6M, Midpart of the inferior parietal lobule, Nucleus ventralis anterior thalami, pars magnocellularis, Nucleus ventralis lateralis thalami, pars oralis, Orbital area 10, Orbital area 12, Orbitofrontal area 13, Orbitofrontal area 13, lateral part, Orbitofrontal area 13, medial part, Orbitofrontal area 13a, Postcentral area 3a, Postcentral area 3b, Posteromedial agranular insular cortex, Precentral opercular area, Prefrontal area 47\/12, Primary motor area, Primary motor cortex M1, forelimb area, Primary sensory area PC, Primary sensory cortex, Principal Sulcus, Pro motor area, Putamen; rostral, Rostral area 12, Rostral inferior parietal lobule, Rostral parietal operculum, Rostral part of area 36, SMA - rostral part, Secondary somatosensory cortex, Temporal area TF (lateral part), Temporal area TH, Temporal parietooccipital associated area in superior temporal sulcus, Ventral area 46, Visual area V6A, area 24, orofacial representation in MI, rostroventral parietal area as defined in DLRPK03

Sub-regions:
Agranular frontal area 4 (= caudal ventrolateral premotor area), Agranular frontal area 5 (= rostral ventrolateral premotor area), Motor area 4c, Precentral opercular area, Premotor area 6Va, Premotor area 6Vb

---
Region: Agranular frontal area 5 (= rostral ventrolateral premotor area) (F5)

Super-regions:
Agranular frontal area 5 (= rostral ventrolateral premotor area) < Area 6 (ventral part) < Area 6 < Cortical area FL < GM-CerebralCortex < Brain

Sources:
Agranular frontal area 3 (= SMA-proper), Agranular frontal area 4 (= caudal ventrolateral premotor area), Anterior intraparietal area, Area 24a, Area 24c (rostral part of the cingulate sulcus), Area 6 (ventral part), Area 7a, Area 7b, Area X (thalamus), Central amygdaloid nucleus, lateral part, Centrum medianum thalami, Cortical area 46, Lateral intraparietal area, Lateral intraparietal area (external part), Medial intraparietal area, Nucleus medialis dorsalis thalami, Nucleus paracentralis thalami, Nucleus parafascicularis thalami, Nucleus pulvinaris medialis thalami, Nucleus pulvinaris oralis thalami, Nucleus ventralis anterior thalami, pars magnocellularis, Nucleus ventralis anterior thalami, pars parvocellularis, Nucleus ventralis lateralis thalami, pars caudalis, Nucleus ventralis lateralis thalami, pars medialis, Nucleus ventralis lateralis thalami, pars oralis, Nucleus ventralis posterior inferior thalami, Nucleus ventralis posterior lateralis thalami, pars oralis, Nucleus ventralis posterior medialis thalami, Parasubiculum, Precentral opercular area, Primary motor area, Primary motor cortex M1, forelimb area, Primary somatosensory cortex, Rostral inferior parietal lobule, Rostral parietal operculum, Secondary somatosensory cortex, Ventolateral Nucleii of Thalamus, Ventral area 46, Visual area V6A, caudal lateral auditory (belt), orofacial representation in MI, superior parietal lobule (posterior dorsomedial parietal cortex above the intraparietal sulcus)

Targets:
Agranular frontal area 2 (= caudal dorsolateral premotor area), Agranular frontal area 3 (= SMA-proper), Agranular frontal area 4 (= caudal ventrolateral premotor area), Agranular frontal area 6 (= pre-SMA), Agranular frontal area 7 (= rostral dorsolateral premotor area), Agranular insula, Anterior intraparietal area, Area 1, Area 23c, Area 24a, Area 24b, Area 24c (rostral part of the cingulate sulcus), Area 24d (rostral part of the cingulate sulcus), Area 8A, Area 8B, Caudal and medial superior parietal lobule, Caudal inferior parietal lobule, Caudal parietal operculum, Cortical area 44, Cortical area 45A, Dysgranular insular cortex, Granular insular cortex, Gustatory cortex, Insular proisocortex, LGN layer 2, Lateral intraparietal area, Medial intraparietal area, Medial premotor area 6M, Midpart of the inferior parietal lobule, Nucleus ventralis anterior thalami, pars

magnocellularis, Nucleus ventralis lateralis thalami, pars oralis, Postcentral area 3a, Postcentral area 3b, Precentral opercular area, Prefrontal area 47\/12, Primary motor area, Primary motor cortex M1, forelimb area, Pro motor area, Rostral inferior parietal lobule, Rostral parietal operculum, Secondary somatosensory cortex, Temporal parietooccipital associated area in superior temporal sulcus, Ventral area 46, Visual area V6A, orofacial representation in MI, rostroventral parietal area as defined in DLRPK03

Region: Precentral opercular area (PrCO)

Super-regions:
Precentral opercular area < Area 6 (ventral part) < Area 6 < Cortical area FL < GM-CerebralCortex < Brain

Sources:
Agranular frontal area 4 (= caudal ventrolateral premotor area), Agranular frontal area 5 (= rostral ventrolateral premotor area), Insula, Medial agranular insular cortex, Nucleus medialis dorsalis thalami, Nucleus medialis dorsalis thalami, pars fibrosa, Nucleus ventralis anterior thalami, pars parvocellularis, Orbitofrontal area 13a, Primary motor area, Primary motor cortex M1, forelimb area, area 24

Targets:
Agranular frontal area 4 (= caudal ventrolateral premotor area), Agranular frontal area 5 (= rostral ventrolateral premotor area), Area 24c (rostral part of the cingulate sulcus), Area 36, Area 7b, Intermediate agranula insular cortex, Lateral area 11, Medial area 12, Medial premotor area 6M, Nucleus ventralis lateralis thalami, pars oralis, Orbital area 10, Orbital area 12, Orbitofrontal area 13, Orbitofrontal area 13, lateral part, Orbitofrontal area 13, medial part, Posteromedial agranular insular cortex, Primary motor area, Primary motor cortex M1, forelimb area, Primary sensory cortex, Putamen; rostral, Rostral area 12, Rostral part of area 36, Temporal area TF (lateral part), Temporal area TH, area 24

Region: Motor area 4c (4c)

Super-regions:
Motor area 4c < Area 6 (ventral part) < Area 6 < Cortical area FL < GM-CerebralCortex < Brain

Sources:
Area X (thalamus), Central amygdaloid nucleus, lateral part, Centrum medianum thalami, Nucleus medialis dorsalis thalami, Nucleus paracentralis thalami, Nucleus pulvinaris oralis thalami, Nucleus ventralis lateralis thalami, pars caudalis, Nucleus ventralis lateralis thalami, pars medialis, Nucleus ventralis lateralis thalami, pars oralis, Nucleus ventralis posterior lateralis thalami, pars oralis

Targets:
Area 23c, Area 24c (rostral part of the cingulate sulcus), Area 7, Area 7b, Area 8A, Inferior parietal lobule (lateral posterior cortex below the intraparietal sulcus), Medial premotor area 6M

Region: Premotor area 6Vb (6Vb)

Super-regions:
Premotor area 6Vb < Area 6 (ventral part) < Area 6 < Cortical area FL < GM-CerebralCortex < Brain

Sources:
Medial agranular insular cortex, Principal Sulcus,

SMA - rostral part

Targets:
Area 24c (rostral part of the cingulate sulcus), Area 7b, Intermediate agranula insular cortex, Lateral area 11, Lateral area 12, Medial area 12, Medial premotor area 6M, Orbital area 12, Orbitofrontal area 13, Orbitofrontal area 13, lateral part, Orbitofrontal area 13a, Primary sensory cortex, Principal Sulcus, Putamen; rostral, Rostral area 12, SMA - rostral part, Ventral area 46

Region: Premotor area 6Va (6Va)

Super-regions:
Premotor area 6Va < Area 6 (ventral part) < Area 6 < Cortical area FL < GM-CerebralCortex < Brain

Sources:
Orbitofrontal area 13a, Principal Sulcus, SMA - rostral part

Targets:
Area 24c (rostral part of the cingulate sulcus), Area 7, Area 7b, Inferior parietal lobule (lateral posterior cortex below the intraparietal sulcus), Intermediate agranula insular cortex, Lateral area 11, Lateral area 12, Medial area 12, Medial premotor area 6M, Orbital area 10, Orbital area 12, Orbitofrontal area 13, lateral part, Orbitofrontal area 13a, Primary motor area, Primary sensory cortex, Principal Sulcus, Putamen; rostral, Rostral area 12, SMA - rostral part, Ventral area 46

Region: Agranular frontal area 4 (= caudal ventrolateral premotor area) (F4)

Super-regions:
Agranular frontal area 4 (= caudal ventrolateral premotor area) < Area 6 (ventral part) < Area 6 < Cortical area FL < GM-CerebralCortex < Brain

Sources:
Agranular frontal area 5 (= rostral ventrolateral premotor area), Anterior intraparietal area, Area 7b, Area X (thalamus), Central amygdaloid nucleus, lateral part, Centrum medianum thalami, Lateral intraparietal area (internal part), Medial intraparietal area, Nucleus medialis dorsalis thalami, Nucleus medialis dorsalis thalami, pars parvocellularis, Nucleus paracentralis thalami, Nucleus pulvinaris oralis thalami, Nucleus ventralis anterior thalami, pars parvocellularis, Nucleus ventralis lateralis thalami, pars caudalis, Nucleus ventralis lateralis thalami, pars medialis, Nucleus ventralis lateralis thalami, pars oralis, Nucleus ventralis posterior inferior thalami, Nucleus ventralis posterior lateralis thalami, pars oralis, Nucleus ventralis posterior medialis thalami, Precentral opercular area, Primary motor area, Primary motor cortex M1, forelimb area, Primary sensory area PC, Primary somatosensory cortex, Rostral inferior parietal lobule, Secondary somatosensory cortex, Ventral area 46, Ventral intraparietal area, Ventral posterior lateral nucleus (thalamus), caudal lateral auditory (belt), orofacial representation in MI, superior parietal lobule (posterior dorsomedial parietal cortex above the intraparietal sulcus)

Targets:
Agranular frontal area 2 (= caudal dorsolateral premotor area), Agranular frontal area 3 (= SMA-proper), Agranular frontal area 5 (= rostral ventrolateral premotor area), Agranular frontal area 6 (= pre-SMA), Anterior intraparietal area, Area 24d (rostral part of the cingulate sulcus), Medial premotor area 6M, Nucleus ventralis lateralis thalami, pars oralis, Precentral opercular area, Primary motor area, Primary motor cortex M1, forelimb area, Primary sensory area PC, Rostral inferior parietal lobule, Secondary somatosensory cortex, Ventral area 46,

orofacial representation in MI

Region: Cortical area 44 (44)

Super-regions:
Cortical area 44 < Area 6 < Cortical area FL < GM-CerebralCortex < Brain

Sources:
Agranular frontal area 5 (= rostral ventrolateral premotor area)

Targets:
Cortical area 9\/46v, Parietal area PE (cingulate part), Prefrontal area 47\/12, Pro motor area, Secondary somatosensory cortex

---

Region: Premotor area 6b-beta (6b-beta)

Super-regions:
Premotor area 6b-beta < Area 6 < Cortical area FL < GM-CerebralCortex < Brain

Sources:
area 24

Targets:
area 24

Region: Premotor area 6 (dorsal part) (6D)

Super-regions:
Premotor area 6 (dorsal part) < Area 6 < Cortical area FL < GM-CerebralCortex < Brain

Sources:
Area 7a, Area 7b, Area 8A, Area 8B, Area X (thalamus), Caudal and medial superior parietal lobule, Central amygdaloid nucleus, lateral part, Centrum medianum thalami, Claustrum, Cortical area 45, Cortical area 46, Hypothalamus, Lateral intraparietal area, Medial intraparietal area, Nucleus centralis superior lateralis thalami, Nucleus medialis dorsalis thalami, Nucleus medialis dorsalis thalami, pars densocellularis, Nucleus medialis dorsalis thalami, pars multiformis, Nucleus medialis dorsalis thalami, pars parvocellularis, Nucleus paracentralis thalami, Nucleus parafascicularis thalami, Nucleus pulvinaris thalami, pars oralis, Nucleus ventralis anterior thalami, pars magnocellularis, Nucleus ventralis anterior thalami, pars parvocellularis, Nucleus ventralis lateralis thalami, pars caudalis, Nucleus ventralis lateralis thalami, pars medialis, Nucleus ventralis lateralis thalami, pars oralis, Nucleus ventralis posterior lateralis thalami, pars oralis, Parietal area PG, medial part, Primary sensory cortex, Thalamus, Ventral area 46, Ventral intraparietal area, Ventral posterior lateral nucleus (thalamus), caudal lateral auditory (belt), ventral anterior nucleus (thalamus)

Descendant sources:
Agranular frontal area 2 (= caudal dorsolateral premotor area), Agranular frontal area 3 (= SMA-proper), Agranular frontal area 4 (= caudal ventrolateral premotor area), Agranular frontal area 5 (= rostral ventrolateral premotor area), Agranular frontal area 6 (= pre-SMA), Agranular frontal area 7 (= rostral dorsolateral premotor area), Anterior intraparietal area, Anterior medial nucleus, Area 12, Area 23, Area 23c, Area 24a, Area 24b, Area 24c (rostral part of the cingulate sulcus), Area 24d (rostral part of the cingulate sulcus), Area 6 (ventral part), Area 6 (ventral part), Area 7a, Area 7b, Area 8, Area 8A, Area 8B, Area 9, Area X (thalamus), Caudal and medial superior parietal lobule, Central amygdaloid nucleus, lateral part, Centrum medianum thalami, Claustrum, Cortical area 45, Cortical area 45B, Cortical area 46, Extrastriate area OA, Frontal eye field, Hypothalamus, Intralaminar nuclei of the thalamus, Lateral intraparietal area, Lateral intraparietal area (external part), Lateral intraparietal area (internal part), Laterodorsal nucleus

(thalamus), Medial intraparietal area, Medial premotor area 6M, Medial superior temporal area, Midpart of the inferior parietal lobule, Nucleus anterior ventralis thalami, Nucleus centralis densocellularis thalami, Nucleus centralis latocellularis thalami, Nucleus centralis superior lateralis thalami, Nucleus limitans thalami, Nucleus medialis dorsalis thalami, Nucleus medialis dorsalis thalami, pars densocellularis, Nucleus medialis dorsalis thalami, pars multiformis, Nucleus medialis dorsalis thalami, pars parvocellularis, Nucleus paracentralis thalami, Nucleus parafascicularis thalami, Nucleus pulvinaris medialis thalami, Nucleus pulvinaris oralis thalami, Nucleus pulvinaris thalami, Nucleus pulvinaris thalami, pars oralis, Nucleus reticularis thalami, Nucleus reuniens thalami, Nucleus supragenicularus thalami, Nucleus ventralis anterior thalami, pars magnocellularis, Nucleus ventralis anterior thalami, pars parvocellularis, Nucleus ventralis lateralis thalami, pars caudalis, Nucleus ventralis lateralis thalami, pars medialis, Nucleus ventralis lateralis thalami, pars oralis, Nucleus ventralis lateralis thalami, pars postrema, Nucleus ventralis posterior inferior thalami, Nucleus ventralis posterior lateralis thalami, pars oralis, Nucleus ventralis posterior medialis thalami, Parietal area PE (cingulate part), Parietal area PG, medial part, Posterior parietal area, Primary motor area, Primary motor cortex M1, forelimb area, Primary motor cortex M1, hindlimb area, Primary sensory cortex, Primary somatosensory cortex, Principal Sulcus, Rostral superior parietal lobule, SMA - rostral part, Secondary somatosensory cortex, Superior temporal sulcus, Ventolateral Nucleii of Thalamus, Ventral intraparietal area, Ventral posterior lateral nucleus (thalamus), Visual area V6A, area dentata (dentate gyrus), caudal lateral auditory (belt), superior parietal lobule (posterior dorsomedial parietal cortex above the intraparietal sulcus), ventral anterior nucleus (thalamus)

Targets:

Area 6 (ventral part), Area 7, Area 7a, Area 7b, Area 8A, Area 8B, Area X (thalamus), Central amygdaloid nucleus, lateral part, Centrum medianum thalami, Claustrum, Cortical area 45, Dorsal area 46, Fascia dentata hippocampi, Inferior parietal lobule (lateral posterior cortex below the intraparietal sulcus), Lateral area 12, Lateral intraparietal area, Medial area 12, Medial area 9, Nucleus caudatus, Nucleus medialis dorsalis thalami, Nucleus medialis dorsalis thalami, pars multiformis, Nucleus medialis dorsalis thalami, pars parvocellularis, Nucleus paracentralis thalami, Nucleus parafascicularis thalami, Nucleus reticularis thalami, Nucleus subthalamicus, Nucleus ventralis anterior thalami, pars parvocellularis, Nucleus ventralis lateralis thalami, pars caudalis, Nucleus ventralis lateralis thalami, pars medialis, Nucleus ventralis lateralis thalami, pars oralis, Nucleus ventralis lateralis thalami, pars postrema, Orbital area 12, Orbitofrontal area 13, lateral part, Orbitofrontal area 13a, Parietal area PG, medial part, Primary motor cortex M1, forelimb area, Putamen, Putamen; caudal, Putamen; rostral, Rostral area 12, Ventral area 46, Ventral posterior lateral nucleus (thalamus), caudal lateral auditory (belt), dorsal area 9, substantia nigra, ventral anterior nucleus (thalamus)

Descendant targets:

Agranular frontal area 2 (= caudal dorsolateral premotor area), Agranular frontal area 3 (= SMA-proper), Agranular frontal area 6 (= pre-SMA), Agranular frontal area 7 (= rostral dorsolateral premotor area), Area 12, Area 23c, Area 24c (rostral part of the cingulate sulcus), Area 24d (rostral part of the cingulate sulcus), Area 31, Area 6 (ventral part), Area 8, Area 8A, Area 8B, Area 9, Area X (thalamus), Caudal and medial superior parietal lobule, Central amygdaloid nucleus, lateral part, Centrum medianum thalami, Claustrum, Cortical area 46, Cortical area 9\/46d, Dorsal portion of area 8A, Lateral area 12, Lateral intraparietal area, Medial premotor area 6M, Nucleus caudatus, Nucleus centralis superior lateralis thalami, Nucleus medialis dorsalis thalami, Nucleus medialis dorsalis thalami, pars multiformis, Nucleus medialis dorsalis thalami, pars parvocellularis, Nucleus paracentralis thalami, Nucleus parafascicularis thalami, Nucleus pulvinaris medialis thalami, Nucleus reticularis thalami, Nucleus ventralis anterior thalami, pars magnocellularis, Nucleus ventralis anterior thalami, pars parvocellularis, Nucleus ventralis lateralis thalami, pars caudalis, Nucleus ventralis lateralis thalami, pars medialis, Nucleus ventralis lateralis thalami, pars oralis,

Orbital area 12, Parietal area PE (cingulate part), Parietal area PG, medial part, Primary motor area, Primary motor cortex M1, forelimb area, Principal Sulcus, Putamen, Putamen; caudal, Putamen; rostral, Rostral area 12, SMA - rostral part, Transitional sensory area, Ventral area 46, Visual area V6A, area 24, substantia nigra, ventral anterior nucleus (thalamus)

Sub-regions:
Agranular frontal area 2 (= caudal dorsolateral premotor area), Agranular frontal area 7 (= rostral dorsolateral premotor area)

Region: Agranular frontal area 7 (= rostral dorsolateral premotor area) (F7)

Super-regions:
Agranular frontal area 7 (= rostral dorsolateral premotor area) < Premotor area 6 (dorsal part) < Area 6 < Cortical area FL < GM-CerebralCortex < Brain

Sources:
Agranular frontal area 2 (= caudal dorsolateral premotor area), Agranular frontal area 3 (= SMA-proper), Agranular frontal area 5 (= rostral ventrolateral premotor area), Agranular frontal area 6 (= pre-SMA), Area 12, Area 23, Area 23c, Area 24a, Area 24b, Area 24c (rostral part of the cingulate sulcus), Area 24d (rostral part of the cingulate sulcus), Area 6 (ventral part), Area 6 (ventral part), Area 7a, Area 7b, Area 8, Area 8A, Area 8B, Area 9, Area X (thalamus), Caudal and medial superior parietal lobule, Central amygdaloid nucleus, lateral part, Centrum medianum thalami, Claustrum, Cortical area 45, Cortical area 45B, Cortical area 46, Extrastriate area OA, Frontal eye field, Hypothalamus, Intralaminar nuclei of the thalamus, Lateral intraparietal area, Medial intraparietal area, Medial premotor area 6M, Midpart of the inferior parietal lobule, Nucleus centralis densocellularis thalami, Nucleus centralis latocellularis thalami, Nucleus centralis superior lateralis thalami, Nucleus limitans thalami, Nucleus medialis dorsalis thalami, Nucleus medialis dorsalis thalami, pars densocellularis, Nucleus medialis dorsalis thalami, pars multiformis, Nucleus medialis dorsalis thalami, pars parvocellularis, Nucleus paracentralis thalami, Nucleus parafascicularis thalami, Nucleus pulvinaris medialis thalami, Nucleus pulvinaris oralis thalami, Nucleus pulvinaris thalami, Nucleus pulvinaris thalami, pars oralis, Nucleus reuniens thalami, Nucleus supragenicularus thalami, Nucleus ventralis anterior thalami, pars magnocellularis, Nucleus ventralis anterior thalami, pars parvocellularis, Nucleus ventralis lateralis thalami, pars caudalis, Nucleus ventralis lateralis thalami, pars medialis, Nucleus ventralis lateralis thalami, pars oralis, Nucleus ventralis lateralis thalami, pars postrema, Nucleus ventralis posterior lateralis thalami, pars oralis, Parietal area PE (cingulate part), Parietal area PG, medial part, Primary motor area, Primary sensory cortex, Primary somatosensory cortex, Principal Sulcus, Rostral superior parietal lobule, SMA - rostral part, Superior temporal sulcus, Ventolateral Nucleii of Thalamus, Ventral intraparietal area, Ventral posterior lateral nucleus (thalamus), Visual area V6A, area dentata (dentate gyrus), caudal lateral auditory (belt), superior parietal lobule (posterior dorsomedial parietal cortex above the intraparietal sulcus), ventral anterior nucleus (thalamus)

Targets:
Agranular frontal area 2 (= caudal dorsolateral premotor area), Agranular frontal area 3 (= SMA-proper), Agranular frontal area 6 (= pre-SMA), Area 12, Area 23c, Area 24c (rostral part of the cingulate sulcus), Area 24d (rostral part of the cingulate sulcus), Area 31, Area 6 (ventral part), Area 8, Area 8A, Area 8B, Area 9, Area X (thalamus), Caudal and medial superior parietal lobule, Centrum medianum thalami, Claustrum, Cortical area 46, Cortical area 9\/46d, Dorsal portion of area 8A, Lateral area 12, Lateral intraparietal area, Medial premotor area 6M, Nucleus caudatus, Nucleus centralis superior lateralis

thalami, Nucleus medialis dorsalis thalami, Nucleus medialis dorsalis thalami, pars multiformis, Nucleus medialis dorsalis thalami, pars parvocellularis, Nucleus paracentralis thalami, Nucleus parafascicularis thalami, Nucleus pulvinaris medialis thalami, Nucleus ventralis anterior thalami, pars magnocellularis, Nucleus ventralis anterior thalami, pars parvocellularis, Nucleus ventralis lateralis thalami, pars caudalis, Orbital area 12, Parietal area PE (cingulate part), Parietal area PG, medial part, Primary motor area, Principal Sulcus, Putamen, Putamen; caudal, Putamen; rostral, Rostral area 12, SMA - rostral part, Transitional sensory area, Ventral area 46, Visual area V6A, area 24, substantia nigra

---
Region: Agranular frontal area 2 (= caudal dorsolateral premotor area) (F2)

Super-regions:
Agranular frontal area 2 (= caudal dorsolateral premotor area) < Premotor area 6 (dorsal part) < Area 6 < Cortical area FL < GM-CerebralCortex < Brain

Sources:
Agranular frontal area 3 (= SMA-proper), Agranular frontal area 4 (= caudal ventrolateral premotor area), Agranular frontal area 5 (= rostral ventrolateral premotor area), Agranular frontal area 6 (= pre-SMA), Agranular frontal area 7 (= rostral dorsolateral premotor area), Anterior intraparietal area, Anterior medial nucleus, Area 23c, Area 24a, Area 24b, Area 24c (rostral part of the cingulate sulcus), Area 24d (rostral part of the cingulate sulcus), Area 6 (ventral part), Area 7a, Area 7b, Area 8B, Area X (thalamus), Caudal and medial superior parietal lobule, Central amygdaloid nucleus, lateral part, Centrum medianum thalami, Cortical area 46, Intralaminar nuclei of the thalamus, Lateral intraparietal area (external part), Lateral intraparietal area (internal part), Laterodorsal nucleus (thalamus), Medial intraparietal area, Medial premotor area 6M, Medial superior temporal area, Nucleus anterior ventralis thalami, Nucleus limitans thalami, Nucleus medialis dorsalis thalami, Nucleus paracentralis thalami, Nucleus pulvinaris medialis thalami, Nucleus pulvinaris oralis thalami, Nucleus pulvinaris thalami, Nucleus pulvinaris thalami, pars oralis, Nucleus reticularis thalami, Nucleus reuniens thalami, Nucleus ventralis anterior thalami, pars parvocellularis, Nucleus ventralis lateralis thalami, pars caudalis, Nucleus ventralis lateralis thalami, pars medialis, Nucleus ventralis lateralis thalami, pars oralis, Nucleus ventralis lateralis thalami, pars postrema, Nucleus ventralis posterior inferior thalami, Nucleus ventralis posterior lateralis thalami, pars oralis, Nucleus ventralis posterior medialis thalami, Parietal area PE (cingulate part), Parietal area PG, medial part, Posterior parietal area, Primary motor area, Primary motor cortex M1, forelimb area, Primary motor cortex M1, hindlimb area, Rostral superior parietal lobule, SMA - rostral part, Secondary somatosensory cortex, Ventolateral Nucleii of Thalamus, Ventral intraparietal area, Ventral posterior lateral nucleus (thalamus), Visual area V6A, area dentata (dentate gyrus), caudal lateral auditory (belt), superior parietal lobule (posterior dorsomedial parietal cortex above the intraparietal sulcus), ventral anterior nucleus (thalamus)

Targets:
Agranular frontal area 3 (= SMA-proper), Agranular frontal area 6 (= pre-SMA), Agranular frontal area 7 (= rostral dorsolateral premotor area), Area 23c, Area 24c (rostral part of the cingulate sulcus), Area 24d (rostral part of the cingulate sulcus), Area 31, Area X (thalamus), Caudal and medial superior parietal lobule, Central amygdaloid nucleus, lateral part, Centrum medianum thalami, Medial premotor area 6M, Nucleus medialis dorsalis thalami, Nucleus reticularis thalami, Nucleus ventralis lateralis thalami, pars caudalis, Nucleus ventralis lateralis thalami, pars medialis, Nucleus ventralis lateralis thalami, pars oralis, Parietal area PE (cingulate part), Primary motor area, Primary motor cortex M1, forelimb area,

SMA - rostral part, Transitional sensory area, Visual area V6A, area 24, ventral anterior nucleus (thalamus)

Region: Medial premotor area 6M (6M)

Super-regions:
Medial premotor area 6M < Area 6 < Cortical area FL < GM-CerebralCortex < Brain

Sources:
Agranular frontal area 2 (= caudal dorsolateral premotor area), Agranular frontal area 4 (= caudal ventrolateral premotor area), Agranular frontal area 5 (= rostral ventrolateral premotor area), Agranular frontal area 7 (= rostral dorsolateral premotor area), Area 12, Area 23, Area 23c, Area 24b, Area 24c (rostral part of the cingulate sulcus), Area 24d (rostral part of the cingulate sulcus), Area 6 (ventral part), Area 7, Area 7b, Area 8A, Area 8B, Area 9, Area X (thalamus), Central amygdaloid nucleus, lateral part, Centrum medianum thalami, Corpus geniculatum mediale, Cortical area 45, Cortical area 46, Dysgranular insular cortex, Fascia dentata hippocampi, Granular insular cortex, LGN layer 2, Lateral area 12, Lateral intraparietal area, Motor area 4c, Nucleus medialis dorsalis thalami, Nucleus medialis dorsalis thalami, pars densocellularis, Nucleus medialis dorsalis thalami, pars multiformis, Nucleus medialis dorsalis thalami, pars parvocellularis, Nucleus paracentralis thalami, Nucleus parafascicularis thalami, Nucleus pulvinaris thalami, Nucleus ventralis anterior thalami, pars parvocellularis, Nucleus ventralis lateralis thalami, pars caudalis, Nucleus ventralis lateralis thalami, pars medialis, Nucleus ventralis lateralis thalami, pars oralis, Nucleus ventralis lateralis thalami, pars postrema, Nucleus ventralis posterior inferior thalami, Nucleus ventralis posterior lateralis thalami, pars oralis, Nucleus ventralis posterior medialis thalami, Orbital area 12, Parietal area PG, medial part, Precentral opercular area, Premotor area 6Va, Premotor area 6Vb, Primary motor area, Primary motor cortex M1, forelimb area, Primary motor cortex M1, hindlimb area, Primary sensory area PC, Rostral superior parietal lobule, Secondary somatosensory cortex, Temporoparietal cortex, Ventral posterior lateral nucleus (thalamus), area 24, caudal lateral auditory (belt), orofacial representation in MI, superior parietal lobule (posterior dorsomedial parietal cortex above the intraparietal sulcus), ventral anterior nucleus (thalamus)

Descendant sources:
Agranular frontal area 2 (= caudal dorsolateral premotor area), Agranular frontal area 3 (= SMA-proper), Agranular frontal area 4 (= caudal ventrolateral premotor area), Agranular frontal area 5 (= rostral ventrolateral premotor area), Agranular frontal area 6 (= pre-SMA), Agranular frontal area 7 (= rostral dorsolateral premotor area), Anterior medial nucleus, Area 23, Area 23c, Area 24a, Area 24b, Area 24c (rostral part of the cingulate sulcus), Area 24d (rostral part of the cingulate sulcus), Area 31, Area 46 (dorsal rim of the principal sulcus), Area 46 (ventral rim of the principal sulcus), Area 6 (ventral part), Area 6 (ventral part), Area 8A, Area 8B, Area X (thalamus), Caudal and medial superior parietal lobule, Caudal inferior parietal lobule, Central amygdaloid nucleus, lateral part, Centrum medianum thalami, Cortical amygdaloid nucleus, Cortical area 46, Dorsal area 46, Dysgranular insular cortex, Granular insular cortex, Intralaminar nuclei of the thalamus, Medial intraparietal area, Midpart of the inferior parietal lobule, Nucleus centralis densocellularis thalami, Nucleus centralis latocellularis thalami, Nucleus centralis superior lateralis thalami, Nucleus limitans thalami, Nucleus medialis dorsalis thalami, Nucleus medialis dorsalis thalami, pars parvocellularis, Nucleus paracentralis thalami, Nucleus pulvinaris medialis thalami, Nucleus pulvinaris oralis thalami, Nucleus reuniens thalami, Nucleus suprageniculatus thalami, Nucleus ventralis anterior thalami, pars magnocellularis, Nucleus ventralis anterior thalami, pars parvocellularis, Nucleus ventralis lateralis thalami, pars caudalis, Nucleus ventralis lateralis thalami, pars medialis, Nucleus ventralis lateralis thalami, pars oralis, Nucleus ventralis lateralis thalami, pars postrema, Nucleus ventralis posterior lateralis thalami, pars oralis, Occipitoparietal area,

Parietal area PE (cingulate part), Parietal area PG, medial part, Premotor area 6Va, Premotor area 6Vb, Primary motor area, Primary motor cortex M1, forelimb area, Primary motor cortex M1, hindlimb area, Primary sensory area PC, Principal Sulcus, Rostral superior parietal lobule, SMA - caudal part, SMA - rostral part, Secondary somatosensory cortex, Superior temporal sulcus, Ventolateral Nucleii of Thalamus, Ventral area 46, Ventral posterior lateral nucleus (thalamus), Visual area V6A, area 24, orofacial representation in MI, ventral anterior nucleus (thalamus)

Targets:
Agranular frontal area 2 (= caudal dorsolateral premotor area), Agranular frontal area 7 (= rostral dorsolateral premotor area), Area 12, Area 23c, Area 24c (rostral part of the cingulate sulcus), Area 24d (rostral part of the cingulate sulcus), Area 3, Area 31, Area 6 (ventral part), Area 7b, Area 8A, Area 8B, Area 9, Cortical area 46, Fascia dentata hippocampi, Inferior parietal lobule (lateral posterior cortex below the intraparietal sulcus), Lateral intraparietal area, Medial area 9, Medial superior temporal area (dorsal), Nucleus ventralis lateralis thalami, pars oralis, Orbital area 12, Parietal area PE (cingulate part), Parietal area PG, medial part, Primary motor area, Primary motor cortex M1, forelimb area, Primary motor cortex M1, hindlimb area, Pro motor area, Transitional sensory area, area 24, orofacial representation in MI, superior parietal lobule (posterior dorsomedial parietal cortex above the intraparietal sulcus)

Descendant targets:
Agranular frontal area 2 (= caudal dorsolateral premotor area), Agranular frontal area 3 (= SMA-proper), Agranular frontal area 5 (= rostral ventrolateral premotor area), Agranular frontal area 6 (= pre-SMA), Agranular frontal area 7 (= rostral dorsolateral premotor area), Area 23, Area 23c, Area 24d (rostral part of the cingulate sulcus), Area 31, Area 46 (dorsal rim of the principal sulcus), Area 46 (ventral rim of the principal sulcus), Area 6 (ventral part), Area 8A, Caudal and medial superior parietal lobule, Central amygdaloid nucleus, lateral part, Centrum medianum thalami, Cortical area 46, Dorsal area 46, Fascia dentata hippocampi, Medial intraparietal area, Nucleus medialis dorsalis thalami, Nucleus pulvinaris thalami, Nucleus reticularis thalami, Nucleus ventralis anterior thalami, pars magnocellularis, Nucleus ventralis lateralis thalami, pars caudalis, Nucleus ventralis lateralis thalami, pars medialis, Nucleus ventralis lateralis thalami, pars oralis, Nucleus ventralis lateralis thalami, pars postrema, Nucleus ventralis posterior lateralis thalami, pars caudalis, Nucleus ventralis posterior lateralis thalami, pars oralis, Occipitoparietal area, Parietal area PE (cingulate part), Parietal area PG, medial part, Premotor area 6Va, Premotor area 6Vb, Primary motor area, Primary motor cortex M1, forelimb area, Primary motor cortex M1, hindlimb area, Principal Sulcus, SMA - caudal part, SMA - rostral part, Secondary somatosensory cortex, Ventral area 46, Ventral posterior lateral nucleus (thalamus), Visual area V6A, area 24, orofacial representation in MI, ventral anterior nucleus (thalamus)

Sub-regions:
Agranular frontal area 3 (= SMA-proper), Agranular frontal area 6 (= pre-SMA), Supplementary motor cortex M2, forelimb area, Supplementary motor cortex M2, hindlimb area

---
Region: Agranular frontal area 3 (= SMA-proper) (F3)

Super-regions:
Agranular frontal area 3 (= SMA-proper) < Medial premotor area 6M < Area 6 < Cortical area FL < GM-CerebralCortex < Brain

Sources:
Agranular frontal area 2 (= caudal dorsolateral premotor area), Agranular frontal area 4 (= caudal ventrolateral premotor area), Agranular frontal area 5 (= rostral ventrolateral premotor area), Agranular frontal area 6 (= pre-SMA), Agranular frontal area 7 (= rostral dorsolateral premotor area), Area 23, Area 24b, Area 24c (rostral part of the cingulate sulcus), Area 24d (rostral part of the cingulate sulcus), Area 6 (ventral part), Area 6 (ventral part), Area X (thalamus), Central amygdaloid nucleus, lateral part,

Centrum medianum thalami, Cortical amygdaloid nucleus, Dysgranular insular cortex, Granular insular cortex, Intralaminar nuclei of the thalamus, Medial intraparietal area, Nucleus centralis densocellularis thalami, Nucleus centralis latocellularis thalami, Nucleus centralis superior lateralis thalami, Nucleus limitans thalami, Nucleus medialis dorsalis thalami, Nucleus medialis dorsalis thalami, pars parvocellularis, Nucleus paracentralis thalami, Nucleus pulvinaris medialis thalami, Nucleus pulvinaris oralis thalami, Nucleus reuniens thalami, Nucleus suprageniculatus thalami, Nucleus ventralis anterior thalami, pars parvocellularis, Nucleus ventralis lateralis thalami, pars caudalis, Nucleus ventralis lateralis thalami, pars medialis, Nucleus ventralis lateralis thalami, pars oralis, Nucleus ventralis lateralis thalami, pars postrema, Nucleus ventralis posterior lateralis thalami, pars oralis, Primary motor area, Primary motor cortex M1, forelimb area, Primary motor cortex M1, hindlimb area, Primary sensory area PC, Rostral superior parietal lobule, Secondary somatosensory cortex, Ventolateral Nucleii of Thalamus, Ventral posterior lateral nucleus (thalamus), Visual area V6A, orofacial representation in MI, ventral anterior nucleus (thalamus)

Descendant sources:
Agranular frontal area 2 (= caudal dorsolateral premotor area), Agranular frontal area 7 (= rostral dorsolateral premotor area), Area 23, Area 31, Area 46 (dorsal rim of the principal sulcus), Area 46 (ventral rim of the principal sulcus), Area 8A, Caudal and medial superior parietal lobule, Dorsal area 46, Medial intraparietal area, Occipitoparietal area, Parietal area PE (cingulate part), Parietal area PG, medial part, Premotor area 6Va, Premotor area 6Vb, Primary motor area, Principal Sulcus, SMA - caudal part, SMA - rostral part, Ventral area 46, area 24

Targets:
Agranular frontal area 2 (= caudal dorsolateral premotor area), Agranular frontal area 5 (= rostral ventrolateral premotor area), Agranular frontal area 6 (= pre-SMA), Agranular frontal area 7 (= rostral dorsolateral premotor area), Area 6 (ventral part), Caudal and medial superior parietal lobule, Central amygdaloid nucleus, lateral part, Centrum medianum thalami, Nucleus medialis dorsalis thalami, Nucleus pulvinaris thalami, Nucleus reticularis thalami, Nucleus ventralis lateralis thalami, pars caudalis, Nucleus ventralis lateralis thalami, pars medialis, Nucleus ventralis lateralis thalami, pars oralis, Nucleus ventralis lateralis thalami, pars postrema, Nucleus ventralis posterior lateralis thalami, pars caudalis, Nucleus ventralis posterior lateralis thalami, pars oralis, Primary motor cortex M1, forelimb area, Primary motor cortex M1, hindlimb area, Ventral posterior lateral nucleus (thalamus), orofacial representation in MI, ventral anterior nucleus (thalamus)

Descendant targets:
Agranular frontal area 2 (= caudal dorsolateral premotor area), Agranular frontal area 7 (= rostral dorsolateral premotor area), Area 23, Area 31, Area 46 (dorsal rim of the principal sulcus), Area 46 (ventral rim of the principal sulcus), Area 8A, Caudal and medial superior parietal lobule, Dorsal area 46, Medial intraparietal area, Occipitoparietal area, Parietal area PE (cingulate part), Parietal area PG, medial part, Premotor area 6Va, Premotor area 6Vb, Primary motor area, Principal Sulcus, SMA - caudal part, SMA - rostral part, Secondary somatosensory cortex, Ventral area 46, area 24

Sub-regions:
SMA - caudal part, SMA - rostral part

Region: SMA - rostral part (SMAr)

Super-regions:
SMA - rostral part < Agranular frontal area 3 (= SMA-proper) < Medial premotor area 6M < Area 6 < Cortical area FL < GM-

CerebralCortex < Brain

Sources:
Agranular frontal area 2 (= caudal dorsolateral premotor area), Agranular frontal area 7 (= rostral dorsolateral premotor area), Area 23, Area 31, Area 46 (dorsal rim of the principal sulcus), Area 46 (ventral rim of the principal sulcus), Area 8A, Caudal and medial superior parietal lobule, Dorsal area 46, Medial intraparietal area, Occipitoparietal area, Parietal area PE (cingulate part), Parietal area PG, medial part, Premotor area 6Va, Premotor area 6Vb, Primary motor area, Principal Sulcus, SMA - caudal part, Ventral area 46, area 24

Targets:
Agranular frontal area 2 (= caudal dorsolateral premotor area), Agranular frontal area 7 (= rostral dorsolateral premotor area), Area 23, Area 31, Area 46 (dorsal rim of the principal sulcus), Area 46 (ventral rim of the principal sulcus), Area 8A, Caudal and medial superior parietal lobule, Dorsal area 46, Medial intraparietal area, Occipitoparietal area, Parietal area PE (cingulate part), Parietal area PG, medial part, Premotor area 6Va, Premotor area 6Vb, Primary motor area, Principal Sulcus, SMA - caudal part, Secondary somatosensory cortex, Ventral area 46, area 24

Region: SMA - caudal part (SMAc)

Super-regions:
SMA - caudal part < Agranular frontal area 3 (= SMA-proper) < Medial premotor area 6M < Area 6 < Cortical area FL < GM-CerebralCortex < Brain

Sources:
SMA - rostral part

Targets:
SMA - rostral part

Region: Supplementary motor cortex M2, hindlimb area (M2-HL)

Super-regions:
Supplementary motor cortex M2, hindlimb area < Medial premotor area 6M < Area 6 < Cortical area FL < GM-CerebralCortex < Brain

Sources:
Area 23c, Area 24b, Area 24c (rostral part of the cingulate sulcus), Primary motor area, Primary motor cortex M1, forelimb area, Primary motor cortex M1, hindlimb area

Targets:
Primary motor cortex M1, hindlimb area

Region: Supplementary motor cortex M2, forelimb area (M2-FL)

Super-regions:
Supplementary motor cortex M2, forelimb area < Medial premotor area 6M < Area 6 < Cortical area FL < GM-CerebralCortex < Brain

Sources:
Area 23c, Area 24b, Area 24c (rostral part of the cingulate sulcus), Primary motor area, Primary motor cortex M1, forelimb area

Targets:
Primary motor cortex M1, forelimb area

Region: Agranular frontal area 6 (= pre-SMA) (F6)

Super-regions:
Agranular frontal area 6 (= pre-SMA) < Medial premotor area 6M < Area 6 < Cortical area FL < GM-CerebralCortex < Brain

Sources:
Agranular frontal area 2 (= caudal dorsolateral premotor area), Agranular frontal area 3 (= SMA-proper), Agranular frontal area 4 (= caudal ventrolateral premotor area), Agranular frontal area 5 (= rostral ventrolateral premotor area), Agranular frontal area 7 (= rostral dorsolateral premotor area), Anterior medial nucleus, Area 23, Area 23c, Area 24a, Area 24b, Area 24c (rostral part of the cingulate sulcus), Area 24d (rostral part of the cingulate sulcus), Area 8B, Area X (thalamus), Caudal inferior parietal lobule, Central amygdaloid nucleus, lateral part, Centrum medianum thalami, Cortical area 46, Dorsal area 46, Dysgranular insular cortex, Granular insular cortex, Intralaminar nuclei of the thalamus, Midpart of the inferior parietal lobule, Nucleus centralis superior lateralis thalami, Nucleus limitans thalami, Nucleus medialis dorsalis thalami, Nucleus paracentralis thalami, Nucleus pulvinaris medialis thalami, Nucleus pulvinaris oralis thalami, Nucleus reuniens thalami, Nucleus supragenicularus thalami, Nucleus ventralis anterior thalami, pars magnocellularis, Nucleus ventralis anterior thalami, pars parvocellularis, Nucleus ventralis lateralis thalami, pars caudalis, Nucleus ventralis lateralis thalami, pars medialis, Nucleus ventralis lateralis thalami, pars oralis, Nucleus ventralis lateralis thalami, pars postrema, Nucleus ventralis posterior lateralis thalami, pars oralis, Superior temporal sulcus, Ventolateral Nucleii of Thalamus, Ventral area 46, Ventral posterior lateral nucleus (thalamus), Visual area V6A, ventral anterior nucleus (thalamus)

Targets:
Agranular frontal area 2 (= caudal dorsolateral premotor area), Agranular frontal area 3 (= SMA-proper), Agranular frontal area 7 (= rostral dorsolateral premotor area), Area 23c, Area 24d (rostral part of the cingulate sulcus), Area 31, Area 6 (ventral part), Caudal and medial superior parietal lobule, Cortical area 46, Fascia dentata hippocampi, Nucleus ventralis anterior thalami, pars magnocellularis, Nucleus ventralis lateralis thalami, pars oralis, Visual area V6A

Region: Primary motor area (M1)

Super-regions:
Primary motor area < Cortical area FL < GM-CerebralCortex < Brain

Sources:
Agranular frontal area 2 (= caudal dorsolateral premotor area), Agranular frontal area 4 (= caudal ventrolateral premotor area), Agranular frontal area 5 (= rostral ventrolateral premotor area), Agranular frontal area 7 (= rostral dorsolateral premotor area), Area 1, Area 23c, Area 24b, Area 24c (rostral part of the cingulate sulcus), Area 6, Area 6 (ventral part), Area 7b, Area X (thalamus), Central amygdaloid nucleus, lateral part, Centrum medianum thalami, LGN layer 2, Medial agranular insular cortex, Medial intraparietal area, Medial premotor area 6M, Nucleus medialis dorsalis thalami, Nucleus medialis dorsalis thalami, pars densocellularis, Nucleus medialis dorsalis thalami, pars parvocellularis, Nucleus paracentralis thalami, Nucleus parafascicularis thalami, Nucleus pulvinaris oralis thalami, Nucleus pulvinaris thalami, Nucleus ventralis anterior thalami, pars parvocellularis, Nucleus ventralis lateralis thalami, pars caudalis, Nucleus ventralis lateralis thalami, pars medialis, Nucleus ventralis lateralis thalami, pars oralis, Nucleus ventralis lateralis thalami, pars postrema, Nucleus ventralis posterior inferior thalami, Nucleus ventralis posterior lateralis thalami, pars caudalis, Nucleus ventralis posterior lateralis thalami, pars oralis, Nucleus ventralis posterior medialis thalami, Postcentral area 3a, Postcentral area 3b, Precentral opercular area, Premotor area 6Va, Primary sensory area PC, Primary sensory cortex, Rostral inferior parietal lobule, Rostral superior parietal lobule, SMA -

rostral part, Secondary somatosensory cortex, Ventolateral Nucleii of Thalamus, Ventral posterior lateral nucleus (thalamus), Visual area V6A, caudal lateral auditory (belt), superior parietal lobule (posterior dorsomedial parietal cortex above the intraparietal sulcus), superior temporal gyrus, ventral anterior nucleus (thalamus)

Descendant sources:
Agranular frontal area 2 (= caudal dorsolateral premotor area), Agranular frontal area 3 (= SMA-proper), Agranular frontal area 4 (= caudal ventrolateral premotor area), Agranular frontal area 5 (= rostral ventrolateral premotor area), Area 1, Area 12, Area 23c, Area 24b, Area 24c (rostral part of the cingulate sulcus), Area 24d (rostral part of the cingulate sulcus), Area 3, Area 6, Area 6 (ventral part), Area 7, Area 7b, Area X (thalamus), Central amygdaloid nucleus, lateral part, Centrum medianum thalami, Cingulate motor areas, LGN layer 2, Lateral intraparietal area, Laterodorsal nucleus (thalamus), Medial intraparietal area, Medial premotor area 6M, Nucleus centralis superior lateralis thalami, Nucleus limitans thalami, Nucleus medialis dorsalis thalami, Nucleus medialis dorsalis thalami, pars densocellularis, Nucleus paracentralis thalami, Nucleus pulvinaris medialis thalami, Nucleus pulvinaris oralis thalami, Nucleus ventralis anterior thalami, pars densocellularis, Nucleus ventralis lateralis thalami, pars caudalis, Nucleus ventralis lateralis thalami, pars medialis, Nucleus ventralis lateralis thalami, pars oralis, Nucleus ventralis posterior lateralis thalami, pars caudalis, Nucleus ventralis posterior lateralis thalami, pars oralis, Nucleus ventralis posterior medialis thalami, Orbitofrontal area 13, Postcentral area 3a, Postcentral area 3b, Precentral opercular area, Premotor area 6 (dorsal part), Primary motor cortex M1, forelimb area, Primary motor cortex M1, hindlimb area, Primary somatosensory cortex, Rostral inferior parietal lobule, Rostral parietal operculum, Rostral superior parietal lobule, Secondary somatosensory cortex, Supplementary motor cortex M2, forelimb area, Supplementary motor cortex M2, hindlimb area, Ventral posterior lateral nucleus (thalamus), area 24, superior parietal lobule (posterior dorsomedial parietal cortex above the intraparietal sulcus), ventral lateral nucleus (thalamus)

Targets:
Agranular frontal area 2 (= caudal dorsolateral premotor area), Agranular frontal area 3 (= SMA-proper), Agranular frontal area 4 (= caudal ventrolateral premotor area), Agranular frontal area 5 (= rostral ventrolateral premotor area), Agranular frontal area 7 (= rostral dorsolateral premotor area), Area 1, Area 23c, Area 24c (rostral part of the cingulate sulcus), Area 3, Area 31, Area 6, Area 6 (ventral part), Area 7, Area X (thalamus), Central amygdaloid nucleus, lateral part, Centrum medianum thalami, Inferior parietal lobule (lateral posterior cortex below the intraparietal sulcus), LGN layer 2, Medial premotor area 6M, Nucleus medialis dorsalis thalami, Nucleus reticularis thalami, Nucleus ventralis lateralis thalami, pars caudalis, Nucleus ventralis lateralis thalami, pars medialis, Nucleus ventralis lateralis thalami, pars oralis, Nucleus ventralis lateralis thalami, pars postrema, Nucleus ventralis posterior inferior thalami, Nucleus ventralis posterior lateralis thalami, pars caudalis, Nucleus ventralis posterior lateralis thalami, pars oralis, Nucleus ventralis posterior medialis thalami, Parietal area PE (cingulate part), Postcentral area 3a, Postcentral area 3b, Precentral opercular area, Primary sensory area PC, Primary somatosensory cortex, Rostral inferior parietal lobule, SMA - rostral part, Secondary somatosensory cortex, Supplementary motor cortex M2, forelimb area, Supplementary motor cortex M2, hindlimb area, Transitional sensory area, Ventral posterior lateral nucleus (thalamus), belt line of the sensory system according to CP99, belt line of the sensorymotor system according to CP99, superior parietal lobule (posterior dorsomedial parietal cortex above the intraparietal sulcus)

Descendant targets:
Agranular frontal area 2 (= caudal dorsolateral premotor area), Agranular frontal area 3 (= SMA-proper), Agranular frontal area 4 (= caudal ventrolateral premotor area), Agranular frontal area 5 (= rostral ventrolateral premotor area), Area 1, Area 24b, Area 3, Area 6, Area 6 (ventral part), Area X (thalamus), Central amygdaloid nucleus, lateral part, Centrum medianum thalami, LGN layer 2, Medial intraparietal area, Medial premotor area 6M, Nucleus medialis dorsalis thalami, Nucleus pulvinaris medialis thalami, Nucleus pulvinaris oralis thalami, Nucleus reticularis thalami, Nucleus ventralis anterior thalami, pars densocellularis, Nucleus ventralis lateralis thalami, pars caudalis, Nucleus ventralis lateralis thalami, pars oralis, Nucleus ventralis posterior lateralis thalami, pars caudalis, Nucleus ventralis posterior lateralis thalami, pars oralis, Precentral opercular area, Primary motor cortex M1, hindlimb

area, Primary somatosensory cortex, Rostral inferior parietal lobule, Rostral parietal operculum, Rostral superior parietal lobule, Secondary somatosensory cortex, Supplementary motor cortex M2, forelimb area, Supplementary motor cortex M2, hindlimb area, Ventral posterior area, Ventral posterior lateral nucleus (thalamus), area 24, body representation of MI as defined in KSI03, superior parietal lobule (posterior dorsomedial parietal cortex above the intraparietal sulcus), ventral lateral nucleus (thalamus)

Sub-regions:
Motor area 4a, Motor area 4b, Primary motor cortex M1, forelimb area, Primary motor cortex M1, hindlimb area, body representation of MI as defined in KSI03, orofacial representation in MI

Region: Primary motor cortex M1, forelimb area (M1-FL)

Super-regions:
Primary motor cortex M1, forelimb area < Primary motor area < Cortical area FL < GM-CerebralCortex < Brain

Sources:
Agranular frontal area 2 (= caudal dorsolateral premotor area), Agranular frontal area 3 (= SMA-proper), Agranular frontal area 4 (= caudal ventrolateral premotor area), Agranular frontal area 5 (= rostral ventrolateral premotor area), Area 1, Area 23c, Area 24b, Area 24c (rostral part of the cingulate sulcus), Area 24d (rostral part of the cingulate sulcus), Area 3, Area 6, Area 6 (ventral part), Area 7, Area X (thalamus), Central amygdaloid nucleus, lateral part, Centrum medianum thalami, LGN layer 2, Lateral intraparietal area, Laterodorsal nucleus (thalamus), Medial intraparietal area, Medial premotor area 6M, Nucleus centralis superior lateralis thalami, Nucleus limitans thalami, Nucleus medialis dorsalis thalami, Nucleus medialis dorsalis thalami, pars densocellularis, Nucleus paracentralis thalami, Nucleus pulvinaris oralis thalami, Nucleus ventralis anterior thalami, pars densocellularis, Nucleus ventralis lateralis thalami, pars caudalis, Nucleus ventralis lateralis thalami, pars medialis, Nucleus ventralis lateralis thalami, pars oralis, Nucleus ventralis posterior lateralis thalami, pars caudalis, Nucleus ventralis posterior lateralis thalami, pars oralis, Nucleus ventralis posterior medialis thalami, Postcentral area 3a, Postcentral area 3b, Precentral opercular area, Premotor area 6 (dorsal part), Primary somatosensory cortex, Rostral inferior parietal lobule, Rostral parietal operculum, Rostral superior parietal lobule, Secondary somatosensory cortex, Supplementary motor cortex M2, forelimb area, Ventral posterior lateral nucleus (thalamus), area 24, superior parietal lobule (posterior dorsomedial parietal cortex above the intraparietal sulcus), ventral lateral nucleus (thalamus)

Targets:
Agranular frontal area 2 (= caudal dorsolateral premotor area), Agranular frontal area 3 (= SMA-proper), Agranular frontal area 4 (= caudal ventrolateral premotor area), Agranular frontal area 5 (= rostral ventrolateral premotor area), Area 1, Area 24b, Area 3, Area 6, Area 6 (ventral part), Area X (thalamus), Central amygdaloid nucleus, lateral part, Centrum medianum thalami, LGN layer 2, Medial intraparietal area, Medial premotor area 6M, Nucleus medialis dorsalis thalami, Nucleus pulvinaris medialis thalami, Nucleus pulvinaris oralis thalami, Nucleus reticularis thalami, Nucleus ventralis anterior thalami, pars densocellularis, Nucleus ventralis lateralis thalami, pars caudalis, Nucleus ventralis lateralis thalami, pars oralis, Nucleus ventralis posterior lateralis thalami, pars caudalis, Nucleus ventralis posterior lateralis thalami, pars oralis, Precentral opercular area, Primary motor cortex M1, hindlimb area, Primary somatosensory cortex, Rostral inferior parietal lobule, Rostral parietal operculum, Rostral superior parietal lobule, Secondary somatosensory cortex, Supplementary motor cortex M2, forelimb area, Supplementary motor cortex M2, hindlimb area, Ventral posterior area, Ventral posterior lateral nucleus (thalamus), area 24, body representation of MI as defined in KSI03, ventral lateral nucleus (thalamus)

Region: orofacial representation in MI (MI-of)

Super-regions:
orofacial representation in MI < Primary motor area < Cortical area FL < GM-CerebralCortex < Brain

Sources:
Agranular frontal area 3 (= SMA-proper), Agranular frontal area 4 (= caudal ventrolateral premotor area), Agranular frontal area 5 (= rostral ventrolateral premotor area), Area 1, Area 12, Area 23c, Area 24c (rostral part of the cingulate sulcus), Area 24d (rostral part of the cingulate sulcus), Area 6, Area 6 (ventral part), Area 7b, Cingulate motor areas, LGN layer 2, Medial premotor area 6M, Orbitofrontal area 13, Postcentral area 3a, Rostral inferior parietal lobule, Secondary somatosensory cortex

Targets:
Agranular frontal area 3 (= SMA-proper), Agranular frontal area 4 (= caudal ventrolateral premotor area), Agranular frontal area 5 (= rostral ventrolateral premotor area), Medial premotor area 6M, Rostral inferior parietal lobule, Secondary somatosensory cortex

---
Region: Motor area 4b (4b)

Super-regions:
Motor area 4b < Primary motor area < Cortical area FL < GM-CerebralCortex < Brain

Sources:
area 24

Targets:
area 24

Region: Motor area 4a (4a)

Super-regions:
Motor area 4a < Primary motor area < Cortical area FL < GM-CerebralCortex < Brain

Sources:
area 24

Targets:
area 24

Region: body representation of MI as defined in KSI03 (MI-body)

Super-regions:
body representation of MI as defined in KSI03 < Primary motor area < Cortical area FL < GM-CerebralCortex < Brain

Sources:
Area 23c, Area 24b, Area 24c (rostral part of the cingulate sulcus), Area 6, Central amygdaloid nucleus, lateral part, Centrum medianum thalami, Nucleus medialis dorsalis thalami, Nucleus paracentralis thalami, Nucleus pulvinaris medialis thalami, Nucleus ventralis anterior thalami, pars densocellularis, Primary motor cortex M1, forelimb area, Primary motor cortex M1, hindlimb area, Ventral posterior lateral nucleus (thalamus), ventral lateral nucleus (thalamus)

Targets:
Centrum medianum thalami, Nucleus medialis dorsalis thalami, Nucleus pulvinaris medialis thalami, Nucleus reticularis thalami, Nucleus ventralis anterior thalami, pars densocellularis, Ventral posterior lateral nucleus (thalamus), ventral lateral nucleus (thalamus)

Region: Primary motor cortex M1, hindlimb area (M1-HL)

Super-regions:
Primary motor cortex M1, hindlimb area < Primary motor area < Cortical area FL < GM-CerebralCortex < Brain

Sources:
Agranular frontal area 3 (= SMA-proper), Area 23c, Area 24c (rostral part of the cingulate sulcus), Area 24d (rostral part of the cingulate sulcus), Area 6, Central amygdaloid nucleus, lateral part, Centrum medianum thalami, Medial premotor area 6M, Nucleus medialis dorsalis thalami, Nucleus ventralis anterior thalami, pars densocellularis, Primary motor cortex M1, forelimb area, Secondary somatosensory cortex, Supplementary motor cortex M2, hindlimb area, ventral lateral nucleus (thalamus)

Targets:
Agranular frontal area 2 (= caudal dorsolateral premotor area), Agranular frontal area 3 (= SMA-proper), Area 24b, Central amygdaloid nucleus, lateral part, Centrum medianum thalami, Medial premotor area 6M, Nucleus medialis dorsalis thalami, Nucleus pulvinaris medialis thalami, Nucleus reticularis thalami, Nucleus ventralis anterior thalami, pars densocellularis, Primary somatosensory cortex, Secondary somatosensory cortex, Supplementary motor cortex M2, hindlimb area, Ventral posterior lateral nucleus (thalamus), body representation of MI as defined in KSI03, superior parietal lobule (posterior dorsomedial parietal cortex above the intraparietal sulcus), ventral lateral nucleus (thalamus)

Region: ParietalLobe according to GM-Definition (Pl#6)

Super-regions:
ParietalLobe according to GM-Definition < GM-CerebralCortex < Brain

Descendant sources:
Agranular frontal area 2 (= caudal dorsolateral premotor area), Agranular frontal area 3 (= SMA-proper), Agranular frontal area 4 (= caudal ventrolateral premotor area), Agranular frontal area 5 (= rostral ventrolateral premotor area), Agranular frontal area 6 (= pre-SMA), Agranular frontal area 7 (= rostral dorsolateral premotor area), Agranular insula, Anterior inferotemporal area (dorsal), Anterior intraparietal area, Anterior medial nucleus, Area 1, Area 10, Area 11, Area 12, Area 20, Area 21, Area 23, Area 23a, Area 23b, Area 23c, Area 24a, Area 24b, Area 24c (rostral part of the cingulate sulcus), Area 24d (rostral part of the cingulate sulcus), Area 26, Area 29, Area 3, Area 31, Area 36, Area 6, Area 6 (ventral part), Area 6 (ventral part), Area 7, Area 7a, Area 7b, Area 8A, Area 8B, Area 9, Area X (thalamus), Caudal and medial superior parietal lobule, Caudal area 8A, Caudal auditory parakoniocortex, Caudal inferior parietal lobule, Caudal parietal operculum, Central amygdaloid nucleus, lateral part, Central inferotemporal area (ventral), Centrum medianum thalami, Claustrum, Cortical area 44, Cortical area 45, Cortical area 45A, Cortical area 45B, Cortical area 46, Cortical area 9\/46d, Cortical area OAa, Cortical area PGa, Cortical area TEm, Dorsal portion of area 8A, Dorsal prelunate gyrus, Dorsal visual area 3, Dysgranular insular cortex, Extrastriate area OA, Floor of superior temporal sulcus, Frontal eye field, Granular insular cortex, Gustatory cortex, Hypothalamus, Inferior parietal lobule (lateral posterior cortex below the intraparietal sulcus), Inferotemporal area TE, Insula, Insular proisocortex, Intraparietal sulcus associated area in the superior temporal sulcus, LGN internal magnocellular layer, LGN layer 2, Lateral Geniculate Nucleus, Lateral intraparietal area, Lateral intraparietal area (external part), Lateral intraparietal area (internal part), Laterodorsal nucleus (thalamus), Medial agranular insular cortex, Medial intraparietal area, Medial premotor area 6M, Medial superior temporal area, Medial superior temporal area (dorsal), Medial superior temporal area (posterior), Middle temporal area, Midpart of the inferior parietal lobule, Motor area 4c, Nucleus anterior ventralis thalami, Nucleus centralis superior lateralis thalami, Nucleus limitans thalami, Nucleus medialis dorsalis thalami, Nucleus medialis dorsalis thalami, pars densocellularis, Nucleus medialis dorsalis thalami, pars multiformis, Nucleus medialis dorsalis thalami, pars parvocellularis, Nucleus paracentralis thalami, Nucleus parafascicularis thalami, Nucleus paraventricularis thalami, pars anterior, Nucleus pulvinaris inferior thalami, central subdivision, Nucleus pulvinaris inferior thalami, pars medialis, Nucleus pulvinaris lateralis thalami, dorsal division, Nucleus pulvinaris medialis thalami, Nucleus pulvinaris medialis thalami, lateral division, Nucleus pulvinaris medialis thalami, medial division, Nucleus pulvinaris oralis thalami, Nucleus

pulvinaris thalami, Nucleus pulvinaris thalami, pars oralis, Nucleus reuniens thalami, Nucleus suprageniculatus thalami, Nucleus ventralis lateralis thalami, pars caudalis, Nucleus ventralis lateralis thalami, pars postrema, Nucleus ventralis posterior inferior thalami, Nucleus ventralis posterior lateralis thalami, pars caudalis, Nucleus ventralis posterior lateralis thalami, pars oralis, Nucleus ventralis posterior medialis thalami, Occipitoparietal area, Orbital prefrontal cortex, Orbitofrontal area 13, Parietal area PE (cingulate part), Parietal area PG, medial part, Peripheral part of area MT, Postcentral area 3a, Postcentral area 3b, Posterior inferotemporal area, Posterior intraparietal area, Precentral opercular area, Premotor area 6 (dorsal part), Premotor area 6Va, Premotor area 6Vb, Presubiculum, Primary motor area, Primary motor cortex M1, forelimb area, Primary motor cortex M1, hindlimb area, Primary sensory cortex, Primary somatosensory cortex, Principal Sulcus, Pro motor area, Retroinsular area, Retrosplenial area 30, Rostral inferior parietal lobule, Rostral superior parietal lobule, SMA - rostral part, Secondary somatosensory cortex, Superior temporal sulcus, Temporal area TAa, Temporal area TF, Temporal area TH, Temporal parietooccipital associated area in superior temporal sulcus, Temporal proisocortex, Temporoparietal asscociated area (caudal part), Temporoparietal associated area (intermediate part), Temporoparietal associated area (rostral part), Temporoparietal cortex, Temporopolar area TG, Transitional sensory area, V4 transitional area, Ventral area 46, Ventral intraparietal area, Ventral posterior lateral nucleus (thalamus), Ventral visual area 3, Ventroposterior superior nucleus thalami, Visual area 1, Visual area 2, Visual area 3, Visual area 3A, Visual area 4, Visual area 4 (dorsal part), Visual area 4 (ventral part), Visual area V6A, accessory basal nucleus (amygdala), magnocellular subdivision, area 24, belt line of the sensory system according to CP99, belt line of the sensorymotor system according to CP99, caudal lateral auditory (belt), face representation in SII as defined in DLRPK03, orofacial representation in MI, posterior lateral auditory area, rostroventral parietal area as defined in DLRPK03, superior parietal lobule (posterior dorsomedial parietal cortex above the intraparietal sulcus), superior temporal gyrus, temporal visual association area in the lower bank of the superior temporal sulcus, ventral anterior nucleus (thalamus)

Descendant targets:

Agranular frontal area 2 (= caudal dorsolateral premotor area), Agranular frontal area 3 (= SMA-proper), Agranular frontal area 4 (= caudal ventrolateral premotor area), Agranular frontal area 5 (= rostral ventrolateral premotor area), Agranular frontal area 6 (= pre-SMA), Agranular frontal area 7 (= rostral dorsolateral premotor area), Agranular insula, Anterior inferotemporal area (dorsal), Anterior intraparietal area, Area 1, Area 10, Area 11, Area 12, Area 20, Area 21, Area 23, Area 23b, Area 23c, Area 24a, Area 24b, Area 24c (rostral part of the cingulate sulcus), Area 26, Area 3, Area 31, Area 32, Area 35, Area 36, Area 6, Area 6 (ventral part), Area 7, Area 7a, Area 7b, Area 8, Area 8A, Area 8B, Area 9, Area X (thalamus), CA1 subfield of Ammon`s horn, Caudal and medial superior parietal lobule, Caudal area 8A, Caudal inferior parietal lobule, Caudal parietal operculum, Central amygdaloid nucleus, lateral part, Central inferotemporal area (ventral), Centrum medianum thalami, Claustrum, Corpus geniculatum mediale, Cortical area 45, Cortical area 45A, Cortical area 45B, Cortical area 46, Cortical area 9\/46d, Cortical area 9\/46v, Cortical area PGa, Dorsal portion of area 8A, Dorsal prelunate gyrus, Dorsal visual area 3, Dysgranular insular cortex, Extrastriate area OA, Floor of superior temporal sulcus, Frontal eye field, Granular insular cortex, Gustatory cortex, Inferior parietal lobule (lateral posterior cortex below the intraparietal sulcus), Inferotemporal area TE, Intralaminar nuclei of the thalamus, Intraparietal sulcus associated area in the superior temporal sulcus, LGN internal magnocellular layer, LGN layer 2, Lateral area 12, Lateral intraparietal area, Laterodorsal nucleus (thalamus), Medial area 12, Medial area 9, Medial intraparietal area, Medial premotor area 6M, Medial superior temporal area, Medial superior temporal area (dorsal), Medial superior temporal area (posterior), Middle temporal area, Midpart of the inferior parietal lobule, Nucleus caudatus, Nucleus caudatus; genu, Nucleus caudatus; tail, Nucleus centralis superior lateralis thalami, Nucleus limitans thalami, Nucleus medialis dorsalis thalami, Nucleus medialis dorsalis thalami, pars densocellularis, Nucleus paracentralis thalami, Nucleus paraventricularis thalami, pars anterior, Nucleus pulvinaris lateralis thalami, dorsal division, Nucleus pulvinaris medialis thalami, Nucleus pulvinaris medialis thalami, lateral division, Nucleus pulvinaris medialis thalami, medial division, Nucleus pulvinaris oralis thalami, Nucleus pulvinaris thalami, pars oralis, Nucleus reticularis thalami, Nucleus suprageniculatus thalami, Nucleus ventralis lateralis thalami, pars caudalis, Nucleus ventralis lateralis thalami, pars medialis, Nucleus ventralis lateralis thalami, pars oralis, Nucleus ventralis lateralis thalami, pars postrema, Nucleus ventralis posterior inferior thalami, Nucleus ventralis posterior lateralis thalami, pars caudalis, Nucleus ventralis posterior lateralis thalami, pars oralis, Nucleus ventralis

posterior medialis thalami, Orbital area 12, Orbital prefrontal cortex, Orbitofrontal area 13, Orbitofrontal area 13, lateral part, Parietal area PE (cingulate part), Parietal area PG, medial part, Peripheral part of area MT, Postcentral area 3a, Postcentral area 3b, Posterior Nucleii of Thalamus, Posterior inferotemporal area, Posterior inferotemporal area (dorsal), Posterior inferotemporal area (ventral), Posterior intraparietal area, Posteromedial agranular insular cortex, Premotor area 6 (dorsal part), Presubiculum, Primary motor area, Primary motor cortex M1, forelimb area, Primary motor cortex M1, hindlimb area, Primary somatosensory cortex, Principal Sulcus, Pro motor area, Putamen, Putamen; caudal, Putamen; rostral, Retroinsular area, Rostral area 12, Rostral inferior parietal lobule, Rostral parietal operculum, Rostral part of area 36, Rostral superior parietal lobule, SMA - rostral part, Secondary somatosensory cortex, Superior temporal sulcus, Temporal area TAa, Temporal area TF, Temporal area TF (lateral part), Temporal area TF (medial part), Temporal area TH, Temporal parietooccipital associated area in superior temporal sulcus, Temporoparietal asscociated area (caudal part), Temporoparietal associated area (intermediate part), Temporoparietal associated area (rostral part), Temporoparietal cortex, Transitional sensory area, V4 transitional area, Ventral area 46, Ventral intraparietal area, Ventral posterior lateral nucleus (thalamus), Ventral visual area 3, Ventroposterior superior nucleus thalami, Visual area 1, Visual area 2, Visual area 3, Visual area 3A, Visual area 4, Visual area V6A, area 24, belt line of the sensory system according to CP99, belt line of the sensorymotor system according to CP99, face representation in SII as defined in DLRPK03, orofacial representation in MI, posterior lateral auditory area, rostroventral parietal area as defined in DLRPK03, superior parietal lobule (posterior dorsomedial parietal cortex above the intraparietal sulcus), superior temporal gyrus, ventral lateral nucleus (thalamus)

Sub-regions:
Area 7, Cortex of the intraparietal sulcus, Dorsal parietal cortex (= SPL and precuneus), Primary somatosensory cortex, Secondary somatosensory cortex, belt line of the sensory system according to CP99, rostroventral parietal area as defined in DLRPK03

Region: Primary somatosensory cortex (S1)

Super-regions:
Primary somatosensory cortex < ParietalLobe according to GM-Definition < GM-CerebralCortex < Brain

Sources:
Area 7b, Granular insular cortex, Hypothalamus, Insula, Nucleus ventralis posterior lateralis thalami, pars caudalis, Primary motor area, Primary motor cortex M1, forelimb area, Primary motor cortex M1, hindlimb area, Primary sensory cortex, Retroinsular area, Rostral inferior parietal lobule, Secondary somatosensory cortex, Ventral posterior lateral nucleus (thalamus), superior parietal lobule (posterior dorsomedial parietal cortex above the intraparietal sulcus)

Descendant sources:
Agranular frontal area 4 (= caudal ventrolateral premotor area), Agranular frontal area 5 (= rostral ventrolateral premotor area), Anterior intraparietal area, Area 1, Area 23c, Area 24b, Area 24c (rostral part of the cingulate sulcus), Area 3, Area 6, Area 6 (ventral part), Area 7a, Area 7b, Caudal and medial superior parietal lobule, Caudal parietal operculum, Central amygdaloid nucleus, lateral part, Centrum medianum thalami, Cortical area 46, Dysgranular insular cortex, Granular insular cortex, Insula, Insular proisocortex, LGN layer 2, Lateral intraparietal area, Medial agranular insular cortex, Medial intraparietal area, Medial premotor area 6M, Nucleus medialis dorsalis thalami, Nucleus pulvinaris oralis thalami, Nucleus ventralis lateralis thalami, pars caudalis, Nucleus ventralis posterior lateralis thalami, pars caudalis, Nucleus ventralis posterior lateralis thalami, pars oralis, Nucleus ventralis posterior medialis thalami, Parietal area PE (cingulate part), Postcentral area 3a, Postcentral area 3b, Primary motor area, Primary motor cortex M1, forelimb area, Pro motor area, Retroinsular area, Rostral inferior parietal lobule, Rostral superior parietal lobule, Secondary somatosensory cortex, Ventral posterior lateral nucleus (thalamus), Ventroposterior superior nucleus thalami, belt line of the sensory system according to CP99, belt line of the sensorymotor system according to CP99, rostroventral parietal area as defined in DLRPK03, superior parietal lobule (posterior dorsomedial parietal cortex above the intraparietal sulcus)

Targets:
Agranular frontal area 4 (= caudal ventrolateral premotor area),

Agranular frontal area 5 (= rostral ventrolateral premotor area), Agranular frontal area 7 (= rostral dorsolateral premotor area), Area 11, Area 7b, Cortical area 46, Lateral area 12, Medial area 12, Orbital area 12, Orbitofrontal area 13, Orbitofrontal area 13, lateral part, Posteromedial agranular insular cortex, Primary motor cortex M1, forelimb area, Rostral area 12, Rostral inferior parietal lobule, Ventral area 46, superior parietal lobule (posterior dorsomedial parietal cortex above the intraparietal sulcus)

Descendant targets:
Agranular frontal area 3 (= SMA-proper), Agranular frontal area 4 (= caudal ventrolateral premotor area), Anterior intraparietal area, Area 1, Area 10, Area 23c, Area 3, Area 31, Area 6, Area 6 (ventral part), Area 7, Area 7b, Area 8A, Cortical area 46, Granular insular cortex, LGN layer 2, Medial area 12, Medial premotor area 6M, Nucleus paraventricularis thalami, pars anterior, Nucleus pulvinaris oralis thalami, Nucleus ventralis posterior lateralis thalami, pars caudalis, Nucleus ventralis posterior lateralis thalami, pars oralis, Nucleus ventralis posterior medialis thalami, Orbitofrontal area 13, lateral part, Parietal area PE (cingulate part), Postcentral area 3a, Postcentral area 3b, Posteromedial agranular insular cortex, Primary motor area, Primary motor cortex M1, forelimb area, Pro motor area, Retroinsular area, Rostral inferior parietal lobule, Secondary somatosensory cortex, Transitional sensory area, Ventral posterior lateral nucleus (thalamus), Ventroposterior superior nucleus thalami, belt line of the sensory system according to CP99, belt line of the sensorymotor system according to CP99, face representation in SII as defined in DLRPK03, orofacial representation in MI, rostroventral parietal area as defined in DLRPK03, superior parietal lobule (posterior dorsomedial parietal cortex above the intraparietal sulcus)

Sub-regions:
Area 3, Primary sensory area PC

Region: Primary sensory area PC (PC#1)

Super-regions:
Primary sensory area PC < Primary somatosensory cortex < ParietalLobe according to GM-Definition < GM-CerebralCortex < Brain

Sources:
Agranular frontal area 4 (= caudal ventrolateral premotor area), Central amygdaloid nucleus, lateral part, Centrum medianum thalami, Nucleus medialis dorsalis thalami, Nucleus pulvinaris oralis thalami, Nucleus ventralis lateralis thalami, pars caudalis, Nucleus ventralis posterior lateralis thalami, pars caudalis, Nucleus ventralis posterior medialis thalami, Primary motor area, Ventral posterior lateral nucleus (thalamus)

Descendant sources:
Agranular frontal area 5 (= rostral ventrolateral premotor area), Anterior intraparietal area, Area 1, Area 3, Area 6, Area 6 (ventral part), Area 7a, Area 7b, Centrum medianum thalami, Cortical area 46, Dysgranular insular cortex, Granular insular cortex, Insula, LGN layer 2, Lateral intraparietal area, Medial intraparietal area, Nucleus pulvinaris oralis thalami, Nucleus ventralis posterior lateralis thalami, pars caudalis, Nucleus ventralis posterior medialis thalami, Postcentral area 3a, Postcentral area 3b, Primary motor area, Primary motor cortex M1, forelimb area, Retroinsular area, Rostral inferior parietal lobule, Rostral superior parietal lobule, Secondary somatosensory cortex, Ventral posterior lateral nucleus (thalamus), Ventroposterior superior nucleus thalami, belt line of the sensorymotor system according to CP99, rostroventral parietal area as defined in DLRPK03, superior parietal lobule (posterior dorsomedial parietal cortex above the intraparietal sulcus)

Targets:
Agranular frontal area 3 (= SMA-proper), Agranular frontal area 4 (= caudal ventrolateral premotor area), Medial premotor area 6M, Primary motor area

Descendant targets:
Anterior intraparietal area, Area 1, Area 23c, Area 3, Area 31, Area 6, Area 6 (ventral part), Area 7, Area 7b, Area 8A, Cortical area 46, Granular insular cortex, LGN layer 2, Medial premotor area 6M, Nucleus

paraventricularis thalami, pars anterior, Nucleus pulvinaris oralis thalami, Nucleus ventralis posterior lateralis thalami, pars caudalis, Parietal area PE (cingulate part), Postcentral area 3a, Postcentral area 3b, Primary motor area, Primary motor cortex M1, forelimb area, Pro motor area, Retroinsular area, Rostral inferior parietal lobule, Secondary somatosensory cortex, Ventral posterior lateral nucleus (thalamus), Ventroposterior superior nucleus thalami, belt line of the sensorymotor system according to CP99, face representation in SII as defined in DLRPK03, orofacial representation in MI, rostroventral parietal area as defined in DLRPK03, superior parietal lobule (posterior dorsomedial parietal cortex above the intraparietal sulcus)

Sub-regions:
Area 1, LGN layer 2

Region: Area 1 (1#1)

Super-regions:
Area 1 < Primary sensory area PC < Primary somatosensory cortex < ParietalLobe according to GM-Definition < GM-CerebralCortex < Brain

Sources:
Agranular frontal area 5 (= rostral ventrolateral premotor area), Anterior intraparietal area, Area 6 (ventral part), Area 7b, Centrum medianum thalami, Granular insular cortex, Insula, LGN layer 2, Nucleus ventralis posterior lateralis thalami, pars caudalis, Nucleus ventralis posterior medialis thalami, Postcentral area 3a, Postcentral area 3b, Primary motor area, Primary motor cortex M1, forelimb area, Retroinsular area, Secondary somatosensory cortex, Ventral posterior lateral nucleus (thalamus), Ventroposterior superior nucleus thalami, belt line of the sensorymotor system according to CP99, rostroventral parietal area as defined in DLRPK03, superior parietal lobule (posterior dorsomedial parietal cortex above the intraparietal sulcus)

Targets:
Area 23c, Area 3, Area 31, Area 6 (ventral part), Area 7, Area 7b, Area 8A, Cortical area 46, Granular insular cortex, LGN layer 2, Nucleus paraventricularis thalami, pars anterior, Nucleus ventralis posterior lateralis thalami, pars caudalis, Parietal area PE (cingulate part), Postcentral area 3a, Postcentral area 3b, Primary motor area, Primary motor cortex M1, forelimb area, Pro motor area, Retroinsular area, Rostral inferior parietal lobule, Secondary somatosensory cortex, Ventral posterior lateral nucleus (thalamus), Ventroposterior superior nucleus thalami, belt line of the sensorymotor system according to CP99, face representation in SII as defined in DLRPK03, orofacial representation in MI, rostroventral parietal area as defined in DLRPK03, superior parietal lobule (posterior dorsomedial parietal cortex above the intraparietal sulcus)

Region: LGN layer 2 (2#1)

Super-regions:
LGN layer 2 < Primary sensory area PC < Primary somatosensory cortex < ParietalLobe according to GM-Definition < GM-CerebralCortex < Brain

Sources:
Agranular frontal area 5 (= rostral ventrolateral premotor area), Area 1, Area 3, Area 6, Area 6 (ventral part), Area 7a, Area 7b, Cortical area 46, Dysgranular insular cortex, Insula, Lateral intraparietal area, Medial intraparietal area, Nucleus pulvinaris oralis thalami, Nucleus ventralis posterior lateralis thalami, pars caudalis, Postcentral area 3a, Postcentral area 3b, Primary motor area, Primary motor cortex M1, forelimb area, Retroinsular area, Rostral inferior parietal lobule, Rostral superior parietal lobule, Secondary somatosensory cortex, Ventral posterior lateral nucleus (thalamus), Ventroposterior superior nucleus

thalami, belt line of the sensorymotor system according to CP99, superior parietal lobule (posterior dorsomedial parietal cortex above the intraparietal sulcus)

Targets:
Anterior intraparietal area, Area 1, Area 23c, Area 3, Area 31, Area 6, Area 6 (ventral part), Area 7, Area 7b, Cortical area 46, Granular insular cortex, Medial premotor area 6M, Nucleus pulvinaris oralis thalami, Nucleus ventralis posterior lateralis thalami, pars caudalis, Parietal area PE (cingulate part), Postcentral area 3a, Postcentral area 3b, Primary motor area, Primary motor cortex M1, forelimb area, Pro motor area, Retroinsular area, Rostral inferior parietal lobule, Secondary somatosensory cortex, Ventral posterior lateral nucleus (thalamus), Ventroposterior superior nucleus thalami, belt line of the sensorymotor system according to CP99, orofacial representation in MI, superior parietal lobule (posterior dorsomedial parietal cortex above the intraparietal sulcus)

Region: Area 3 (3#1)

Super-regions:
Area 3 < Primary somatosensory cortex < ParietalLobe according to GM-Definition < GM-CerebralCortex < Brain

Sources:
Area 1, Area 23c, Area 24c (rostral part of the cingulate sulcus), Caudal and medial superior parietal lobule, Caudal parietal operculum, Dysgranular insular cortex, Granular insular cortex, Insula, Insular proisocortex, LGN layer 2, Medial premotor area 6M, Parietal area PE (cingulate part), Primary motor area, Primary motor cortex M1, forelimb area, Pro motor area, Rostral superior parietal lobule, Secondary somatosensory cortex, belt line of the sensory system according to CP99, belt line of the sensorymotor system according to CP99

Descendant sources:
Agranular frontal area 5 (= rostral ventrolateral premotor area), Area 1, Area 24b, Area 24c (rostral part of the cingulate sulcus), Area 6 (ventral part), Central amygdaloid nucleus, lateral part, Centrum medianum thalami, LGN layer 2, Medial agranular insular cortex, Nucleus pulvinaris oralis thalami, Nucleus ventralis posterior lateralis thalami, pars caudalis, Nucleus ventralis posterior lateralis thalami, pars oralis, Nucleus ventralis posterior medialis thalami, Postcentral area 3a, Postcentral area 3b, Primary motor area, Secondary somatosensory cortex, Ventral posterior lateral nucleus (thalamus), Ventroposterior superior nucleus thalami, rostroventral parietal area as defined in DLRPK03

Targets:
Area 23c, Area 31, LGN layer 2, Parietal area PE (cingulate part), Primary motor cortex M1, forelimb area, Pro motor area, belt line of the sensory system according to CP99, belt line of the sensorymotor system according to CP99

Descendant targets:
Area 1, Area 10, Area 23c, Area 6 (ventral part), Area 7, Area 8A, Granular insular cortex, LGN layer 2, Medial area 12, Nucleus paraventricularis thalami, pars anterior, Nucleus ventralis posterior lateralis thalami, pars caudalis, Nucleus ventralis posterior lateralis thalami, pars oralis, Nucleus ventralis posterior medialis thalami, Orbitofrontal area 13, lateral part, Parietal area PE (cingulate part), Postcentral area 3a, Postcentral area 3b, Posteromedial agranular insular cortex, Primary motor area, Primary motor cortex M1, forelimb area, Retroinsular area, Secondary somatosensory cortex, Transitional sensory area, face representation in SII as defined in DLRPK03, orofacial representation in MI, rostroventral parietal area as defined in DLRPK03, superior parietal lobule (posterior dorsomedial parietal cortex above the intraparietal sulcus)

Sub-regions:
Postcentral area 3a, Postcentral area 3b

Region: Postcentral area 3b (3b)

Super-regions:
Postcentral area 3b < Area 3 < Primary somatosensory cortex < ParietalLobe according to GM-Definition < GM-CerebralCortex < Brain

Sources:
Agranular frontal area 5 (= rostral ventrolateral premotor area), Area 1, LGN layer 2, Nucleus pulvinaris oralis thalami, Nucleus ventralis posterior lateralis thalami, pars caudalis, Nucleus ventralis posterior medialis thalami, Postcentral area 3a, Primary motor area, Secondary somatosensory cortex, Ventral posterior lateral nucleus (thalamus), rostroventral parietal area as defined in DLRPK03

Targets:
Area 1, Area 23c, Granular insular cortex, LGN layer 2, Medial area 12, Nucleus paraventricularis thalami, pars anterior, Nucleus ventralis posterior lateralis thalami, pars caudalis, Nucleus ventralis posterior lateralis thalami, pars oralis, Nucleus ventralis posterior medialis thalami, Orbitofrontal area 13, lateral part, Parietal area PE (cingulate part), Postcentral area 3a, Posteromedial agranular insular cortex, Primary motor area, Primary motor cortex M1, forelimb area, Retroinsular area, Secondary somatosensory cortex, Transitional sensory area, face representation in SII as defined in DLRPK03, rostroventral parietal area as defined in DLRPK03, superior parietal lobule (posterior dorsomedial parietal cortex above the intraparietal sulcus)

Region: Postcentral area 3a (3a)

Super-regions:
Postcentral area 3a < Area 3 < Primary somatosensory cortex < ParietalLobe according to GM-Definition < GM-CerebralCortex < Brain

Sources:
Agranular frontal area 5 (= rostral ventrolateral premotor area), Area 1, Area 24b, Area 24c (rostral part of the cingulate sulcus), Area 6 (ventral part), Central amygdaloid nucleus, lateral part, Centrum medianum thalami, LGN layer 2, Medial agranular insular cortex, Nucleus pulvinaris oralis thalami, Nucleus ventralis posterior lateralis thalami, pars caudalis, Nucleus ventralis posterior lateralis thalami, pars oralis, Nucleus ventralis posterior medialis thalami, Postcentral area 3b, Primary motor area, Secondary somatosensory cortex, Ventral posterior lateral nucleus (thalamus), Ventroposterior superior nucleus thalami

Targets:
Area 1, Area 10, Area 23c, Area 6 (ventral part), Area 7, Area 8A, LGN layer 2, Nucleus ventralis posterior lateralis thalami, pars caudalis, Parietal area PE (cingulate part), Postcentral area 3b, Primary motor area, Primary motor cortex M1, forelimb area, Secondary somatosensory cortex, Transitional sensory area, orofacial representation in MI, rostroventral parietal area as defined in DLRPK03, superior parietal lobule (posterior dorsomedial parietal cortex above the intraparietal sulcus)

Region: Secondary somatosensory cortex (S2)

Super-regions:
Secondary somatosensory cortex < ParietalLobe according to GM-Definition < GM-CerebralCortex < Brain

Sources:
Agranular frontal area 4 (= caudal ventrolateral premotor area), Agranular frontal area 5 (= rostral ventrolateral premotor area), Area 1, Area 24d (rostral part of the cingulate sulcus), Area 6, Area 6 (ventral part), Area 7b, Caudal parietal operculum, Cortical area 44, Cortical area 46, Dysgranular insular cortex,

Granular insular cortex, Gustatory cortex, Hypothalamus, Insula, LGN layer 2, Lateral intraparietal area, Medial intraparietal area, Nucleus ventralis posterior lateralis thalami, pars caudalis, Nucleus ventralis posterior medialis thalami, Orbital prefrontal cortex, Postcentral area 3a, Postcentral area 3b, Primary motor area, Primary motor cortex M1, forelimb area, Primary motor cortex M1, hindlimb area, Primary sensory cortex, Pro motor area, Retroinsular area, Rostral inferior parietal lobule, SMA - rostral part, area 24, belt line of the sensorymotor system according to CP99, orofacial representation in MI, rostroventral parietal area as defined in DLRPK03

Descendant sources:
Area 1, Area 7b, Postcentral area 3b, accessory basal nucleus (amygdala), magnocellular subdivision, rostroventral parietal area as defined in DLRPK03

Targets:
Agranular frontal area 2 (= caudal dorsolateral premotor area), Agranular frontal area 3 (= SMA-proper), Agranular frontal area 4 (= caudal ventrolateral premotor area), Agranular frontal area 5 (= rostral ventrolateral premotor area), Area 1, Area 11, Area 23c, Area 3, Area 36, Area 6, Area 6 (ventral part), Area 7b, Cortical area 46, Dysgranular insular cortex, Granular insular cortex, Inferior parietal lobule (lateral posterior cortex below the intraparietal sulcus), LGN layer 2, Lateral area 12, Medial area 12, Medial premotor area 6M, Nucleus pulvinaris oralis thalami, Nucleus ventralis posterior inferior thalami, Nucleus ventralis posterior lateralis thalami, pars caudalis, Orbital area 12, Orbital prefrontal cortex, Parietal area PE (cingulate part), Postcentral area 3a, Postcentral area 3b, Posterior Nucleii of Thalamus, Primary motor area, Primary motor cortex M1, forelimb area, Primary motor cortex M1, hindlimb area, Primary somatosensory cortex, Pro motor area, Retroinsular area, Rostral inferior parietal lobule, Rostral part of area 36, Temporal area TF (lateral part), Temporal area TF (medial part), Transitional sensory area, Ventral area 46, area 24, belt line of the sensorymotor system according to CP99, orofacial representation in MI, rostroventral parietal area as defined in DLRPK03, superior parietal lobule (posterior dorsomedial parietal cortex above the intraparietal sulcus)

Descendant targets:
orofacial representation in MI, rostroventral parietal area as defined in DLRPK03

Sub-regions:
Cingulate motor areas, face representation in SII as defined in DLRPK03

Region: face representation in SII as defined in DLRPK03 (SII-f)

Super-regions:
face representation in SII as defined in DLRPK03 < Secondary somatosensory cortex < ParietalLobe according to GM-Definition < GM-CerebralCortex < Brain

Sources:
Area 1, Area 7b, Postcentral area 3b, rostroventral parietal area as defined in DLRPK03

Targets:
rostroventral parietal area as defined in DLRPK03

Region: Cingulate motor areas (CMA#2)

Super-regions:
Cingulate motor areas < Secondary somatosensory cortex < ParietalLobe according to GM-Definition < GM-CerebralCortex < Brain

Sources:
accessory basal nucleus (amygdala), magnocellular subdivision

Targets:
orofacial representation in MI

Region: belt line of the sensory system according to CP99 (belt_s)

Super-regions:
belt line of the sensory system according to CP99 < ParietalLobe according to GM-Definition < GM-CerebralCortex < Brain

Sources:
Agranular insula, Area 12, Area 3, Area 6, Dysgranular insular cortex, Gustatory cortex, Orbitofrontal area 13, Primary motor area, Pro motor area

Targets:
Area 3, Area 6, Gustatory cortex, Pro motor area

Region: rostroventral parietal area as defined in DLRPK03 (PR#4)

Super-regions:
rostroventral parietal area as defined in DLRPK03 < ParietalLobe according to GM-Definition < GM-CerebralCortex < Brain

Sources:
Agranular frontal area 5 (= rostral ventrolateral premotor area), Area 1, Area 6, Area 7, Area 7b, Frontal eye field, Postcentral area 3a, Postcentral area 3b, Secondary somatosensory cortex, face representation in SII as defined in DLRPK03, superior parietal lobule (posterior dorsomedial parietal cortex above the intraparietal sulcus)

Targets:
Area 1, Area 6, Area 7b, Frontal eye field, Postcentral area 3b, Secondary somatosensory cortex, face representation in SII as defined in DLRPK03, superior parietal lobule (posterior dorsomedial parietal cortex above the intraparietal sulcus)

Region: Area 7 (7#1)

Super-regions:
Area 7 < ParietalLobe according to GM-Definition < GM-CerebralCortex < Brain

Sources:
Area 1, Area 23, Area 24a, Area 24b, Area 24d (rostral part of the cingulate sulcus), Dysgranular insular cortex, Granular insular cortex, Hypothalamus, LGN layer 2, Medial intraparietal area, Medial superior temporal area (dorsal), Middle temporal area, Motor area 4c, Postcentral area 3a, Premotor area 6 (dorsal part), Premotor area 6Va, Primary motor area, Primary sensory cortex, Retroinsular area, Temporoparietal asscociated area (caudal part), Temporoparietal associated area (intermediate part), Temporoparietal associated area (rostral part), Ventral area 46, Ventral intraparietal area, caudal lateral auditory (belt), posterior lateral auditory area, superior parietal lobule (posterior dorsomedial parietal cortex above the intraparietal sulcus)

Descendant sources:
Agranular frontal area 4 (= caudal ventrolateral premotor area), Agranular frontal area 5 (= rostral ventrolateral premotor area), Agranular insula, Anterior inferotemporal area (dorsal), Anterior medial nucleus, Area 1, Area 11, Area 12, Area 20, Area 21, Area 23, Area 23c, Area 24a, Area 24b, Area 24c (rostral part of the cingulate sulcus), Area 24d (rostral part of the cingulate sulcus), Area 26, Area 29, Area 6, Area 6 (ventral part), Area 6 (ventral part), Area 7a, Area 7b, Area 8A, Area 8B, Caudal and medial superior parietal lobule, Caudal area 8A, Caudal parietal operculum, Central amygdaloid nucleus, lateral part, Centrum medianum thalami, Claustrum, Cortical area 45, Cortical area 45A, Cortical area 45B, Cortical area 46, Cortical area OAa, Cortical area PGa, Cortical area TEm, Dorsal prelunate gyrus, Dysgranular insular cortex, Extrastriate area OA, Floor of superior temporal sulcus, Frontal eye field, Granular insular cortex, Hypothalamus, Insula, Intraparietal sulcus associated area in the superior temporal sulcus, LGN internal magnocellular layer, LGN layer 2, Lateral Geniculate Nucleus, Lateral intraparietal area, Lateral intraparietal area (external part), Lateral intraparietal area (internal part), Laterodorsal nucleus (thalamus), Medial intraparietal area, Medial premotor area 6M, Medial superior temporal area, Medial superior temporal area

(dorsal), Middle temporal area, Motor area 4c, Nucleus anterior ventralis thalami, Nucleus centralis superior lateralis thalami, Nucleus limitans thalami, Nucleus medialis dorsalis thalami, pars densocellularis, Nucleus medialis dorsalis thalami, pars multiformis, Nucleus medialis dorsalis thalami, pars parvocellularis, Nucleus paracentralis thalami, Nucleus parafascicularis thalami, Nucleus pulvinaris inferior thalami, central subdivision, Nucleus pulvinaris inferior thalami, pars medialis, Nucleus pulvinaris lateralis thalami, dorsal division, Nucleus pulvinaris medialis thalami, Nucleus pulvinaris medialis thalami, lateral division, Nucleus pulvinaris medialis thalami, medial division, Nucleus pulvinaris oralis thalami, Nucleus pulvinaris thalami, Nucleus pulvinaris thalami, pars oralis, Nucleus suprageniculatus thalami, Nucleus ventralis lateralis thalami, pars caudalis, Nucleus ventralis lateralis thalami, pars postrema, Nucleus ventralis posterior inferior thalami, Nucleus ventralis posterior lateralis thalami, pars caudalis, Nucleus ventralis posterior medialis thalami, Parietal area PE (cingulate part), Parietal area PG, medial part, Peripheral part of area MT, Posterior inferotemporal area, Precentral opercular area, Premotor area 6 (dorsal part), Premotor area 6Va, Premotor area 6Vb, Primary motor area, Primary motor cortex M1, forelimb area, Primary sensory cortex, Primary somatosensory cortex, Principal Sulcus, Pro motor area, Retroinsular area, Retrosplenial area 30, Rostral inferior parietal lobule, Rostral superior parietal lobule, SMA - rostral part, Secondary somatosensory cortex, Superior temporal sulcus, Temporal area TAa, Temporal area TF, Temporal area TH, Temporal parietooccipital associated area in superior temporal sulcus, Temporal proisocortex, Temporoparietal asscociated area (caudal part), Temporoparietal associated area (intermediate part), Temporoparietal associated area (rostral part), Temporoparietal cortex, Temporopolar area TG, Ventral area 46, Ventral intraparietal area, Ventral posterior lateral nucleus (thalamus), Visual area 2, Visual area 3, Visual area 4, Visual area 4 (dorsal part), Visual area 4 (ventral part), Visual area V6A, area 24, belt line of the sensorymotor system according to CP99, caudal lateral auditory (belt), orofacial representation in MI, posterior lateral auditory area, rostroventral parietal area as defined in DLRPK03, superior parietal lobule (posterior dorsomedial parietal cortex above the intraparietal sulcus), superior temporal gyrus, temporal visual association area in the lower bank of the superior temporal sulcus, ventral anterior nucleus (thalamus)

Targets:

Area 10, Area 23, Area 24b, Area 24c (rostral part of the cingulate sulcus), Area 6, Area 8, Area 9, Caudal and medial superior parietal lobule, Central amygdaloid nucleus, lateral part, Cortical area PGa, Intraparietal sulcus associated area in the superior temporal sulcus, Laterodorsal nucleus (thalamus), Medial intraparietal area, Medial premotor area 6M, Nucleus caudatus, Nucleus caudatus; genu, Nucleus centralis superior lateralis thalami, Nucleus pulvinaris medialis thalami, Nucleus pulvinaris oralis thalami, Nucleus ventralis lateralis thalami, pars postrema, Parietal area PE (cingulate part), Parietal area PG, medial part, Primary motor cortex M1, forelimb area, Putamen, Putamen; caudal, Putamen; rostral, Rostral superior parietal lobule, Temporal area TAa, Temporal parietooccipital associated area in superior temporal sulcus, Temporoparietal cortex, Ventral intraparietal area, Ventral posterior lateral nucleus (thalamus), area 24, posterior lateral auditory area, rostroventral parietal area as defined in DLRPK03, ventral lateral nucleus (thalamus)

Descendant targets:

Agranular frontal area 2 (= caudal dorsolateral premotor area), Agranular frontal area 4 (= caudal ventrolateral premotor area), Agranular frontal area 5 (= rostral ventrolateral premotor area), Agranular frontal area 6 (= pre-SMA), Agranular frontal area 7 (= rostral dorsolateral premotor area), Agranular insula, Anterior inferotemporal area (dorsal), Area 1, Area 11, Area 12, Area 21, Area 23, Area 23b, Area 23c, Area 24a, Area 24c (rostral part of the cingulate sulcus), Area 3, Area 31, Area 32, Area 35, Area 36, Area 6, Area 6 (ventral part), Area 7a, Area 7b, Area 8, Area 8A, Area 8B, Area 9, Area X (thalamus), CA1 subfield of Ammon`s horn, Caudal and medial superior parietal lobule, Central amygdaloid nucleus, lateral part, Centrum medianum thalami, Claustrum, Corpus geniculatum mediale, Cortical area 45, Cortical area 45A, Cortical area 46, Cortical area 9\/46d, Cortical area 9\/46v, Cortical area PGa, Dorsal portion of area 8A, Dorsal prelunate gyrus, Dysgranular insular cortex, Extrastriate area OA, Floor of superior temporal sulcus, Frontal eye field, Granular insular cortex, Gustatory cortex, Intraparietal sulcus associated area in the superior temporal sulcus, LGN internal magnocellular layer, LGN layer 2, Lateral area 12, Lateral intraparietal area, Medial area 12, Medial premotor area 6M, Medial superior

temporal area, Medial superior temporal area (dorsal), Middle temporal area, Midpart of the inferior parietal lobule, Nucleus caudatus, Nucleus caudatus; genu, Nucleus caudatus; tail, Nucleus centralis superior lateralis thalami, Nucleus limitans thalami, Nucleus medialis dorsalis thalami, Nucleus medialis dorsalis thalami, pars densocellularis, Nucleus paracentralis thalami, Nucleus pulvinaris lateralis thalami, dorsal division, Nucleus pulvinaris medialis thalami, Nucleus pulvinaris medialis thalami, lateral division, Nucleus pulvinaris medialis thalami, medial division, Nucleus pulvinaris oralis thalami, Nucleus pulvinaris thalami, pars oralis, Nucleus reticularis thalami, Nucleus suprageniculatus thalami, Nucleus ventralis lateralis thalami, pars caudalis, Nucleus ventralis lateralis thalami, pars medialis, Nucleus ventralis lateralis thalami, pars oralis, Nucleus ventralis posterior inferior thalami, Nucleus ventralis posterior lateralis thalami, pars caudalis, Nucleus ventralis posterior medialis thalami, Orbital area 12, Parietal area PE (cingulate part), Parietal area PG, medial part, Peripheral part of area MT, Posterior inferotemporal area, Premotor area 6 (dorsal part), Presubiculum, Primary motor area, Primary motor cortex M1, forelimb area, Primary somatosensory cortex, Principal Sulcus, Pro motor area, Putamen, Putamen; caudal, Putamen; rostral, Retroinsular area, Rostral parietal operculum, SMA - rostral part, Secondary somatosensory cortex, Superior temporal sulcus, Temporal area TAa, Temporal area TF, Temporal area TH, Temporal parietooccipital associated area in superior temporal sulcus, Temporoparietal asscociated area (caudal part), Temporoparietal associated area (intermediate part), Temporoparietal associated area (rostral part), Temporoparietal cortex, Transitional sensory area, V4 transitional area, Ventral area 46, Ventral intraparietal area, Ventral posterior lateral nucleus (thalamus), Visual area 4, Visual area V6A, area 24, belt line of the sensorymotor system according to CP99, face representation in SII as defined in DLRPK03, orofacial representation in MI, posterior lateral auditory area, rostroventral parietal area as defined in DLRPK03, superior parietal lobule (posterior dorsomedial parietal cortex above the intraparietal sulcus), superior temporal gyrus

Sub-regions:
Caudal parietal operculum, Inferior parietal lobule (lateral posterior cortex below the intraparietal sulcus), Posterior parietal area, Rostral parietal operculum

---
Region: Rostral parietal operculum (PFop)

Super-regions:
Rostral parietal operculum < Area 7 < ParietalLobe according to GM-Definition < GM-CerebralCortex < Brain

Sources:
Agranular frontal area 5 (= rostral ventrolateral premotor area), Area 6 (ventral part), Primary motor cortex M1, forelimb area, Rostral inferior parietal lobule

Targets:
Agranular frontal area 5 (= rostral ventrolateral premotor area), Area 6 (ventral part), Primary motor cortex M1, forelimb area, Putamen, Putamen; caudal

---
Region: Posterior parietal area (PP)

Super-regions:
Posterior parietal area < Area 7 < ParietalLobe according to GM-Definition < GM-CerebralCortex < Brain

Sources:
Posterior inferotemporal area

Targets:
Agranular frontal area 2 (= caudal dorsolateral premotor area), Posterior inferotemporal area

---
Region: Caudal parietal operculum (PGop)

Super-regions:

Caudal parietal operculum < Area 7 < ParietalLobe according to GM-Definition < GM-CerebralCortex < Brain

Sources:
Agranular frontal area 5 (= rostral ventrolateral premotor area), Caudal and medial superior parietal lobule, Cortical area 46, Medial intraparietal area, Rostral superior parietal lobule

Targets:
Area 23c, Area 3, Area 31, Area 6 (ventral part), Area 7b, Dorsal portion of area 8A, Parietal area PE (cingulate part), Secondary somatosensory cortex

---
Region: Inferior parietal lobule (lateral posterior cortex below the intraparietal sulcus) (IPL)

Super-regions:
Inferior parietal lobule (lateral posterior cortex below the intraparietal sulcus) < Area 7 < ParietalLobe according to GM-Definition < GM-CerebralCortex < Brain

Sources:
Anterior inferotemporal area (dorsal), Area 20, Area 23, Area 24a, Area 24b, Area 24d (rostral part of the cingulate sulcus), Area 29, Caudal area 8A, Cortical area 45, Cortical area 46, Cortical area OAa, Cortical area PGa, Floor of superior temporal sulcus, Medial intraparietal area, Medial premotor area 6M, Motor area 4c, Parietal area PG, medial part, Premotor area 6 (dorsal part), Premotor area 6Va, Primary motor area, Retrosplenial area 30, Secondary somatosensory cortex, Temporal area TAa, Temporoparietal asscociated area (caudal part), Temporoparietal associated area (rostral part), Ventral area 46, Ventral intraparietal area, Visual area 4 (ventral part)

Descendant sources:
Agranular frontal area 4 (= caudal ventrolateral premotor area), Agranular frontal area 5 (= rostral ventrolateral premotor area), Agranular insula, Anterior inferotemporal area (dorsal), Anterior medial nucleus, Area 1, Area 11, Area 12, Area 21, Area 23, Area 23c, Area 24a, Area 24b, Area 24c (rostral part of the cingulate sulcus), Area 26, Area 6, Area 6 (ventral part), Area 6 (ventral part), Area 7a, Area 7b, Area 8A, Area 8B, Caudal and medial superior parietal lobule, Caudal area 8A, Caudal parietal operculum, Central amygdaloid nucleus, lateral part, Centrum medianum thalami, Claustrum, Cortical area 45, Cortical area 45A, Cortical area 45B, Cortical area 46, Cortical area OAa, Cortical area PGa, Cortical area TEm, Dorsal prelunate gyrus, Dysgranular insular cortex, Extrastriate area OA, Floor of superior temporal sulcus, Frontal eye field, Granular insular cortex, Hypothalamus, Insula, Intraparietal sulcus associated area in the superior temporal sulcus, LGN internal magnocellular layer, LGN layer 2, Lateral Geniculate Nucleus, Lateral intraparietal area, Lateral intraparietal area (external part), Lateral intraparietal area (internal part), Laterodorsal nucleus (thalamus), Medial intraparietal area, Medial premotor area 6M, Medial superior temporal area, Medial superior temporal area (dorsal), Middle temporal area, Motor area 4c, Nucleus anterior ventralis thalami, Nucleus centralis superior lateralis thalami, Nucleus limitans thalami, Nucleus medialis dorsalis thalami, pars densocellularis, Nucleus medialis dorsalis thalami, pars multiformis, Nucleus medialis dorsalis thalami, pars parvocellularis, Nucleus paracentralis thalami, Nucleus parafascicularis thalami, Nucleus pulvinaris inferior thalami, central subdivision, Nucleus pulvinaris inferior thalami, pars medialis, Nucleus pulvinaris lateralis thalami, dorsal division, Nucleus pulvinaris medialis thalami, Nucleus pulvinaris medialis thalami, lateral division, Nucleus pulvinaris medialis thalami, medial division, Nucleus pulvinaris oralis thalami, Nucleus pulvinaris thalami, Nucleus pulvinaris thalami, pars oralis, Nucleus suprageniculatus thalami, Nucleus ventralis lateralis thalami, pars caudalis, Nucleus ventralis lateralis thalami, pars postrema, Nucleus ventralis posterior inferior thalami, Nucleus ventralis posterior lateralis thalami, pars caudalis, Nucleus ventralis posterior medialis thalami, Parietal area PE (cingulate part), Parietal area PG, medial part, Peripheral part of area MT, Precentral opercular area,

Premotor area 6 (dorsal part), Premotor area 6Va, Premotor area 6Vb, Primary motor area, Primary motor cortex M1, forelimb area, Primary sensory cortex, Primary somatosensory cortex, Principal Sulcus, Pro motor area, Retroinsular area, Rostral inferior parietal lobule, Rostral superior parietal lobule, SMA - rostral part, Secondary somatosensory cortex, Superior temporal sulcus, Temporal area TF, Temporal area TH, Temporal parietooccipital associated area in superior temporal sulcus, Temporal proisocortex, Temporoparietal asscociated area (caudal part), Temporoparietal associated area (intermediate part), Temporoparietal associated area (rostral part), Temporoparietal cortex, Temporopolar area TG, Ventral intraparietal area, Ventral posterior lateral nucleus (thalamus), Visual area 2, Visual area 3, Visual area 4, Visual area 4 (dorsal part), Visual area V6A, area 24, belt line of the sensorymotor system according to CP99, caudal lateral auditory (belt), orofacial representation in MI, posterior lateral auditory area, rostroventral parietal area as defined in DLRPK03, superior parietal lobule (posterior dorsomedial parietal cortex above the intraparietal sulcus), superior temporal gyrus, temporal visual association area in the lower bank of the superior temporal sulcus, ventral anterior nucleus (thalamus)

Targets:

Area 23, Area 24c (rostral part of the cingulate sulcus), Area 35, Area 36, Area 6, Area 8, Area 9, Central amygdaloid nucleus, lateral part, Cortical area 46, Cortical area PGa, Extrastriate area OA, Intraparietal sulcus associated area in the superior temporal sulcus, Nucleus caudatus, Nucleus caudatus; genu, Nucleus caudatus; tail, Nucleus centralis superior lateralis thalami, Nucleus medialis dorsalis thalami, Nucleus paracentralis thalami, Nucleus pulvinaris lateralis thalami, dorsal division, Nucleus pulvinaris medialis thalami, Nucleus pulvinaris medialis thalami, lateral division, Nucleus pulvinaris medialis thalami, medial division, Nucleus pulvinaris oralis thalami, Nucleus reticularis thalami, Nucleus suprageniculatus thalami, Nucleus ventralis lateralis thalami, pars caudalis, Nucleus ventralis posterior lateralis thalami, pars caudalis, Parietal area PE (cingulate part), Parietal area PG, medial part, Presubiculum, Putamen; caudal, Putamen; rostral, Temporal area TAa, Temporal area TF, Temporal parietooccipital associated area in superior temporal sulcus, Temporoparietal cortex, Ventral intraparietal area, Ventral posterior lateral nucleus (thalamus), area 24, posterior lateral auditory area

Descendant targets:

Agranular frontal area 2 (= caudal dorsolateral premotor area), Agranular frontal area 4 (= caudal ventrolateral premotor area), Agranular frontal area 5 (= rostral ventrolateral premotor area), Agranular frontal area 6 (= pre-SMA), Agranular frontal area 7 (= rostral dorsolateral premotor area), Agranular insula, Anterior inferotemporal area (dorsal), Area 1, Area 11, Area 12, Area 21, Area 23, Area 23b, Area 23c, Area 24a, Area 24c (rostral part of the cingulate sulcus), Area 31, Area 32, Area 6, Area 6 (ventral part), Area 7a, Area 7b, Area 8A, Area 8B, Area X (thalamus), CA1 subfield of Ammon`s horn, Caudal and medial superior parietal lobule, Central amygdaloid nucleus, lateral part, Centrum medianum thalami, Claustrum, Corpus geniculatum mediale, Cortical area 45, Cortical area 45A, Cortical area 46, Cortical area 9\/46d, Cortical area 9\/46v, Cortical area PGa, Dorsal portion of area 8A, Dorsal prelunate gyrus, Dysgranular insular cortex, Floor of superior temporal sulcus, Frontal eye field, Granular insular cortex, Gustatory cortex, Intraparietal sulcus associated area in the superior temporal sulcus, LGN internal magnocellular layer, LGN layer 2, Lateral area 12, Lateral intraparietal area, Medial area 12, Medial premotor area 6M, Medial superior temporal area, Medial superior temporal area (dorsal), Middle temporal area, Midpart of the inferior parietal lobule, Nucleus caudatus, Nucleus caudatus; genu, Nucleus limitans thalami, Nucleus medialis dorsalis thalami, Nucleus medialis dorsalis thalami, pars densocellularis, Nucleus paracentralis thalami, Nucleus pulvinaris medialis thalami, Nucleus pulvinaris medialis thalami, lateral division, Nucleus pulvinaris medialis thalami, medial division, Nucleus pulvinaris oralis thalami, Nucleus pulvinaris thalami, pars oralis, Nucleus reticularis thalami, Nucleus suprageniculatus thalami, Nucleus ventralis lateralis thalami, pars caudalis, Nucleus ventralis lateralis thalami, pars medialis, Nucleus

ventralis lateralis thalami, pars oralis, Nucleus ventralis posterior inferior thalami, Nucleus ventralis posterior medialis thalami, Orbital area 12, Parietal area PE (cingulate part), Parietal area PG, medial part, Peripheral part of area MT, Posterior inferotemporal area, Premotor area 6 (dorsal part), Primary motor area, Primary motor cortex M1, forelimb area, Primary somatosensory cortex, Principal Sulcus, Pro motor area, Putamen, Putamen; caudal, Putamen; rostral, Retroinsular area, Rostral parietal operculum, SMA - rostral part, Secondary somatosensory cortex, Superior temporal sulcus, Temporal area TAa, Temporal area TF, Temporal area TH, Temporal parietooccipital associated area in superior temporal sulcus, Temporoparietal asscociated area (caudal part), Temporoparietal associated area (intermediate part), Temporoparietal associated area (rostral part), Transitional sensory area, V4 transitional area, Ventral area 46, Ventral posterior lateral nucleus (thalamus), Visual area 4, Visual area V6A, area 24, belt line of the sensorymotor system according to CP99, face representation in SII as defined in DLRPK03, orofacial representation in MI, posterior lateral auditory area, rostroventral parietal area as defined in DLRPK03, superior parietal lobule (posterior dorsomedial parietal cortex above the intraparietal sulcus), superior temporal gyrus

Sub-regions:
Area 7a, Area 7b

Region: Area 7a (7a)

Super-regions:
Area 7a < Inferior parietal lobule (lateral posterior cortex below the intraparietal sulcus) < Area 7 < ParietalLobe according to GM-Definition < GM-CerebralCortex < Brain

Sources:
Anterior inferotemporal area (dorsal), Area 12, Area 6, Area 6 (ventral part), Area 7b, Area 8A, Area 8B, Caudal area 8A, Cortical area 45, Cortical area 45A, Cortical area 45B, Cortical area 46, Dorsal prelunate gyrus, Floor of superior temporal sulcus, Frontal eye field, Lateral intraparietal area, Medial intraparietal area, Medial superior temporal area (dorsal), Nucleus pulvinaris thalami, pars oralis, Parietal area PG, medial part, Premotor area 6 (dorsal part), Superior temporal sulcus, Temporal area TF, Temporal area TH, Ventral intraparietal area, Visual area V6A, area 24

Descendant sources:
Agranular frontal area 5 (= rostral ventrolateral premotor area), Anterior medial nucleus, Area 23, Area 26, Caudal and medial superior parietal lobule, Central amygdaloid nucleus, lateral part, Centrum medianum thalami, Cortical area 46, Cortical area OAa, Cortical area PGa, Cortical area TEm, Dorsal prelunate gyrus, Extrastriate area OA, Floor of superior temporal sulcus, Hypothalamus, Intraparietal sulcus associated area in the superior temporal sulcus, Lateral Geniculate Nucleus, Laterodorsal nucleus (thalamus), Medial superior temporal area, Middle temporal area, Nucleus anterior ventralis thalami, Nucleus centralis superior lateralis thalami, Nucleus limitans thalami, Nucleus medialis dorsalis thalami, pars densocellularis, Nucleus medialis dorsalis thalami, pars multiformis, Nucleus medialis dorsalis thalami, pars parvocellularis, Nucleus paracentralis thalami, Nucleus parafascicularis thalami, Nucleus pulvinaris inferior thalami, central subdivision, Nucleus pulvinaris inferior thalami, pars medialis, Nucleus pulvinaris lateralis thalami, dorsal division, Nucleus pulvinaris medialis thalami, Nucleus pulvinaris medialis thalami, lateral division, Nucleus pulvinaris medialis thalami, medial division, Nucleus pulvinaris thalami, Nucleus pulvinaris thalami, pars oralis, Nucleus suprageniculatus thalami, Nucleus ventralis lateralis thalami, pars caudalis, Nucleus ventralis lateralis thalami, pars postrema, Nucleus ventralis posterior lateralis thalami, pars caudalis, Primary sensory cortex, Principal Sulcus, Rostral superior parietal lobule, SMA - rostral part, Superior temporal sulcus, Temporal parietooccipital associated area in superior temporal sulcus, Temporal

proisocortex, Temporoparietal asscociated area (caudal part), Temporoparietal associated area (rostral part), Temporoparietal cortex, Ventral posterior lateral nucleus (thalamus), Visual area 2, Visual area 3, Visual area 4, Visual area 4 (dorsal part), area 24, posterior lateral auditory area, temporal visual association area in the lower bank of the superior temporal sulcus, ventral anterior nucleus (thalamus)

Targets:
Agranular frontal area 2 (= caudal dorsolateral premotor area), Agranular frontal area 5 (= rostral ventrolateral premotor area), Agranular frontal area 7 (= rostral dorsolateral premotor area), Anterior inferotemporal area (dorsal), Area 6, Area 6 (ventral part), Area 7b, CA1 subfield of Ammon`s horn, Caudal and medial superior parietal lobule, Cortical area 45A, Cortical area 46, Dorsal prelunate gyrus, Frontal eye field, LGN layer 2, Lateral intraparietal area, Medial area 12, Medial superior temporal area (dorsal), Nucleus pulvinaris thalami, pars oralis, Parietal area PG, medial part, Posterior inferotemporal area, Premotor area 6 (dorsal part), Superior temporal sulcus, Temporal area TF, Temporal area TH, Visual area V6A

Descendant targets:
Agranular frontal area 6 (= pre-SMA), Area 11, Area 23, Area 23b, Area 23c, Area 31, Area 32, Area 8A, Area 8B, Corpus geniculatum mediale, Cortical area 46, Cortical area 9\/46d, Cortical area PGa, Dorsal portion of area 8A, Floor of superior temporal sulcus, Intraparietal sulcus associated area in the superior temporal sulcus, Lateral area 12, Medial superior temporal area, Middle temporal area, Nucleus caudatus; genu, Nucleus limitans thalami, Nucleus medialis dorsalis thalami, pars densocellularis, Nucleus pulvinaris medialis thalami, lateral division, Nucleus pulvinaris medialis thalami, medial division, Nucleus suprageniculatus thalami, Orbital area 12, Parietal area PE (cingulate part), Principal Sulcus, SMA - rostral part, Temporal area TAa, Temporal parietooccipital associated area in superior temporal sulcus, Temporoparietal asscociated area (caudal part), Temporoparietal associated area (intermediate part), Temporoparietal associated area (rostral part), Transitional sensory area, V4 transitional area, Ventral area 46, Visual area 4

Sub-regions:
Caudal inferior parietal lobule, Occipitoparietal area

Region: Caudal inferior parietal lobule (PG#1)

Super-regions:
Caudal inferior parietal lobule < Area 7a < Inferior parietal lobule (lateral posterior cortex below the intraparietal sulcus) < Area 7 < ParietalLobe according to GM-Definition < GM-CerebralCortex < Brain

Sources:
Agranular frontal area 5 (= rostral ventrolateral premotor area), Anterior medial nucleus, Area 23, Area 26, Caudal and medial superior parietal lobule, Central amygdaloid nucleus, lateral part, Centrum medianum thalami, Cortical area 46, Cortical area OAa, Cortical area PGa, Cortical area TEm, Dorsal prelunate gyrus, Extrastriate area OA, Floor of superior temporal sulcus, Hypothalamus, Intraparietal sulcus associated area in the superior temporal sulcus, Lateral Geniculate Nucleus, Medial superior temporal area, Middle temporal area, Nucleus limitans thalami, Nucleus medialis dorsalis thalami, pars densocellularis, Nucleus medialis dorsalis thalami, pars parvocellularis, Nucleus parafascicularis thalami, Nucleus pulvinaris inferior thalami, central subdivision, Nucleus pulvinaris inferior thalami, pars medialis, Nucleus pulvinaris lateralis thalami, dorsal division, Nucleus pulvinaris medialis thalami, Nucleus pulvinaris medialis thalami, lateral division, Nucleus pulvinaris medialis thalami, medial division, Nucleus pulvinaris thalami,

Nucleus pulvinaris thalami, pars oralis, Nucleus suprageniculatus thalami, Nucleus ventralis lateralis thalami, pars caudalis, Nucleus ventralis lateralis thalami, pars postrema, Primary sensory cortex, Principal Sulcus, Rostral superior parietal lobule, Superior temporal sulcus, Temporal parietooccipital associated area in superior temporal sulcus, Temporal proisocortex, Temporoparietal asscociated area (caudal part), Temporoparietal associated area (rostral part), Ventral posterior lateral nucleus (thalamus), Visual area 2, Visual area 3, Visual area 4, Visual area 4 (dorsal part), area 24, posterior lateral auditory area, temporal visual association area in the lower bank of the superior temporal sulcus, ventral anterior nucleus (thalamus)

Targets:
Agranular frontal area 6 (= pre-SMA), Area 11, Area 23, Area 23c, Area 31, Area 32, Area 8A, Area 8B, Corpus geniculatum mediale, Cortical area 46, Cortical area 9\/46d, Cortical area PGa, Lateral area 12, Nucleus caudatus; genu, Nucleus limitans thalami, Nucleus medialis dorsalis thalami, pars densocellularis, Nucleus pulvinaris medialis thalami, lateral division, Nucleus pulvinaris medialis thalami, medial division, Nucleus suprageniculatus thalami, Orbital area 12, Parietal area PE (cingulate part), Principal Sulcus, Temporal parietooccipital associated area in superior temporal sulcus, Transitional sensory area, Ventral area 46, Visual area 4

Region: Occipitoparietal area (Opt)

Super-regions:
Occipitoparietal area < Area 7a < Inferior parietal lobule (lateral posterior cortex below the intraparietal sulcus) < Area 7 < ParietalLobe according to GM-Definition < GM-CerebralCortex < Brain

Sources:
Anterior medial nucleus, Central amygdaloid nucleus, lateral part, Cortical area 46, Cortical area PGa, Laterodorsal nucleus (thalamus), Nucleus anterior ventralis thalami, Nucleus centralis superior lateralis thalami, Nucleus medialis dorsalis thalami, pars multiformis, Nucleus paracentralis thalami, Nucleus parafascicularis thalami, Nucleus pulvinaris medialis thalami, Nucleus ventralis lateralis thalami, pars caudalis, Nucleus ventralis lateralis thalami, pars postrema, Nucleus ventralis posterior lateralis thalami, pars caudalis, SMA - rostral part, Superior temporal sulcus, Temporoparietal asscociated area (caudal part), Temporoparietal associated area (rostral part), Temporoparietal cortex, Ventral posterior lateral nucleus (thalamus)

Targets:
Area 23, Area 23b, Area 23c, Area 31, Area 8A, Area 8B, Cortical area 46, Dorsal portion of area 8A, Floor of superior temporal sulcus, Intraparietal sulcus associated area in the superior temporal sulcus, Medial superior temporal area, Middle temporal area, SMA - rostral part, Temporal area TAa, Temporoparietal asscociated area (caudal part), Temporoparietal associated area (intermediate part), Temporoparietal associated area (rostral part), V4 transitional area

---
Region: Area 7b (7b)

Super-regions:
Area 7b < Inferior parietal lobule (lateral posterior cortex below the intraparietal sulcus) < Area 7 < ParietalLobe according to GM-Definition

< GM-CerebralCortex < Brain

Sources:
Agranular insula, Anterior inferotemporal area (dorsal), Area 1, Area 11, Area 12, Area 21, Area 23, Area 23c, Area 24a, Area 24b, Area 24c (rostral part of the cingulate sulcus), Area 6, Area 6 (ventral part), Area 7a, Caudal parietal operculum, Cortical area 45, Cortical area 46, Dysgranular insular cortex, Granular insular cortex, Intraparietal sulcus associated area in the superior temporal sulcus, LGN internal magnocellular layer, LGN layer 2, Lateral intraparietal area, Lateral intraparietal area (external part), Lateral intraparietal area (internal part), Medial premotor area 6M, Medial superior temporal area, Motor area 4c, Parietal area PE (cingulate part), Parietal area PG, medial part, Peripheral part of area MT, Precentral opercular area, Premotor area 6 (dorsal part), Premotor area 6Va, Premotor area 6Vb, Primary somatosensory cortex, Pro motor area, Retroinsular area, Secondary somatosensory cortex, Temporal parietooccipital associated area in superior temporal sulcus, Temporoparietal asscociated area (caudal part), Temporoparietal associated area (intermediate part), Temporoparietal associated area (rostral part), Temporopolar area TG, Ventral intraparietal area, caudal lateral auditory (belt), rostroventral parietal area as defined in DLRPK03, superior parietal lobule (posterior dorsomedial parietal cortex above the intraparietal sulcus), superior temporal gyrus, temporal visual association area in the lower bank of the superior temporal sulcus

Descendant sources:
Agranular frontal area 4 (= caudal ventrolateral premotor area), Agranular frontal area 5 (= rostral ventrolateral premotor area), Agranular insula, Area 1, Area 6 (ventral part), Central amygdaloid nucleus, lateral part, Centrum medianum thalami, Claustrum, Dysgranular insular cortex, Granular insular cortex, Insula, LGN layer 2, Nucleus centralis superior lateralis thalami, Nucleus medialis dorsalis thalami, pars multiformis, Nucleus medialis dorsalis thalami, pars parvocellularis, Nucleus paracentralis thalami, Nucleus pulvinaris medialis thalami, Nucleus pulvinaris oralis thalami, Nucleus ventralis lateralis thalami, pars caudalis, Nucleus ventralis posterior inferior thalami, Nucleus ventralis posterior lateralis thalami, pars caudalis, Nucleus ventralis posterior medialis thalami, Primary motor area, Primary motor cortex M1, forelimb area, Primary somatosensory cortex, Rostral inferior parietal lobule, Secondary somatosensory cortex, Ventral posterior lateral nucleus (thalamus), belt line of the sensorymotor system according to CP99, orofacial representation in MI, posterior lateral auditory area

Targets:
Agranular frontal area 2 (= caudal dorsolateral premotor area), Agranular frontal area 4 (= caudal ventrolateral premotor area), Agranular frontal area 5 (= rostral ventrolateral premotor area), Agranular frontal area 7 (= rostral dorsolateral premotor area), Agranular insula, Area 1, Area 11, Area 12, Area 21, Area 23c, Area 24a, Area 24c (rostral part of the cingulate sulcus), Area 6, Area 6 (ventral part), Area 7a, CA1 subfield of Ammon`s horn, Cortical area 45, Cortical area 46, Dysgranular insular cortex, Granular insular cortex, LGN internal magnocellular layer, LGN layer 2, Lateral intraparietal area, Medial area 12, Medial premotor area 6M, Medial superior temporal area, Orbital area 12, Parietal area PE (cingulate part), Peripheral part of area MT, Premotor area 6 (dorsal part), Primary motor area, Primary somatosensory cortex, Pro motor area, Retroinsular area, Secondary somatosensory cortex, area 24, belt line of the sensorymotor system according to CP99, face representation in SII as defined in DLRPK03, orofacial representation in MI, rostroventral parietal area as defined in DLRPK03, superior parietal lobule (posterior dorsomedial parietal cortex above the intraparietal sulcus), superior temporal gyrus

Descendant targets:
Agranular frontal area 4 (= caudal ventrolateral premotor area), Agranular frontal area 5 (= rostral

ventrolateral premotor area), Agranular frontal area 6 (= pre-SMA), Agranular frontal area 7 (= rostral dorsolateral premotor area), Area 23c, Area 6, Area 6 (ventral part), Area X (thalamus), Caudal and medial superior parietal lobule, Central amygdaloid nucleus, lateral part, Centrum medianum thalami, Claustrum, Cortical area 46, Cortical area 9\/46v, Dysgranular insular cortex, Gustatory cortex, LGN layer 2, Lateral intraparietal area, Midpart of the inferior parietal lobule, Nucleus caudatus, Nucleus caudatus; genu, Nucleus medialis dorsalis thalami, Nucleus paracentralis thalami, Nucleus pulvinaris medialis thalami, Nucleus pulvinaris oralis thalami, Nucleus reticularis thalami, Nucleus suprageniculatus thalami, Nucleus ventralis lateralis thalami, pars caudalis, Nucleus ventralis lateralis thalami, pars medialis, Nucleus ventralis lateralis thalami, pars oralis, Nucleus ventralis posterior inferior thalami, Nucleus ventralis posterior medialis thalami, Orbital area 12, Parietal area PE (cingulate part), Primary motor area, Primary motor cortex M1, forelimb area, Primary somatosensory cortex, Putamen, Putamen; caudal, Putamen; rostral, Rostral parietal operculum, Secondary somatosensory cortex, Ventral posterior lateral nucleus (thalamus), orofacial representation in MI, posterior lateral auditory area, superior parietal lobule (posterior dorsomedial parietal cortex above the intraparietal sulcus)

Sub-regions:
Midpart of the inferior parietal lobule, Rostral inferior parietal lobule

---
Region: Midpart of the inferior parietal lobule (PFG#1)

Super-regions:
Midpart of the inferior parietal lobule < Area 7b < Inferior parietal lobule (lateral posterior cortex below the intraparietal sulcus) < Area 7 < ParietalLobe according to GM-Definition < GM-CerebralCortex < Brain

Sources:
Agranular frontal area 5 (= rostral ventrolateral premotor area), Central amygdaloid nucleus, lateral part, Nucleus centralis superior lateralis thalami, Nucleus medialis dorsalis thalami, pars multiformis, Nucleus medialis dorsalis thalami, pars parvocellularis, Nucleus paracentralis thalami, Nucleus pulvinaris medialis thalami, Nucleus pulvinaris oralis thalami, Nucleus ventralis posterior lateralis thalami, pars caudalis, Rostral inferior parietal lobule, Ventral posterior lateral nucleus (thalamus), posterior lateral auditory area

Targets:
Agranular frontal area 6 (= pre-SMA), Agranular frontal area 7 (= rostral dorsolateral premotor area), Area 23c, Area X (thalamus), Caudal and medial superior parietal lobule, Central amygdaloid nucleus, lateral part, Centrum medianum thalami, Cortical area 9\/46v, Nucleus caudatus, Nucleus medialis dorsalis thalami, Nucleus paracentralis thalami, Nucleus pulvinaris medialis thalami, Nucleus pulvinaris oralis thalami, Nucleus reticularis thalami, Nucleus suprageniculatus thalami, Nucleus ventralis lateralis thalami, pars caudalis, Nucleus ventralis lateralis thalami, pars medialis, Nucleus ventralis lateralis thalami, pars oralis, Nucleus ventralis posterior inferior thalami, Nucleus ventralis posterior medialis thalami, Parietal area PE (cingulate part), Putamen, Putamen; caudal, Putamen; rostral, Ventral posterior lateral nucleus (thalamus), posterior lateral auditory area

---
Region: Rostral inferior parietal lobule (PF#1)

Super-regions:
Rostral inferior parietal lobule < Area 7b <

Inferior parietal lobule (lateral posterior cortex below the intraparietal sulcus) < Area 7 < ParietalLobe according to GM-Definition < GM-CerebralCortex < Brain

Sources:
Agranular frontal area 4 (= caudal ventrolateral premotor area), Agranular frontal area 5 (= rostral ventrolateral premotor area), Agranular insula, Area 1, Area 6 (ventral part), Central amygdaloid nucleus, lateral part, Centrum medianum thalami, Claustrum, Dysgranular insular cortex, Granular insular cortex, Insula, LGN layer 2, Nucleus medialis dorsalis thalami, pars multiformis, Nucleus medialis dorsalis thalami, pars parvocellularis, Nucleus paracentralis thalami, Nucleus pulvinaris medialis thalami, Nucleus pulvinaris oralis thalami, Nucleus ventralis lateralis thalami, pars caudalis, Nucleus ventralis posterior inferior thalami, Nucleus ventralis posterior lateralis thalami, pars caudalis, Nucleus ventralis posterior medialis thalami, Primary motor area, Primary motor cortex M1, forelimb area, Primary somatosensory cortex, Secondary somatosensory cortex, Ventral posterior lateral nucleus (thalamus), belt line of the sensorymotor system according to CP99, orofacial representation in MI, posterior lateral auditory area

Targets:
Agranular frontal area 4 (= caudal ventrolateral premotor area), Agranular frontal area 5 (= rostral ventrolateral premotor area), Area 6, Area 6 (ventral part), Claustrum, Cortical area 46, Cortical area 9\/46v, Dysgranular insular cortex, Gustatory cortex, LGN layer 2, Lateral intraparietal area, Midpart of the inferior parietal lobule, Nucleus caudatus, Nucleus caudatus; genu, Orbital area 12, Primary motor area, Primary motor cortex M1, forelimb area, Primary somatosensory cortex, Putamen, Putamen; caudal, Putamen; rostral, Rostral parietal operculum, Secondary somatosensory cortex, orofacial representation in MI, superior parietal lobule (posterior dorsomedial parietal cortex above the intraparietal sulcus)

Region: Cortex of the intraparietal sulcus (PCip)

Super-regions:
Cortex of the intraparietal sulcus < ParietalLobe according to GM-Definition < GM-CerebralCortex < Brain

Descendant sources:
Agranular frontal area 4 (= caudal ventrolateral premotor area), Agranular frontal area 5 (= rostral ventrolateral premotor area), Agranular frontal area 7 (= rostral dorsolateral premotor area), Anterior intraparietal area, Area 11, Area 12, Area 20, Area 21, Area 23, Area 26, Area 6, Area 6 (ventral part), Area 6 (ventral part), Area 7, Area 7a, Area 7b, Area 8B, Area 9, Area X (thalamus), Caudal and medial superior parietal lobule, Caudal area 8A, Central amygdaloid nucleus, lateral part, Central inferotemporal area (ventral), Centrum medianum thalami, Cortical area 45, Cortical area 45A, Cortical area 45B, Cortical area 46, Cortical area OAa, Cortical area PGa, Dorsal prelunate gyrus, Dorsal visual area 3, Dysgranular insular cortex, Extrastriate area OA, Floor of superior temporal sulcus, Frontal eye field, Granular insular cortex, Inferior parietal lobule (lateral posterior cortex below the intraparietal sulcus), Inferotemporal area TE, Intraparietal sulcus associated area in the superior temporal sulcus, LGN layer 2, Lateral intraparietal area, Laterodorsal nucleus (thalamus), Medial intraparietal area, Medial premotor area 6M, Medial superior temporal area, Medial superior temporal area (dorsal), Medial superior temporal area (posterior), Middle temporal area, Nucleus centralis superior lateralis thalami, Nucleus medialis dorsalis thalami, pars parvocellularis, Nucleus parafascicularis thalami, Nucleus pulvinaris medialis thalami, Nucleus pulvinaris oralis thalami, Nucleus pulvinaris thalami, pars oralis, Nucleus ventralis lateralis thalami, pars postrema, Nucleus ventralis posterior lateralis thalami, pars caudalis, Parietal area PG, medial part, Peripheral part of area MT, Posterior inferotemporal area, Posterior intraparietal area, Premotor area 6 (dorsal part), Presubiculum, Primary motor

cortex M1, forelimb area, Principal Sulcus, Rostral inferior parietal lobule, Rostral superior parietal lobule, SMA - rostral part, Superior temporal sulcus, Temporal area TF, Temporal parietooccipital associated area in superior temporal sulcus, V4 transitional area, Ventral intraparietal area, Ventral posterior lateral nucleus (thalamus), Ventral visual area 3, Visual area 1, Visual area 2, Visual area 3, Visual area 3A, Visual area 4, Visual area 4 (dorsal part), Visual area V6A, area 24, belt line of the sensorymotor system according to CP99, posterior lateral auditory area

Descendant targets:
Agranular frontal area 2 (= caudal dorsolateral premotor area), Agranular frontal area 3 (= SMA-proper), Agranular frontal area 4 (= caudal ventrolateral premotor area), Agranular frontal area 5 (= rostral ventrolateral premotor area), Agranular frontal area 7 (= rostral dorsolateral premotor area), Anterior intraparietal area, Area 1, Area 11, Area 12, Area 20, Area 21, Area 23, Area 23c, Area 26, Area 31, Area 6, Area 6 (ventral part), Area 7, Area 7a, Area 7b, Area 8A, Area 8B, Caudal and medial superior parietal lobule, Caudal area 8A, Caudal parietal operculum, Central inferotemporal area (ventral), Cortical area 45, Cortical area 45A, Cortical area 45B, Cortical area 46, Cortical area 9\/46v, Dorsal portion of area 8A, Dorsal prelunate gyrus, Dorsal visual area 3, Dysgranular insular cortex, Extrastriate area OA, Floor of superior temporal sulcus, Frontal eye field, Granular insular cortex, Inferior parietal lobule (lateral posterior cortex below the intraparietal sulcus), Inferotemporal area TE, Intraparietal sulcus associated area in the superior temporal sulcus, LGN layer 2, Lateral area 12, Lateral intraparietal area, Medial area 12, Medial intraparietal area, Medial premotor area 6M, Medial superior temporal area (dorsal), Medial superior temporal area (posterior), Middle temporal area, Nucleus caudatus, Nucleus pulvinaris thalami, pars oralis, Parietal area PE (cingulate part), Parietal area PG, medial part, Peripheral part of area MT, Posterior inferotemporal area, Posterior inferotemporal area (dorsal), Posterior inferotemporal area (ventral), Posterior intraparietal area, Premotor area 6 (dorsal part), Presubiculum, Primary motor area, Primary motor cortex M1, forelimb area, Putamen, Putamen; caudal, Putamen; rostral, SMA - rostral part, Secondary somatosensory cortex, Superior temporal sulcus, Temporal area TF, Temporal parietooccipital associated area in superior temporal sulcus, Ventral area 46, Ventral intraparietal area, Ventral visual area 3, Visual area 1, Visual area 2, Visual area 3, Visual area 3A, Visual area 4, Visual area V6A, area 24

Sub-regions:
Anterior intraparietal area, Lateral intraparietal area, Medial intraparietal area, Posterior intraparietal area, Ventral intraparietal area

---
Region: Lateral intraparietal area (LIP)

Super-regions:
Lateral intraparietal area < Cortex of the intraparietal sulcus < ParietalLobe according to GM-Definition < GM-CerebralCortex < Brain

Sources:
Agranular frontal area 5 (= rostral ventrolateral premotor area), Agranular frontal area 7 (= rostral dorsolateral premotor area), Anterior intraparietal area, Area 11, Area 12, Area 20, Area 21, Area 23, Area 26, Area 6, Area 6 (ventral part), Area 6 (ventral part), Area 7a, Area 7b, Area 8B, Area 9, Area X (thalamus), Caudal area 8A, Central amygdaloid nucleus, lateral part, Cortical area 45, Cortical area 45A, Cortical area 45B, Cortical area 46, Cortical area OAa, Cortical area PGa, Dorsal prelunate gyrus, Dorsal visual area 3, Dysgranular insular cortex, Extrastriate area OA, Floor of superior temporal sulcus, Frontal eye field, Granular insular cortex, Inferotemporal area TE, Intraparietal sulcus associated area in the superior temporal sulcus, Laterodorsal nucleus (thalamus), Medial intraparietal area, Medial premotor area 6M, Medial superior temporal area, Medial superior temporal area (dorsal), Middle temporal area, Nucleus centralis superior lateralis thalami, Nucleus medialis dorsalis thalami, pars parvocellularis, Nucleus parafascicularis thalami, Nucleus pulvinaris medialis thalami, Nucleus pulvinaris thalami, pars oralis, Nucleus ventralis lateralis thalami, pars postrema, Nucleus ventralis posterior lateralis thalami, pars caudalis,

Parietal area PG, medial part, Peripheral part of area MT, Posterior intraparietal area, Premotor area 6 (dorsal part), Presubiculum, Rostral inferior parietal lobule, Superior temporal sulcus, Temporal area TF, Temporal parietooccipital associated area in superior temporal sulcus, V4 transitional area, Ventral intraparietal area, Ventral posterior lateral nucleus (thalamus), Ventral visual area 3, Visual area 2, Visual area 3, Visual area 3A, Visual area 4, Visual area 4 (dorsal part), Visual area V6A, area 24, posterior lateral auditory area

Descendant sources:
Central inferotemporal area (ventral), Extrastriate area OA, Posterior inferotemporal area, Principal Sulcus, Ventral visual area 3, Visual area 2

Targets:
Agranular frontal area 5 (= rostral ventrolateral premotor area), Agranular frontal area 7 (= rostral dorsolateral premotor area), Anterior intraparietal area, Area 11, Area 12, Area 20, Area 21, Area 23, Area 26, Area 6, Area 6 (ventral part), Area 7a, Area 7b, Area 8A, Area 8B, Caudal area 8A, Cortical area 45, Cortical area 45A, Cortical area 45B, Cortical area 46, Cortical area 9\/46v, Dorsal portion of area 8A, Dorsal prelunate gyrus, Dorsal visual area 3, Dysgranular insular cortex, Extrastriate area OA, Floor of superior temporal sulcus, Frontal eye field, Granular insular cortex, Inferotemporal area TE, Intraparietal sulcus associated area in the superior temporal sulcus, LGN layer 2, Medial intraparietal area, Medial premotor area 6M, Medial superior temporal area (dorsal), Medial superior temporal area (posterior), Middle temporal area, Nucleus caudatus, Nucleus pulvinaris thalami, pars oralis, Parietal area PG, medial part, Peripheral part of area MT, Posterior inferotemporal area (ventral), Posterior intraparietal area, Premotor area 6 (dorsal part), Presubiculum, Primary motor cortex M1, forelimb area, Putamen; caudal, Secondary somatosensory cortex, Superior temporal sulcus, Temporal area TF, Temporal parietooccipital associated area in superior temporal sulcus, Ventral intraparietal area, Ventral visual area 3, Visual area 1, Visual area 2, Visual area 3, Visual area 3A, Visual area 4, Visual area V6A, area 24

Descendant targets:
Agranular frontal area 2 (= caudal dorsolateral premotor area), Agranular frontal area 4 (= caudal ventrolateral premotor area), Agranular frontal area 5 (= rostral ventrolateral premotor area), Area 7b, Area 8A, Central inferotemporal area (ventral), Cortical area 45A, Lateral area 12, Medial superior temporal area (dorsal), Middle temporal area, Posterior inferotemporal area, Posterior inferotemporal area (dorsal), Ventral area 46, Ventral visual area 3

Sub-regions:
Lateral intraparietal area (external part), Lateral intraparietal area (internal part)

Region: Lateral intraparietal area (external part) (LIPe)

Super-regions:
Lateral intraparietal area (external part) < Lateral intraparietal area < Cortex of the intraparietal sulcus < ParietalLobe according to GM-Definition < GM-CerebralCortex < Brain

Sources:
Central inferotemporal area (ventral), Extrastriate area OA, Posterior inferotemporal area, Principal Sulcus

Targets:
Agranular frontal area 2 (= caudal dorsolateral premotor area), Agranular frontal area 5 (= rostral ventrolateral premotor area), Area 7b, Area 8A, Central inferotemporal area (ventral), Cortical area 45A, Lateral area 12, Medial superior temporal area (dorsal), Posterior inferotemporal area, Posterior inferotemporal area (dorsal), Ventral area 46

Region: Lateral intraparietal area (internal part) (LIPi)

Super-regions:
Lateral intraparietal area (internal part) < Lateral intraparietal area < Cortex of the intraparietal sulcus < ParietalLobe according to GM-Definition < GM-CerebralCortex < Brain

Sources:
Central inferotemporal area (ventral), Extrastriate area OA, Posterior inferotemporal area, Principal Sulcus, Ventral visual area 3, Visual area 2

Targets:
Agranular frontal area 2 (= caudal dorsolateral premotor area), Agranular frontal area 4 (= caudal ventrolateral premotor area), Area 7b, Area 8A, Central inferotemporal area (ventral), Cortical area 45A, Lateral area 12, Medial superior temporal area (dorsal), Middle temporal area, Posterior inferotemporal area, Ventral area 46, Ventral visual area 3

Region: Ventral intraparietal area (VIP)

Super-regions:
Ventral intraparietal area < Cortex of the intraparietal sulcus < ParietalLobe according to GM-Definition < GM-CerebralCortex < Brain

Sources:
Area 6 (ventral part), Area 7, Cortical area OAa, Cortical area PGa, Floor of superior temporal sulcus, Frontal eye field, Inferior parietal lobule (lateral posterior cortex below the intraparietal sulcus), Lateral intraparietal area, Medial superior temporal area (dorsal), Medial superior temporal area (posterior), Middle temporal area, Posterior inferotemporal area, Ventral visual area 3, Visual area 2, Visual area 3, Visual area 3A, Visual area V6A, belt line of the sensorymotor system according to CP99

Targets:
Agranular frontal area 2 (= caudal dorsolateral premotor area), Agranular frontal area 4 (= caudal ventrolateral premotor area), Agranular frontal area 7 (= rostral dorsolateral premotor area), Area 23c, Area 6, Area 7, Area 7a, Area 7b, Area 8A, Caudal and medial superior parietal lobule, Cortical area 45A, Floor of superior temporal sulcus, Frontal eye field, Inferior parietal lobule (lateral posterior cortex below the intraparietal sulcus), Lateral intraparietal area, Medial superior temporal area (dorsal), Medial superior temporal area (posterior), Middle temporal area, Nucleus pulvinaris thalami, pars oralis, Posterior inferotemporal area, Premotor area 6 (dorsal part), Visual area 3, Visual area 3A, Visual area 4, Visual area V6A

Region: Posterior intraparietal area (PIP#1)

Super-regions:
Posterior intraparietal area < Cortex of the intraparietal sulcus < ParietalLobe according to GM-Definition < GM-CerebralCortex < Brain

Sources:
Dorsal prelunate gyrus, Lateral intraparietal area, Middle temporal area, Ventral visual area 3, Visual area 1, Visual area 2, Visual area 3, Visual area 4

Targets:
Dorsal prelunate gyrus, Lateral intraparietal area, Medial superior temporal area (dorsal), Middle temporal area, Nucleus pulvinaris thalami, pars oralis, Ventral visual area 3, Visual area 1, Visual area 3, Visual area 4

Region: Anterior intraparietal area (AIP)

Super-regions:

Anterior intraparietal area < Cortex of the intraparietal sulcus < ParietalLobe according to GM-Definition < GM-CerebralCortex < Brain

Sources:
Agranular frontal area 4 (= caudal ventrolateral premotor area), Agranular frontal area 5 (= rostral ventrolateral premotor area), LGN layer 2, Lateral intraparietal area, Medial intraparietal area, Visual area V6A

Targets:
Agranular frontal area 2 (= caudal dorsolateral premotor area), Agranular frontal area 4 (= caudal ventrolateral premotor area), Agranular frontal area 5 (= rostral ventrolateral premotor area), Area 1, Area 6 (ventral part), Caudal and medial superior parietal lobule, Lateral intraparietal area, Medial area 12

Region: Medial intraparietal area (MIP)

Super-regions:
Medial intraparietal area < Cortex of the intraparietal sulcus < ParietalLobe according to GM-Definition < GM-CerebralCortex < Brain

Sources:
Agranular frontal area 5 (= rostral ventrolateral premotor area), Area 6 (ventral part), Area 7, Caudal and medial superior parietal lobule, Central amygdaloid nucleus, lateral part, Centrum medianum thalami, Lateral intraparietal area, Nucleus medialis dorsalis thalami, pars parvocellularis, Nucleus pulvinaris oralis thalami, Nucleus ventralis lateralis thalami, pars postrema, Nucleus ventralis posterior lateralis thalami, pars caudalis, Primary motor cortex M1, forelimb area, Rostral superior parietal lobule, SMA - rostral part, Ventral posterior lateral nucleus (thalamus), Visual area 3A, Visual area V6A, posterior lateral auditory area

Targets:
Agranular frontal area 2 (= caudal dorsolateral premotor area), Agranular frontal area 3 (= SMA-proper), Agranular frontal area 4 (= caudal ventrolateral premotor area), Agranular frontal area 5 (= rostral ventrolateral premotor area), Agranular frontal area 7 (= rostral dorsolateral premotor area), Anterior intraparietal area, Area 23c, Area 31, Area 6, Area 7, Area 7a, Caudal and medial superior parietal lobule, Caudal parietal operculum, Dorsal portion of area 8A, Inferior parietal lobule (lateral posterior cortex below the intraparietal sulcus), LGN layer 2, Lateral intraparietal area, Medial superior temporal area (dorsal), Middle temporal area, Nucleus caudatus, Nucleus pulvinaris thalami, pars oralis, Parietal area PE (cingulate part), Premotor area 6 (dorsal part), Primary motor area, Primary motor cortex M1, forelimb area, Putamen, Putamen; caudal, Putamen; rostral, SMA - rostral part, Secondary somatosensory cortex, Visual area 3A, Visual area V6A

Region: Dorsal parietal cortex (= SPL and precuneus) (PCd#2)

Super-regions:
Dorsal parietal cortex (= SPL and precuneus) < ParietalLobe according to GM-Definition < GM-CerebralCortex < Brain

Descendant sources:
Agranular frontal area 2 (= caudal dorsolateral premotor area), Agranular frontal area 3 (= SMA-proper), Agranular frontal area 5 (= rostral ventrolateral premotor area), Agranular frontal area 6 (= pre-SMA), Agranular frontal area 7 (= rostral dorsolateral premotor area), Agranular insula, Anterior intraparietal area, Anterior medial nucleus, Area 1, Area 10, Area 11, Area 23, Area 23a, Area 23b, Area 23c, Area 24a, Area 24b, Area 24c (rostral part of the cingulate sulcus), Area 26, Area 29, Area 3, Area 31, Area 36, Area 6 (ventral part), Area 6 (ventral part), Area 7, Area 7a, Area 7b, Area 8B, Area 9, Caudal and medial superior parietal lobule, Caudal auditory parakoniocortex, Caudal inferior parietal lobule, Caudal parietal operculum, Central amygdaloid nucleus, lateral part, Centrum medianum thalami, Claustrum, Cortical area 44, Cortical area 45, Cortical area 46, Cortical area 9\/46d, Dorsal portion of area 8A, Dysgranular insular cortex, Frontal

eye field, Granular insular cortex, Hypothalamus, Inferior parietal lobule (lateral posterior cortex below the intraparietal sulcus), LGN internal magnocellular layer, LGN layer 2, Lateral intraparietal area, Medial intraparietal area, Medial premotor area 6M, Medial superior temporal area, Midpart of the inferior parietal lobule, Nucleus anterior ventralis thalami, Nucleus centralis superior lateralis thalami, Nucleus limitans thalami, Nucleus medialis dorsalis thalami, pars densocellularis, Nucleus medialis dorsalis thalami, pars multiformis, Nucleus medialis dorsalis thalami, pars parvocellularis, Nucleus paracentralis thalami, Nucleus paraventricularis thalami, pars anterior, Nucleus pulvinaris medialis thalami, Nucleus pulvinaris oralis thalami, Nucleus pulvinaris thalami, pars oralis, Nucleus reuniens thalami, Nucleus ventralis lateralis thalami, pars caudalis, Nucleus ventralis lateralis thalami, pars postrema, Nucleus ventralis posterior lateralis thalami, pars caudalis, Nucleus ventralis posterior lateralis thalami, pars oralis, Occipitoparietal area, Orbitofrontal area 13, Parietal area PE (cingulate part), Parietal area PG, medial part, Peripheral part of area MT, Postcentral area 3a, Postcentral area 3b, Premotor area 6 (dorsal part), Presubiculum, Primary motor area, Primary motor cortex M1, forelimb area, Primary motor cortex M1, hindlimb area, Primary sensory cortex, Primary somatosensory cortex, Principal Sulcus, Retroinsular area, Retrosplenial area 30, Rostral inferior parietal lobule, Rostral superior parietal lobule, SMA - rostral part, Secondary somatosensory cortex, Temporal area TF, Temporal area TH, Temporal parietooccipital associated area in superior temporal sulcus, Temporoparietal asscociated area (caudal part), Temporoparietal associated area (rostral part), Temporoparietal cortex, Transitional sensory area, Ventral intraparietal area, Ventral posterior lateral nucleus (thalamus), Ventroposterior superior nucleus thalami, Visual area 2, Visual area 3, Visual area V6A, area 24, posterior lateral auditory area, rostroventral parietal area as defined in DLRPK03, superior temporal gyrus

Descendant targets:
Agranular frontal area 2 (= caudal dorsolateral premotor area), Agranular frontal area 3 (= SMA-proper), Agranular frontal area 4 (= caudal ventrolateral premotor area), Agranular frontal area 5 (= rostral ventrolateral premotor area), Agranular frontal area 7 (= rostral dorsolateral premotor area), Agranular insula, Area 1, Area 23, Area 23c, Area 24a, Area 24b, Area 24c (rostral part of the cingulate sulcus), Area 26, Area 3, Area 31, Area 6, Area 6 (ventral part), Area 7, Area 7a, Area 7b, Area 8, Area 8A, Area 8B, Area 9, Caudal and medial superior parietal lobule, Caudal inferior parietal lobule, Caudal parietal operculum, Central amygdaloid nucleus, lateral part, Cortical area 45, Cortical area 45A, Cortical area 46, Cortical area 9\/46d, Cortical area PGa, Dorsal portion of area 8A, Dysgranular insular cortex, Frontal eye field, Granular insular cortex, Inferior parietal lobule (lateral posterior cortex below the intraparietal sulcus), Intralaminar nuclei of the thalamus, LGN layer 2, Lateral intraparietal area, Laterodorsal nucleus (thalamus), Medial area 9, Medial intraparietal area, Medial premotor area 6M, Medial superior temporal area, Nucleus caudatus, Nucleus caudatus; genu, Nucleus centralis superior lateralis thalami, Nucleus medialis dorsalis thalami, Nucleus pulvinaris medialis thalami, Nucleus pulvinaris oralis thalami, Nucleus pulvinaris thalami, pars oralis, Nucleus reticularis thalami, Nucleus ventralis lateralis thalami, pars caudalis, Nucleus ventralis lateralis thalami, pars postrema, Nucleus ventralis posterior lateralis thalami, pars caudalis, Parietal area PE (cingulate part), Parietal area PG, medial part, Peripheral part of area MT, Premotor area 6 (dorsal part), Presubiculum, Primary motor area, Primary motor cortex M1, forelimb area, Primary somatosensory cortex, Principal Sulcus, Putamen, Putamen; caudal, Putamen; rostral, Rostral superior parietal lobule, SMA - rostral part, Temporal area TAa, Temporal area TF, Temporal parietooccipital associated area in superior temporal sulcus, Temporoparietal cortex, Transitional sensory area, Ventral posterior lateral nucleus (thalamus), Ventroposterior superior nucleus thalami, Visual area 2, Visual area V6A, area 24, posterior lateral auditory area, rostroventral parietal area as defined in DLRPK03, superior temporal gyrus, ventral lateral nucleus (thalamus)

Sub-regions:
Medial parietal cortex (= Precuneus), superior parietal lobule (posterior dorsomedial parietal cortex above the intraparietal sulcus)

Region: superior parietal lobule (posterior dorsomedial parietal cortex above the intraparietal sulcus) (SPL)

Super-regions:
superior parietal lobule (posterior dorsomedial parietal cortex above the intraparietal sulcus) < Dorsal parietal cortex (= SPL and precuneus) < ParietalLobe according to GM-Definition < GM-CerebralCortex < Brain

Sources:
Area 1, Area 7b, Central amygdaloid nucleus, lateral part, Claustrum, Dysgranular insular cortex, Granular insular cortex, Hypothalamus, LGN layer 2, Medial premotor area 6M, Nucleus paraventricularis thalami, pars anterior, Nucleus pulvinaris oralis thalami, Nucleus ventralis lateralis thalami, pars postrema, Nucleus ventralis posterior lateralis thalami, pars caudalis, Postcentral area 3a, Postcentral area 3b, Primary motor area, Primary motor cortex M1, hindlimb area, Primary sensory cortex, Primary somatosensory cortex, Retroinsular area, Rostral inferior parietal lobule, Secondary somatosensory cortex, Temporal area TF, Ventral posterior lateral nucleus (thalamus), Ventroposterior superior nucleus thalami, posterior lateral auditory area, rostroventral parietal area as defined in DLRPK03

Descendant sources:
Agranular frontal area 2 (= caudal dorsolateral premotor area), Agranular frontal area 3 (= SMA-proper), Agranular frontal area 5 (= rostral ventrolateral premotor area), Agranular frontal area 6 (= pre-SMA), Agranular frontal area 7 (= rostral dorsolateral premotor area), Anterior intraparietal area, Area 23c, Area 6 (ventral part), Area 6 (ventral part), Area 7, Area 7a, Caudal and medial superior parietal lobule, Central amygdaloid nucleus, lateral part, Centrum medianum thalami, Medial intraparietal area, Medial superior temporal area, Midpart of the inferior parietal lobule, Nucleus limitans thalami, Nucleus medialis dorsalis thalami, pars densocellularis, Nucleus medialis dorsalis thalami, pars multiformis, Nucleus pulvinaris oralis thalami, Nucleus ventralis lateralis thalami, pars caudalis, Nucleus ventralis lateralis thalami, pars postrema, Nucleus ventralis posterior lateralis thalami, pars caudalis, Nucleus ventralis posterior lateralis thalami, pars oralis, Parietal area PE (cingulate part), Parietal area PG, medial part, Primary motor cortex M1, forelimb area, Rostral superior parietal lobule, SMA - rostral part, Ventral intraparietal area, Ventral posterior lateral nucleus (thalamus), Visual area V6A, posterior lateral auditory area

Targets:
Agranular frontal area 2 (= caudal dorsolateral premotor area), Agranular frontal area 4 (= caudal ventrolateral premotor area), Agranular frontal area 5 (= rostral ventrolateral premotor area), Agranular frontal area 7 (= rostral dorsolateral premotor area), Area 1, Area 6, Area 6 (ventral part), Area 7, Area 7b, Area 8A, LGN layer 2, Medial premotor area 6M, Nucleus pulvinaris oralis thalami, Primary motor area, Primary motor cortex M1, forelimb area, Primary somatosensory cortex, Ventral posterior lateral nucleus (thalamus), Ventroposterior superior nucleus thalami, rostroventral parietal area as defined in DLRPK03

Descendant targets:
Agranular frontal area 2 (= caudal dorsolateral premotor area), Agranular frontal area 3 (= SMA-proper), Agranular frontal area 7 (= rostral dorsolateral premotor area), Area 23, Area 23c, Area 24b, Area 24c (rostral part of the cingulate sulcus), Area 3, Area 31, Area 6, Area 6 (ventral part), Area 8, Caudal and medial superior parietal lobule, Caudal inferior parietal lobule, Caudal parietal operculum, Central amygdaloid nucleus, lateral part, Cortical area 46, Cortical area PGa, Intralaminar nuclei of the thalamus, LGN layer 2, Medial area 9, Medial intraparietal area, Medial premotor area 6M, Nucleus caudatus, Nucleus caudatus; genu, Nucleus centralis superior lateralis thalami, Nucleus medialis dorsalis thalami, Nucleus pulvinaris medialis thalami, Nucleus pulvinaris oralis thalami, Nucleus reticularis thalami, Nucleus ventralis lateralis thalami, pars caudalis, Nucleus ventralis posterior lateralis thalami, pars caudalis, Parietal area PE (cingulate part), Parietal area PG, medial part, Premotor area 6 (dorsal part), Primary motor area, Primary motor cortex M1, forelimb area, Putamen, Putamen; caudal, Putamen; rostral, Rostral superior parietal lobule, SMA - rostral part, Temporal area TAa, Temporal parietooccipital associated area in superior temporal sulcus, Temporoparietal cortex,

Transitional sensory area, Ventral posterior lateral nucleus (thalamus), Visual area V6A, area 24, ventral lateral nucleus (thalamus)

Sub-regions:
Caudal and medial superior parietal lobule, Receptive field for the foot in Area5, Rostral superior parietal lobule

---
Region: Rostral superior parietal lobule (PEm)

Super-regions:
Rostral superior parietal lobule < superior parietal lobule (posterior dorsomedial parietal cortex above the intraparietal sulcus) < Dorsal parietal cortex (= SPL and precuneus) < ParietalLobe according to GM-Definition < GM-CerebralCortex < Brain

Sources:
Area 6 (ventral part), Area 7, Caudal and medial superior parietal lobule, Central amygdaloid nucleus, lateral part, Centrum medianum thalami, Nucleus limitans thalami, Nucleus medialis dorsalis thalami, pars densocellularis, Nucleus pulvinaris oralis thalami, Nucleus ventralis lateralis thalami, pars caudalis, Nucleus ventralis lateralis thalami, pars postrema, Nucleus ventralis posterior lateralis thalami, pars caudalis, Nucleus ventralis posterior lateralis thalami, pars oralis, Parietal area PG, medial part, Primary motor cortex M1, forelimb area, Ventral posterior lateral nucleus (thalamus), posterior lateral auditory area

Targets:
Agranular frontal area 2 (= caudal dorsolateral premotor area), Agranular frontal area 3 (= SMA-proper), Agranular frontal area 7 (= rostral dorsolateral premotor area), Area 23, Area 23c, Area 24b, Area 24c (rostral part of the cingulate sulcus), Area 3, Area 6, Area 6 (ventral part), Area 8, Caudal and medial superior parietal lobule, Caudal inferior parietal lobule, Caudal parietal operculum, Cortical area 46, Cortical area PGa, LGN layer 2, Medial area 9, Medial intraparietal area, Medial premotor area 6M, Nucleus caudatus, Nucleus caudatus; genu, Nucleus pulvinaris medialis thalami, Nucleus pulvinaris oralis thalami, Nucleus reticularis thalami, Nucleus ventralis lateralis thalami, pars caudalis, Nucleus ventralis posterior lateralis thalami, pars caudalis, Parietal area PE (cingulate part), Parietal area PG, medial part, Primary motor area, Primary motor cortex M1, forelimb area, Putamen, Putamen; caudal, Putamen; rostral, Temporal area TAa, Temporal parietooccipital associated area in superior temporal sulcus, Temporoparietal cortex, Transitional sensory area, Ventral posterior lateral nucleus (thalamus), Visual area V6A, area 24

Region: Receptive field for the foot in Area5 (5_Foot)

Super-regions:
Receptive field for the foot in Area5 < superior parietal lobule (posterior dorsomedial parietal cortex above the intraparietal sulcus) < Dorsal parietal cortex (= SPL and precuneus) < ParietalLobe according to GM-Definition < GM-CerebralCortex < Brain

Sources:
Nucleus pulvinaris oralis thalami, Ventral posterior lateral nucleus (thalamus)

Targets:
Nucleus pulvinaris oralis thalami, Ventral posterior lateral nucleus (thalamus)

Region: Caudal and medial superior parietal lobule (PEc#1)

Super-regions:

Caudal and medial superior parietal lobule < superior parietal lobule (posterior dorsomedial parietal cortex above the intraparietal sulcus) < Dorsal parietal cortex (= SPL and precuneus) < ParietalLobe according to GM-Definition < GM-CerebralCortex < Brain

Sources:
Agranular frontal area 2 (= caudal dorsolateral premotor area), Agranular frontal area 3 (= SMA-proper), Agranular frontal area 5 (= rostral ventrolateral premotor area), Agranular frontal area 6 (= pre-SMA), Agranular frontal area 7 (= rostral dorsolateral premotor area), Anterior intraparietal area, Area 23c, Area 6 (ventral part), Area 7, Area 7a, Central amygdaloid nucleus, lateral part, Centrum medianum thalami, Medial intraparietal area, Medial superior temporal area, Midpart of the inferior parietal lobule, Nucleus medialis dorsalis thalami, pars multiformis, Nucleus pulvinaris oralis thalami, Nucleus ventralis lateralis thalami, pars postrema, Nucleus ventralis posterior lateralis thalami, pars caudalis, Parietal area PE (cingulate part), Parietal area PG, medial part, Rostral superior parietal lobule, SMA - rostral part, Ventral intraparietal area, Ventral posterior lateral nucleus (thalamus), Visual area V6A, posterior lateral auditory area

Targets:
Agranular frontal area 2 (= caudal dorsolateral premotor area), Agranular frontal area 7 (= rostral dorsolateral premotor area), Area 23c, Area 3, Area 31, Area 6, Caudal inferior parietal lobule, Caudal parietal operculum, Central amygdaloid nucleus, lateral part, Intralaminar nuclei of the thalamus, Medial intraparietal area, Nucleus caudatus, Nucleus caudatus; genu, Nucleus centralis superior lateralis thalami, Nucleus medialis dorsalis thalami, Nucleus pulvinaris medialis thalami, Nucleus pulvinaris oralis thalami, Nucleus reticularis thalami, Nucleus ventralis posterior lateralis thalami, pars caudalis, Parietal area PE (cingulate part), Parietal area PG, medial part, Premotor area 6 (dorsal part), Putamen, Putamen; caudal, Putamen; rostral, Rostral superior parietal lobule, SMA - rostral part, Transitional sensory area, Ventral posterior lateral nucleus (thalamus), Visual area V6A, ventral lateral nucleus (thalamus)

Region: Medial parietal cortex (= Precuneus) (PCm)

Super-regions:
Medial parietal cortex (= Precuneus) < Dorsal parietal cortex (= SPL and precuneus) < ParietalLobe according to GM-Definition < GM-CerebralCortex < Brain

Descendant sources:
Agranular frontal area 2 (= caudal dorsolateral premotor area), Agranular frontal area 6 (= pre-SMA), Agranular frontal area 7 (= rostral dorsolateral premotor area), Agranular insula, Anterior medial nucleus, Area 1, Area 10, Area 11, Area 23, Area 23a, Area 23b, Area 23c, Area 24a, Area 24b, Area 24c (rostral part of the cingulate sulcus), Area 26, Area 29, Area 3, Area 31, Area 36, Area 6 (ventral part), Area 7, Area 7a, Area 7b, Area 8B, Area 9, Caudal and medial superior parietal lobule, Caudal auditory parakoniocortex, Caudal inferior parietal lobule, Caudal parietal operculum, Central amygdaloid nucleus, lateral part, Cortical area 44, Cortical area 45, Cortical area 46, Cortical area 9\/46d, Dorsal portion of area 8A, Dysgranular insular cortex, Frontal eye field, Granular insular cortex, Inferior parietal lobule (lateral posterior cortex below the intraparietal sulcus), LGN internal magnocellular layer, LGN layer 2, Lateral intraparietal area, Medial intraparietal area, Medial premotor area 6M, Medial superior temporal area, Midpart of the inferior parietal lobule, Nucleus anterior ventralis thalami, Nucleus centralis superior lateralis thalami, Nucleus medialis dorsalis thalami, pars densocellularis, Nucleus medialis dorsalis thalami, pars parvocellularis, Nucleus paracentralis thalami, Nucleus pulvinaris medialis thalami, Nucleus pulvinaris oralis thalami, Nucleus pulvinaris thalami, pars oralis, Nucleus reuniens thalami, Nucleus ventralis lateralis thalami, pars caudalis, Nucleus

ventralis lateralis thalami, pars postrema, Occipitoparietal area, Orbitofrontal area 13, Parietal area PE (cingulate part), Parietal area PG, medial part, Peripheral part of area MT, Postcentral area 3a, Postcentral area 3b, Premotor area 6 (dorsal part), Presubiculum, Primary motor area, Principal Sulcus, Retrosplenial area 30, Rostral superior parietal lobule, SMA - rostral part, Secondary somatosensory cortex, Temporal area TF, Temporal area TH, Temporal parietooccipital associated area in superior temporal sulcus, Temporoparietal asscociated area (caudal part), Temporoparietal associated area (rostral part), Temporoparietal cortex, Transitional sensory area, Ventral posterior lateral nucleus (thalamus), Visual area 2, Visual area 3, Visual area V6A, area 24, posterior lateral auditory area, superior temporal gyrus

Descendant targets:
Agranular frontal area 2 (= caudal dorsolateral premotor area), Agranular frontal area 7 (= rostral dorsolateral premotor area), Agranular insula, Area 23, Area 23c, Area 24a, Area 24b, Area 24c (rostral part of the cingulate sulcus), Area 26, Area 3, Area 31, Area 6, Area 7a, Area 7b, Area 8B, Area 9, Caudal and medial superior parietal lobule, Central amygdaloid nucleus, lateral part, Cortical area 45, Cortical area 45A, Cortical area 46, Cortical area 9\/46d, Dorsal portion of area 8A, Dysgranular insular cortex, Frontal eye field, Granular insular cortex, Inferior parietal lobule (lateral posterior cortex below the intraparietal sulcus), Lateral intraparietal area, Laterodorsal nucleus (thalamus), Medial area 9, Medial premotor area 6M, Medial superior temporal area, Nucleus caudatus, Nucleus centralis superior lateralis thalami, Nucleus medialis dorsalis thalami, Nucleus pulvinaris medialis thalami, Nucleus pulvinaris oralis thalami, Nucleus pulvinaris thalami, pars oralis, Nucleus reticularis thalami, Nucleus ventralis lateralis thalami, pars caudalis, Nucleus ventralis lateralis thalami, pars postrema, Parietal area PE (cingulate part), Parietal area PG, medial part, Peripheral part of area MT, Premotor area 6 (dorsal part), Presubiculum, Principal Sulcus, Putamen, Putamen; caudal, Putamen; rostral, Rostral superior parietal lobule, SMA - rostral part, Temporal area TF, Temporoparietal cortex, Transitional sensory area, Ventral posterior lateral nucleus (thalamus), Visual area 2, Visual area V6A, area 24, posterior lateral auditory area, superior temporal gyrus, ventral lateral nucleus (thalamus)

Sub-regions:
Area 31, Parietal area PE (cingulate part), Parietal area PG, medial part

---

Region: Parietal area PG, medial part (PGm)

Super-regions:
Parietal area PG, medial part < Medial parietal cortex (= Precuneus) < Dorsal parietal cortex (= SPL and precuneus) < ParietalLobe according to GM-Definition < GM-CerebralCortex < Brain

Sources:
Agranular frontal area 7 (= rostral dorsolateral premotor area), Agranular insula, Anterior medial nucleus, Area 23, Area 23c, Area 26, Area 6 (ventral part), Area 7, Area 7a, Area 8B, Area 9, Caudal and medial superior parietal lobule, Central amygdaloid nucleus, lateral part, Cortical area 45, Cortical area 46, Dysgranular insular cortex, Frontal eye field, Granular insular cortex, Inferior parietal lobule (lateral posterior cortex below the intraparietal sulcus), LGN internal magnocellular layer, Lateral intraparietal area, Medial premotor area 6M, Medial superior temporal area, Nucleus anterior ventralis thalami, Nucleus centralis superior lateralis thalami, Nucleus medialis dorsalis thalami, pars densocellularis, Nucleus medialis dorsalis thalami, pars parvocellularis, Nucleus paracentralis thalami, Nucleus pulvinaris medialis thalami, Nucleus pulvinaris oralis thalami, Nucleus pulvinaris thalami, pars oralis, Nucleus reuniens thalami, Nucleus ventralis lateralis thalami, pars caudalis, Nucleus ventralis lateralis thalami, pars postrema, Parietal area PE (cingulate part), Peripheral part of area MT, Premotor area 6 (dorsal part), Presubiculum,

Principal Sulcus, Rostral superior parietal lobule, SMA - rostral part, Temporal area TF, Temporoparietal asscociated area (caudal part), Temporoparietal associated area (rostral part), Ventral posterior lateral nucleus (thalamus), Visual area 2, Visual area V6A, area 24, posterior lateral auditory area, superior temporal gyrus

Targets:
Agranular frontal area 2 (= caudal dorsolateral premotor area), Agranular frontal area 7 (= rostral dorsolateral premotor area), Agranular insula, Area 23, Area 23c, Area 24a, Area 24b, Area 24c (rostral part of the cingulate sulcus), Area 26, Area 31, Area 6, Area 7a, Area 7b, Area 8B, Area 9, Caudal and medial superior parietal lobule, Central amygdaloid nucleus, lateral part, Cortical area 45, Cortical area 45A, Cortical area 46, Cortical area 9\/46d, Dysgranular insular cortex, Frontal eye field, Granular insular cortex, Inferior parietal lobule (lateral posterior cortex below the intraparietal sulcus), Lateral intraparietal area, Laterodorsal nucleus (thalamus), Medial premotor area 6M, Medial superior temporal area, Nucleus caudatus, Nucleus centralis superior lateralis thalami, Nucleus medialis dorsalis thalami, Nucleus pulvinaris medialis thalami, Nucleus pulvinaris oralis thalami, Nucleus pulvinaris thalami, pars oralis, Nucleus reticularis thalami, Nucleus ventralis lateralis thalami, pars postrema, Parietal area PE (cingulate part), Peripheral part of area MT, Premotor area 6 (dorsal part), Presubiculum, Principal Sulcus, Putamen, Putamen; caudal, Putamen; rostral, Rostral superior parietal lobule, SMA - rostral part, Temporal area TF, Temporoparietal cortex, Transitional sensory area, Ventral posterior lateral nucleus (thalamus), Visual area 2, Visual area V6A, area 24, posterior lateral auditory area, superior temporal gyrus, ventral lateral nucleus (thalamus)

Region: Area 31 (31)

Super-regions:
Area 31 < Medial parietal cortex (= Precuneus) < Dorsal parietal cortex (= SPL and precuneus) < ParietalLobe according to GM-Definition < GM-CerebralCortex < Brain

Sources:
Agranular frontal area 2 (= caudal dorsolateral premotor area), Agranular frontal area 6 (= pre-SMA), Agranular frontal area 7 (= rostral dorsolateral premotor area), Area 1, Area 10, Area 11, Area 23, Area 23a, Area 23b, Area 23c, Area 24a, Area 24c (rostral part of the cingulate sulcus), Area 29, Area 3, Area 36, Area 8B, Area 9, Caudal and medial superior parietal lobule, Caudal auditory parakoniocortex, Caudal inferior parietal lobule, Caudal parietal operculum, Cortical area 46, Cortical area 9\/46d, Dorsal portion of area 8A, LGN layer 2, Medial intraparietal area, Medial premotor area 6M, Medial superior temporal area, Occipitoparietal area, Orbitofrontal area 13, Parietal area PE (cingulate part), Parietal area PG, medial part, Primary motor area, Principal Sulcus, Retrosplenial area 30, SMA - rostral part, Temporal area TF, Temporal area TH, Temporal parietooccipital associated area in superior temporal sulcus, Temporoparietal cortex, Transitional sensory area, Visual area 3, area 24

Targets:
Area 23, Area 23c, Area 8B, Cortical area 46, Dorsal portion of area 8A, Medial area 9, Parietal area PE (cingulate part), Principal Sulcus, SMA - rostral part, Temporoparietal cortex, Transitional sensory area

---
Region: Parietal area PE (cingulate part) (PECg)

Super-regions:
Parietal area PE (cingulate part) < Medial parietal cortex (= Precuneus) < Dorsal parietal cortex (=

SPL and precuneus) < ParietalLobe according to GM-Definition < GM-CerebralCortex < Brain

Sources:
Agranular frontal area 2 (= caudal dorsolateral premotor area), Agranular frontal area 7 (= rostral dorsolateral premotor area), Area 1, Area 23b, Area 23c, Area 24b, Area 24c (rostral part of the cingulate sulcus), Area 3, Area 31, Area 7, Area 7b, Area 8B, Area 9, Caudal and medial superior parietal lobule, Caudal auditory parakoniocortex, Caudal inferior parietal lobule, Caudal parietal operculum, Cortical area 44, Cortical area 46, Dorsal portion of area 8A, Dysgranular insular cortex, Granular insular cortex, Inferior parietal lobule (lateral posterior cortex below the intraparietal sulcus), LGN layer 2, Medial intraparietal area, Medial premotor area 6M, Medial superior temporal area, Midpart of the inferior parietal lobule, Parietal area PG, medial part, Postcentral area 3a, Postcentral area 3b, Primary motor area, Rostral superior parietal lobule, SMA - rostral part, Secondary somatosensory cortex, Temporal parietooccipital associated area in superior temporal sulcus, Temporoparietal cortex, Transitional sensory area, Visual area V6A

Targets:
Agranular frontal area 2 (= caudal dorsolateral premotor area), Agranular frontal area 7 (= rostral dorsolateral premotor area), Area 23c, Area 3, Area 31, Area 7b, Caudal and medial superior parietal lobule, Central amygdaloid nucleus, lateral part, Nucleus caudatus, Nucleus pulvinaris medialis thalami, Nucleus pulvinaris oralis thalami, Nucleus reticularis thalami, Nucleus ventralis lateralis thalami, pars caudalis, Parietal area PG, medial part, Putamen, Putamen; caudal, Putamen; rostral, SMA - rostral part, Transitional sensory area, Ventral posterior lateral nucleus (thalamus), Visual area V6A, posterior lateral auditory area

---
Region: Cingulate gyrus (CgG#2)

Super-regions:
Cingulate gyrus < GM-CerebralCortex < Brain

Descendant sources:
Agranular frontal area 2 (= caudal dorsolateral premotor area), Agranular frontal area 4 (= caudal ventrolateral premotor area), Agranular frontal area 5 (= rostral ventrolateral premotor area), Agranular frontal area 6 (= pre-SMA), Agranular frontal area 7 (= rostral dorsolateral premotor area), Agranular insula, Amygdala, Anterior medial nucleus, Area 1, Area 10, Area 11, Area 12, Area 20, Area 23, Area 23a, Area 23b, Area 23c, Area 24a, Area 24b, Area 24c (rostral part of the cingulate sulcus), Area 25, Area 29, Area 3, Area 31, Area 32, Area 35, Area 36, Area 6, Area 6 (ventral part), Area 7, Area 7b, Area 8, Area 8A, Area 8B, Area 9, Basolateral nucleus of amygdala, CA1 subfield of Ammon`s horn, Caudal and medial superior parietal lobule, Caudal auditory parakoniocortex, Caudal inferior parietal lobule, Caudal parietal operculum, Claustrum, Cortical area 29a-c, Cortical area 45, Cortical area 46, Cortical area 9\/46d, Dorsal portion of area 8A, Dysgranular Temporopolar Cortex, Dysgranular insular cortex, Entorhinal cortex, Extrastriate area OA, Fascia dentata hippocampi, Granular insular cortex, Hypothalamus, Inferior parietal lobule (lateral posterior cortex below the intraparietal sulcus), Inferotemporal area TE, Insula, Intermediate agranula insular cortex, LGN layer 2, Lateral area 12, Lateral auditory field, Lateral auditory parakoniocortex, Lateral intraparietal area, Medial agranular insular cortex, Medial area 11, Medial basal nucleus of the amygdala, Medial intraparietal area, Medial premotor area 6M, Medial superior temporal area, Midpart of the inferior parietal lobule, Motor area 4a, Motor area 4b, Motor area 4c, Nucleus basalis thalami, Nucleus centralis densocellularis thalami, Nucleus centralis latocellularis thalami, Nucleus centralis superior lateralis thalami, Nucleus limitans thalami, Nucleus medialis dorsalis thalami, Nucleus medialis dorsalis thalami, pars caudodorsalis, Nucleus medialis dorsalis thalami, pars densocellularis, Nucleus medialis dorsalis thalami, pars fibrosa, Nucleus medialis dorsalis thalami, pars magnocellularis, Nucleus medialis dorsalis thalami, pars parvocellularis, Nucleus parafascicularis thalami, Nucleus paraventricularis thalami, pars anterior, Nucleus pulvinaris medialis thalami, Nucleus pulvinaris thalami, Nucleus reticularis thalami, Nucleus reuniens thalami,

Nucleus ventralis anterior thalami, pars parvocellularis, Nucleus ventralis lateralis thalami, pars oralis, Occipitoparietal area, Orbital area 10, Orbital area 12, Orbitofrontal area 13, Orbitofrontal area 13a, Orbitofrontal area 14, Orbitofrontal cortex, agranular periallocortical, Orbitofrontal opercular area, Parasubiculum, Parietal area PE (cingulate part), Parietal area PG, medial part, Postcentral area 3a, Postcentral area 3b, Precentral opercular area, Premotor area 6Va, Premotor area 6Vb, Premotor area 6b-beta, Presubiculum, Primary auditory cortex, Primary motor area, Primary motor cortex M1, forelimb area, Primary motor cortex M1, hindlimb area, Primary sensory cortex, Principal Sulcus, Prostriate cortex, Retroinsular area, Retrosplenial area 30, Rostral area 14, Rostral superior parietal lobule, SMA - rostral part, Secondary auditory cortex, Secondary somatosensory cortex, Superior temporal area 1, Superior temporal area 2, Superior temporal area 3, Superior temporal sulcus, Supratemporal cortex, granular, Temporal area TF, Temporal area TH, Temporal parietooccipital associated area in superior temporal sulcus, Temporal proisocortex, Temporoparietal cortex, Temporopolar area TG, Transitional sensory area, Ventral area 46, Ventral intraparietal area, Visual area 2, Visual area 3, area 24, periamygdaloid cortex, prosubiculum, ventral striatal shell

Descendant targets:

Agranular frontal area 2 (= caudal dorsolateral premotor area), Agranular frontal area 3 (= SMA-proper), Agranular frontal area 5 (= rostral ventrolateral premotor area), Agranular frontal area 6 (= pre-SMA), Agranular frontal area 7 (= rostral dorsolateral premotor area), Agranular insula, Anterior medial nucleus, Area 10, Area 11, Area 12, Area 23, Area 23a, Area 23b, Area 23c, Area 24a, Area 24b, Area 24c (rostral part of the cingulate sulcus), Area 25, Area 29, Area 3, Area 31, Area 32, Area 35, Area 36, Area 6, Area 6 (ventral part), Area 7, Area 7a, Area 7b, Area 8, Area 8A, Area 8B, Area 9, Basal amygdaloid nucleus, intermediate part, Basolateral nucleus of amygdala, CA1 subfield of Ammon`s horn, Caudal and medial superior parietal lobule, Caudal inferior parietal lobule, Centrum medianum thalami, Claustrum, Cortical area 29a-c, Cortical area 45, Cortical area 45A, Cortical area 46, Cortical area 9\/46d, Cortical area 9\/46v, Cortical area PGa, Dorsal portion of area 8A, Dysgranular Temporopolar Cortex, Dysgranular insular cortex, Entorhinal cortex, Entorhinal cortex, Fascia dentata hippocampi, Granular insular cortex, Inferior parietal lobule (lateral posterior cortex below the intraparietal sulcus), Inferotemporal area TE, Intermediate agranula insular cortex, Lateral area 11, Lateral area 12, Lateral intraparietal area, Lateral nucleus (amygdala), dorsal division, Lateral nucleus (amygdala), dorsal intermediate division, Lateral nucleus (amygdala), ventral division, Laterodorsal nucleus (thalamus), Medial area 11, Medial area 12, Medial area 9, Medial premotor area 6M, Medial superior temporal area (dorsal), Motor area 4a, Motor area 4b, Nucleus anterior ventralis thalami, Nucleus caudatus, Nucleus caudatus; genu, Nucleus caudatus; tail, Nucleus centralis densocellularis thalami, Nucleus centralis inferior thalami, Nucleus centralis intermedialis thalami, Nucleus centralis latocellularis thalami, Nucleus centralis superior lateralis thalami, Nucleus centralis superior thalami, Nucleus limitans thalami, Nucleus medialis dorsalis thalami, Nucleus medialis dorsalis thalami, pars magnocellularis, Nucleus medialis dorsalis thalami, pars parvocellularis, Nucleus paracentralis thalami, Nucleus parafascicularis thalami, Nucleus parataenialis thalami, Nucleus paraventricularis thalami, pars anterior, Nucleus peripeduncularis thalami, Nucleus pulvinaris medialis thalami, Nucleus pulvinaris thalami, Nucleus reticularis thalami, Nucleus reuniens thalami, Nucleus ventralis anterior thalami, pars magnocellularis, Nucleus ventralis lateralis thalami, pars caudalis, Nucleus ventralis lateralis thalami, pars oralis, Orbital area 10, Orbital area 12, Orbitofrontal area 13, Orbitofrontal area 13, lateral part, Orbitofrontal area 13, medial part, Orbitofrontal area 13a, Orbitofrontal area 14, Orbitofrontal cortex, agranular periallocortical, Orbitofrontal opercular area, Parietal area PE (cingulate part), Parietal area PG, medial part, Piriform cortex, Postcentral area 3a, Posteromedial agranular insular cortex, Precentral opercular area, Prefrontal area 47\/12, Premotor area 6b-beta, Presubiculum, Primary motor area, Primary motor cortex M1, forelimb area, Primary motor cortex M1, hindlimb area, Primary sensory cortex, Principal Sulcus, Pro motor area, Putamen; rostral, Rostral area 12, Rostral area 14, Rostral part of area 36, SMA - rostral part, Secondary somatosensory cortex, Superior temporal area 1, Superior temporal area 2, Superior temporal sulcus, Superior temporal sulcus, dorsal, Supplementary motor cortex M2, forelimb area, Supplementary motor cortex M2, hindlimb area, Temporal area TA, Temporal area TAa, Temporal area TF, Temporal area TF (lateral part), Temporal area TH, Temporal parietooccipital associated area in superior temporal sulcus, Temporal proisocortex, Temporoparietal asscociated area (caudal part), Temporoparietal cortex, Temporopolar area TG, Transitional sensory area, Ventral area 46, Ventral posterior lateral nucleus (thalamus), accessory basal nucleus (amygdala), magnocellular subdivision, area 24, body representation

of MI as defined in KSI03, dorsal area 9, lateral nucleus (amygdala), ventrolateral subdivision, orofacial representation in MI, prosubiculum, ventral anterior nucleus (thalamus), ventral lateral nucleus (thalamus)

Sub-regions:
Area 23, Area 25, Area 26, area 24

Region: area 24 (24)

Super-regions:
area 24 < Cingulate gyrus < GM-CerebralCortex < Brain

Sources:
Agranular frontal area 2 (= caudal dorsolateral premotor area), Agranular frontal area 7 (= rostral dorsolateral premotor area), Agranular insula, Amygdala, Anterior medial nucleus, Area 10, Area 11, Area 12, Area 20, Area 23, Area 23a, Area 23b, Area 23c, Area 29, Area 32, Area 35, Area 36, Area 6, Area 6 (ventral part), Area 7, Area 7b, Area 8A, Area 8B, Area 9, Basolateral nucleus of amygdala, CA1 subfield of Ammon`s horn, Claustrum, Cortical area 45, Cortical area 46, Entorhinal cortex, Granular insular cortex, Hypothalamus, Inferior parietal lobule (lateral posterior cortex below the intraparietal sulcus), Inferotemporal area TE, Insula, Lateral auditory field, Lateral intraparietal area, Medial basal nucleus of the amygdala, Medial premotor area 6M, Motor area 4a, Motor area 4b, Nucleus basalis thalami, Nucleus centralis densocellularis thalami, Nucleus centralis latocellularis thalami, Nucleus centralis superior lateralis thalami, Nucleus limitans thalami, Nucleus medialis dorsalis thalami, Nucleus medialis dorsalis thalami, pars caudodorsalis, Nucleus medialis dorsalis thalami, pars densocellularis, Nucleus medialis dorsalis thalami, pars fibrosa, Nucleus medialis dorsalis thalami, pars parvocellularis, Nucleus parafascicularis thalami, Nucleus paraventricularis thalami, pars anterior, Nucleus pulvinaris medialis thalami, Nucleus pulvinaris thalami, Nucleus reticularis thalami, Nucleus reuniens thalami, Orbital area 12, Orbitofrontal area 13, Orbitofrontal area 14, Orbitofrontal cortex, agranular periallocortical, Orbitofrontal opercular area, Parietal area PG, medial part, Precentral opercular area, Premotor area 6b-beta, Primary motor cortex M1, forelimb area, Primary sensory cortex, Principal Sulcus, Rostral superior parietal lobule, SMA - rostral part, Secondary auditory cortex, Secondary somatosensory cortex, Superior temporal area 3, Superior temporal sulcus, Supratemporal cortex, granular, Temporal area TF, Temporal area TH, Temporal parietooccipital associated area in superior temporal sulcus, Temporal proisocortex, Temporopolar area TG, Ventral area 46, prosubiculum, ventral striatal shell

Descendant sources:
Agranular frontal area 2 (= caudal dorsolateral premotor area), Agranular frontal area 4 (= caudal ventrolateral premotor area), Agranular frontal area 5 (= rostral ventrolateral premotor area), Agranular frontal area 6 (= pre-SMA), Agranular frontal area 7 (= rostral dorsolateral premotor area), Area 10, Area 11, Area 12, Area 23c, Area 24c (rostral part of the cingulate sulcus), Area 32, Area 36, Area 6 (ventral part), Area 7, Area 7b, Area 8A, Area 8B, Area 9, Cortical area 45, Cortical area 46, Fascia dentata hippocampi, Inferior parietal lobule (lateral posterior cortex below the intraparietal sulcus), Intermediate agranula insular cortex, Lateral area 12, Medial agranular insular cortex, Medial area 11, Medial premotor area 6M, Motor area 4c, Nucleus ventralis anterior thalami, pars parvocellularis, Nucleus ventralis lateralis thalami, pars oralis, Orbital area 10, Orbital area 12, Orbitofrontal area 13, Orbitofrontal area 13a, Orbitofrontal area 14, Parasubiculum, Parietal area PG, medial part, Precentral opercular area, Premotor area 6Va, Premotor area 6Vb, Primary motor area, Primary motor cortex M1, forelimb area, Primary motor cortex M1, hindlimb area, Prostriate cortex, Rostral area 14, Rostral superior parietal lobule, Temporal area TH, Temporopolar area TG

Targets:
Agranular insula, Anterior medial nucleus, Area 10, Area 11, Area 12, Area 23, Area 23a, Area 23b, Area 23c, Area 29, Area 31, Area 32, Area 35, Area 36, Area 6, Area 7a, Area 8, Area 8A, Area 8B, Area 9, Basolateral nucleus of amygdala, CA1 subfield of Ammon`s horn, Caudal inferior parietal lobule, Centrum medianum thalami, Claustrum, Cortical area 29a-c, Cortical area 45, Cortical area 46, Cortical area 9\/46d, Dysgranular insular cortex, Entorhinal cortex, Entorhinal cortex, Granular insular cortex, Inferotemporal area TE,

Lateral area 12, Lateral intraparietal area, Lateral nucleus (amygdala), dorsal division, Lateral nucleus (amygdala), dorsal intermediate division, Lateral nucleus (amygdala), ventral division, Medial area 9, Medial premotor area 6M, Motor area 4a, Motor area 4b, Nucleus caudatus, Nucleus caudatus; tail, Nucleus centralis densocellularis thalami, Nucleus centralis inferior thalami, Nucleus centralis intermedialis thalami, Nucleus centralis latocellularis thalami, Nucleus centralis superior lateralis thalami, Nucleus centralis superior thalami, Nucleus limitans thalami, Nucleus medialis dorsalis thalami, Nucleus medialis dorsalis thalami, pars magnocellularis, Nucleus medialis dorsalis thalami, pars parvocellularis, Nucleus paracentralis thalami, Nucleus parafascicularis thalami, Nucleus parataenialis thalami, Nucleus paraventricularis thalami, pars anterior, Nucleus peripeduncularis thalami, Nucleus pulvinaris thalami, Nucleus reticularis thalami, Nucleus reuniens thalami, Nucleus ventralis anterior thalami, pars magnocellularis, Orbital area 12, Orbitofrontal area 13, Orbitofrontal area 14, Orbitofrontal cortex, agranular periallocortical, Orbitofrontal opercular area, Parietal area PG, medial part, Piriform cortex, Precentral opercular area, Prefrontal area 47\/12, Premotor area 6b-beta, Presubiculum, Primary motor cortex M1, forelimb area, Principal Sulcus, Rostral part of area 36, SMA - rostral part, Secondary somatosensory cortex, Superior temporal sulcus, Superior temporal sulcus, dorsal, Temporal area TF, Temporal area TF (lateral part), Temporal area TH, Temporal proisocortex, Temporopolar area TG, Ventral area 46, dorsal area 9, lateral nucleus (amygdala), ventrolateral subdivision, prosubiculum, ventral anterior nucleus (thalamus), ventral lateral nucleus (thalamus)

Descendant targets:
Agranular frontal area 2 (= caudal dorsolateral premotor area), Agranular frontal area 3 (= SMA-proper), Agranular frontal area 5 (= rostral ventrolateral premotor area), Agranular frontal area 6 (= pre-SMA), Agranular frontal area 7 (= rostral dorsolateral premotor area), Area 11, Area 12, Area 23, Area 23a, Area 23b, Area 23c, Area 24a, Area 24b, Area 25, Area 3, Area 31, Area 32, Area 6 (ventral part), Area 7, Area 7b, Area 8A, Area 8B, Area 9, Cortical area 46, Cortical area 9\/46v, Fascia dentata hippocampi, Inferior parietal lobule (lateral posterior cortex below the intraparietal sulcus), Intermediate agranula insular cortex, Lateral area 11, Lateral area 12, Medial area 11, Medial area 12, Medial area 9, Medial premotor area 6M, Medial superior temporal area (dorsal), Nucleus ventralis anterior thalami, pars magnocellularis, Nucleus ventralis lateralis thalami, pars oralis, Orbital area 10, Orbital area 12, Orbitofrontal area 13, lateral part, Orbitofrontal area 13, medial part, Orbitofrontal area 13a, Parietal area PE (cingulate part), Postcentral area 3a, Posteromedial agranular insular cortex, Primary motor area, Primary motor cortex M1, forelimb area, Primary motor cortex M1, hindlimb area, Primary sensory cortex, Pro motor area, Putamen; rostral, Rostral area 12, Rostral area 14, Secondary somatosensory cortex, Supplementary motor cortex M2, forelimb area, Supplementary motor cortex M2, hindlimb area, Transitional sensory area, body representation of MI as defined in KSI03, dorsal area 9, orofacial representation in MI

Sub-regions:
Area 24a, Area 24b, Area 24c (rostral part of the cingulate sulcus), Area 24d (rostral part of the cingulate sulcus)

Region: Area 24c (rostral part of the cingulate sulcus) (24c)

Super-regions:
Area 24c (rostral part of the cingulate sulcus) < area 24 < Cingulate gyrus < GM-CerebralCortex < Brain

Sources:
Agranular frontal area 2 (= caudal dorsolateral premotor area), Agranular frontal area 5 (= rostral ventrolateral premotor area), Agranular frontal area 7 (= rostral dorsolateral premotor area), Area 10, Area 11, Area 12, Area 23c, Area 32, Area 6 (ventral part), Area 7, Area 7b, Area 8A, Area 8B, Area 9, Cortical area 45, Cortical area 46, Fascia dentata hippocampi, Inferior parietal lobule (lateral posterior cortex below the intraparietal sulcus), Lateral area 12, Medial premotor area 6M, Motor area 4c, Orbital area 12, Orbitofrontal area 13, Orbitofrontal area 13a, Orbitofrontal area 14, Parasubiculum, Parietal area PG, medial part, Precentral opercular area, Premotor area 6Va, Premotor area 6Vb, Primary motor area, Prostriate cortex, Rostral superior

parietal lobule, Temporal area TH, Temporopolar area TG

Targets:
Agranular frontal area 2 (= caudal dorsolateral premotor area), Agranular frontal area 3 (= SMA-proper), Agranular frontal area 5 (= rostral ventrolateral premotor area), Agranular frontal area 6 (= pre-SMA), Agranular frontal area 7 (= rostral dorsolateral premotor area), Area 12, Area 23a, Area 23b, Area 23c, Area 24a, Area 24b, Area 25, Area 3, Area 31, Area 32, Area 6 (ventral part), Area 7b, Area 9, Cortical area 46, Fascia dentata hippocampi, Intermediate agranula insular cortex, Lateral area 12, Medial area 12, Medial premotor area 6M, Nucleus ventralis anterior thalami, pars magnocellularis, Orbital area 10, Orbital area 12, Orbitofrontal area 13, medial part, Orbitofrontal area 13a, Parietal area PE (cingulate part), Postcentral area 3a, Primary motor area, Primary motor cortex M1, forelimb area, Primary motor cortex M1, hindlimb area, Primary sensory cortex, Putamen; rostral, Rostral area 12, Supplementary motor cortex M2, forelimb area, Supplementary motor cortex M2, hindlimb area, Transitional sensory area, body representation of MI as defined in KSI03, orofacial representation in MI

Region: Area 24d (rostral part of the cingulate sulcus) (24d)

Super-regions:
Area 24d (rostral part of the cingulate sulcus) < area 24 < Cingulate gyrus < GM-CerebralCortex < Brain

Sources:
Agranular frontal area 2 (= caudal dorsolateral premotor area), Agranular frontal area 4 (= caudal ventrolateral premotor area), Agranular frontal area 5 (= rostral ventrolateral premotor area), Agranular frontal area 6 (= pre-SMA), Agranular frontal area 7 (= rostral dorsolateral premotor area), Area 8A, Cortical area 46, Medial premotor area 6M, Nucleus ventralis anterior thalami, pars parvocellularis, Nucleus ventralis lateralis thalami, pars oralis

Targets:
Agranular frontal area 2 (= caudal dorsolateral premotor area), Agranular frontal area 3 (= SMA-proper), Agranular frontal area 6 (= pre-SMA), Agranular frontal area 7 (= rostral dorsolateral premotor area), Area 7, Cortical area 46, Inferior parietal lobule (lateral posterior cortex below the intraparietal sulcus), Medial area 9, Medial premotor area 6M, Nucleus ventralis anterior thalami, pars magnocellularis, Nucleus ventralis lateralis thalami, pars oralis, Primary motor cortex M1, forelimb area, Primary motor cortex M1, hindlimb area, Pro motor area, Secondary somatosensory cortex, dorsal area 9, orofacial representation in MI

Region: Area 24b (24b)

Super-regions:
Area 24b < area 24 < Cingulate gyrus < GM-CerebralCortex < Brain

Sources:
Agranular frontal area 5 (= rostral ventrolateral premotor area), Area 12, Area 23c, Area 24c (rostral part of the cingulate sulcus), Area 36, Area 6 (ventral part), Area 7, Area 8A, Area 9, Cortical area 46, Fascia dentata hippocampi, Intermediate agranula insular cortex, Medial agranular insular cortex, Medial area 11, Nucleus ventralis anterior thalami, pars parvocellularis, Orbital area 10, Orbitofrontal area 13a, Parietal area PG, medial part, Primary motor cortex M1, forelimb area, Primary motor cortex M1, hindlimb area, Rostral area 14, Rostral superior parietal lobule, Temporal area TH, Temporopolar area TG

Targets:
Agranular frontal area 2 (= caudal dorsolateral premotor area), Agranular frontal area 3 (= SMA-proper), Agranular frontal area 6 (= pre-SMA), Agranular frontal area 7 (= rostral dorsolateral premotor area), Area 11, Area 12, Area 23b, Area 23c, Area 25, Area 32, Area 7, Area 7b, Area 8A, Area 9, Cortical area 46, Fascia dentata

hippocampi, Inferior parietal lobule (lateral posterior cortex below the intraparietal sulcus), Intermediate agranula insular cortex, Lateral area 11, Lateral area 12, Medial area 11, Medial area 12, Medial premotor area 6M, Medial superior temporal area (dorsal), Nucleus ventralis anterior thalami, pars magnocellularis, Nucleus ventralis lateralis thalami, pars oralis, Orbital area 10, Orbital area 12, Orbitofrontal area 13, lateral part, Orbitofrontal area 13, medial part, Orbitofrontal area 13a, Parietal area PE (cingulate part), Postcentral area 3a, Posteromedial agranular insular cortex, Primary motor area, Primary motor cortex M1, forelimb area, Primary sensory cortex, Putamen; rostral, Rostral area 12, Rostral area 14, Supplementary motor cortex M2, forelimb area, Supplementary motor cortex M2, hindlimb area, body representation of MI as defined in KSI03

Region: Area 24a (24a)

Super-regions:
Area 24a < area 24 < Cingulate gyrus < GM-CerebralCortex < Brain

Sources:
Agranular frontal area 5 (= rostral ventrolateral premotor area), Area 12, Area 23c, Area 24c (rostral part of the cingulate sulcus), Area 36, Area 6 (ventral part), Area 7b, Area 8A, Area 9, Cortical area 46, Fascia dentata hippocampi, Intermediate agranula insular cortex, Medial area 11, Orbital area 10, Orbitofrontal area 13a, Parietal area PG, medial part, Rostral area 14, Temporal area TH, Temporopolar area TG

Targets:
Agranular frontal area 2 (= caudal dorsolateral premotor area), Agranular frontal area 5 (= rostral ventrolateral premotor area), Agranular frontal area 6 (= pre-SMA), Agranular frontal area 7 (= rostral dorsolateral premotor area), Area 11, Area 12, Area 23, Area 23b, Area 23c, Area 31, Area 32, Area 7, Area 7b, Area 8A, Area 8B, Area 9, Cortical area 46, Cortical area 9\/46v, Fascia dentata hippocampi, Inferior parietal lobule (lateral posterior cortex below the intraparietal sulcus), Intermediate agranula insular cortex, Lateral area 12, Medial area 11, Medial area 12, Medial superior temporal area (dorsal), Nucleus ventralis anterior thalami, pars magnocellularis, Orbitofrontal area 13a, Rostral area 14

Region: Area 23 (23)

Super-regions:
Area 23 < Cingulate gyrus < GM-CerebralCortex < Brain

Sources:
Area 10, Area 11, Area 24a, Area 31, Area 32, Area 36, Area 7, Area 8B, Area 9, Caudal inferior parietal lobule, Cortical area 46, Cortical area 9\/46d, Dorsal portion of area 8A, Dysgranular insular cortex, Extrastriate area OA, Inferior parietal lobule (lateral posterior cortex below the intraparietal sulcus), Insula, Lateral auditory parakoniocortex, Lateral intraparietal area, Occipitoparietal area, Orbitofrontal area 14, Parietal area PG, medial part, Principal Sulcus, Rostral superior parietal lobule, SMA - rostral part, Superior temporal area 3, Temporal area TF, Temporal area TH, Temporal parietooccipital associated area in superior temporal sulcus, Temporoparietal cortex, Visual area 2, Visual area 3, area 24

Descendant sources:
Agranular frontal area 2 (= caudal dorsolateral premotor area), Agranular frontal area 5 (= rostral ventrolateral premotor area), Agranular frontal area 6 (= pre-SMA), Agranular frontal area 7 (= rostral dorsolateral premotor area), Area 1, Area 10, Area 11, Area 12, Area 20, Area 23a, Area 23b, Area 23c, Area 24a, Area 24b, Area 24c (rostral part of the cingulate sulcus), Area 25, Area 29, Area 3, Area 31, Area 32, Area 36, Area 7b, Area 8, Area 8A, Area 8B, Area 9, Caudal and medial superior parietal lobule, Caudal auditory parakoniocortex, Caudal inferior parietal lobule, Caudal parietal operculum, Cortical area 46, Dorsal portion of area 8A, Dysgranular insular cortex, Extrastriate area OA, Fascia dentata hippocampi, Granular insular cortex, LGN layer 2, Medial intraparietal area, Medial premotor area 6M, Medial superior

temporal area, Midpart of the inferior parietal lobule, Motor area 4c, Nucleus ventralis anterior thalami, pars parvocellularis, Nucleus ventralis lateralis thalami, pars oralis, Occipitoparietal area, Orbital area 12, Orbitofrontal area 13, Orbitofrontal area 14, Parietal area PE (cingulate part), Parietal area PG, medial part, Postcentral area 3a, Postcentral area 3b, Primary motor area, Retroinsular area, Retrosplenial area 30, Rostral superior parietal lobule, Secondary somatosensory cortex, Temporal area TF, Temporal area TH, Temporal parietooccipital associated area in superior temporal sulcus, Temporoparietal cortex, Transitional sensory area, Ventral intraparietal area, Visual area 3, area 24

Targets:
Agranular frontal area 3 (= SMA-proper), Agranular frontal area 6 (= pre-SMA), Agranular frontal area 7 (= rostral dorsolateral premotor area), Anterior medial nucleus, Area 10, Area 11, Area 31, Area 32, Area 36, Area 7, Area 7b, Area 8A, Area 8B, Area 9, Caudal inferior parietal lobule, Cortical area 45A, Cortical area 46, Cortical area 9\/46d, Cortical area PGa, Dorsal portion of area 8A, Entorhinal cortex, Entorhinal cortex, Inferior parietal lobule (lateral posterior cortex below the intraparietal sulcus), Lateral area 12, Lateral intraparietal area, Laterodorsal nucleus (thalamus), Medial area 9, Medial premotor area 6M, Nucleus anterior ventralis thalami, Nucleus caudatus; genu, Nucleus medialis dorsalis thalami, Nucleus pulvinaris medialis thalami, Nucleus ventralis lateralis thalami, pars caudalis, Orbital area 12, Parietal area PG, medial part, Presubiculum, Principal Sulcus, Pro motor area, Rostral part of area 36, SMA - rostral part, Temporal area TA, Temporal area TAa, Temporal area TF, Temporal area TF (lateral part), Temporal area TH, Temporoparietal asscociated area (caudal part), Ventral area 46, Ventral posterior lateral nucleus (thalamus), area 24

Descendant targets:
Agranular frontal area 2 (= caudal dorsolateral premotor area), Agranular frontal area 6 (= pre-SMA), Agranular frontal area 7 (= rostral dorsolateral premotor area), Area 11, Area 23b, Area 23c, Area 24a, Area 24b, Area 24c (rostral part of the cingulate sulcus), Area 25, Area 3, Area 31, Area 32, Area 6 (ventral part), Area 7b, Area 8A, Area 9, Caudal and medial superior parietal lobule, Cortical area 46, Fascia dentata hippocampi, Medial area 11, Medial premotor area 6M, Nucleus ventralis lateralis thalami, pars oralis, Parietal area PE (cingulate part), Parietal area PG, medial part, Primary motor area, Primary motor cortex M1, forelimb area, Primary motor cortex M1, hindlimb area, Supplementary motor cortex M2, forelimb area, Supplementary motor cortex M2, hindlimb area, Transitional sensory area, area 24, body representation of MI as defined in KSI03, orofacial representation in MI

Sub-regions:
Area 23a, Area 23b, Area 23c, Transitional sensory area

Region: Area 23c (23c)

Super-regions:
Area 23c < Area 23 < Cingulate gyrus < GM-CerebralCortex < Brain

Sources:
Agranular frontal area 2 (= caudal dorsolateral premotor area), Agranular frontal area 5 (= rostral ventrolateral premotor area), Agranular frontal area 6 (= pre-SMA), Agranular frontal area 7 (= rostral dorsolateral premotor area), Area 1, Area 10, Area 11, Area 12, Area 23a, Area 23b, Area 24a, Area 24b, Area 24c (rostral part of the cingulate sulcus), Area 25, Area 29, Area 3, Area 31, Area 32, Area 36, Area 7b, Area 8A, Area 8B, Area 9, Caudal and medial superior parietal lobule, Caudal auditory parakoniocortex, Caudal inferior parietal lobule, Caudal parietal operculum, Cortical area 46, Dorsal portion of area 8A, Dysgranular insular cortex, Fascia dentata hippocampi, Granular insular cortex, LGN layer 2, Medial intraparietal area, Medial premotor area 6M, Medial superior temporal area, Midpart of the inferior parietal lobule, Motor area 4c, Nucleus ventralis anterior thalami, pars parvocellularis, Nucleus ventralis lateralis thalami, pars oralis, Occipitoparietal area, Orbital area 12, Orbitofrontal area 13, Orbitofrontal area 14, Parietal area PE (cingulate part), Parietal area PG, medial part, Postcentral area 3a, Postcentral area 3b, Primary motor area, Retrosplenial area 30, Rostral superior parietal lobule, Secondary somatosensory cortex, Temporal area TF,

Temporal area TH, Temporal parietooccipital associated area in superior temporal sulcus, Temporoparietal cortex, Transitional sensory area, Ventral intraparietal area, Visual area 3, area 24

Targets:
Agranular frontal area 2 (= caudal dorsolateral premotor area), Agranular frontal area 6 (= pre-SMA), Agranular frontal area 7 (= rostral dorsolateral premotor area), Area 23b, Area 24a, Area 24b, Area 24c (rostral part of the cingulate sulcus), Area 3, Area 31, Area 6 (ventral part), Area 7b, Area 8A, Caudal and medial superior parietal lobule, Cortical area 46, Fascia dentata hippocampi, Medial premotor area 6M, Nucleus ventralis lateralis thalami, pars oralis, Parietal area PE (cingulate part), Parietal area PG, medial part, Primary motor area, Primary motor cortex M1, forelimb area, Primary motor cortex M1, hindlimb area, Supplementary motor cortex M2, forelimb area, Supplementary motor cortex M2, hindlimb area, Transitional sensory area, area 24, body representation of MI as defined in KSI03, orofacial representation in MI

Region: Area 23b (23b)

Super-regions:
Area 23b < Area 23 < Cingulate gyrus < GM-CerebralCortex < Brain

Sources:
Area 20, Area 23a, Area 23c, Area 24a, Area 24b, Area 24c (rostral part of the cingulate sulcus), Area 36, Area 8, Area 8A, Area 9, Cortical area 46, Extrastriate area OA, Fascia dentata hippocampi, Occipitoparietal area, Orbitofrontal area 13, Orbitofrontal area 14, Temporal area TF, Temporal area TH, Temporal parietooccipital associated area in superior temporal sulcus, area 24

Targets:
Area 11, Area 23c, Area 25, Area 31, Area 32, Area 8A, Area 9, Cortical area 46, Fascia dentata hippocampi, Medial area 11, Parietal area PE (cingulate part), Transitional sensory area, area 24

Region: Transitional sensory area (TSA)

Super-regions:
Transitional sensory area < Area 23 < Cingulate gyrus < GM-CerebralCortex < Brain

Sources:
Agranular frontal area 2 (= caudal dorsolateral premotor area), Agranular frontal area 7 (= rostral dorsolateral premotor area), Area 23b, Area 23c, Area 24c (rostral part of the cingulate sulcus), Area 31, Caudal and medial superior parietal lobule, Caudal inferior parietal lobule, Cortical area 46, Dorsal portion of area 8A, Medial premotor area 6M, Medial superior temporal area, Parietal area PE (cingulate part), Parietal area PG, medial part, Postcentral area 3a, Postcentral area 3b, Primary motor area, Retroinsular area, Rostral superior parietal lobule, Secondary somatosensory cortex, Temporal parietooccipital associated area in superior temporal sulcus, Temporoparietal cortex

Targets:
Area 23c, Area 31, Parietal area PE (cingulate part)

Region: Area 23a (23a)

Super-regions:
Area 23a < Area 23 < Cingulate gyrus < GM-CerebralCortex < Brain

Sources:
Area 24c (rostral part of the cingulate sulcus), Area 36, Area 8A, Area 9, Cortical area 46, Fascia dentata hippocampi, Temporal area TH, area 24

Targets:
Area 11, Area 23b, Area 23c, Area 31, Area 32, Area 8A, Area 9, Cortical area 46, Fascia dentata hippocampi, Medial area 11, area 24

Region: Area 26 (26)

Super-regions:
Area 26 < Cingulate gyrus < GM-CerebralCortex < Brain

Sources:
Lateral intraparietal area, Parietal area PG, medial part

Descendant sources:
Area 9, Cortical area 46, Cortical area 9\/46d, Principal Sulcus, area 24

Targets:
Caudal inferior parietal lobule, Lateral intraparietal area, Parietal area PG, medial part

Descendant targets:
Area 10, Area 11, Area 12, Area 23c, Area 25, Area 31, Area 32, Area 36, Area 8, Area 8B, Area 9, Cortical area 46, Cortical area 9\/46d, Entorhinal cortex, Entorhinal cortex, Inferior parietal lobule (lateral posterior cortex below the intraparietal sulcus), Medial area 11, Medial area 9, Orbitofrontal area 13, Orbitofrontal area 14, Principal Sulcus, Rostral part of area 36, Temporal area TAa, Temporal area TF, Temporal area TF (lateral part), Temporal area TH, Temporal proisocortex, Temporoparietal asscociated area (caudal part), Temporoparietal cortex, area 24

Sub-regions:
Area 29, Retrosplenial area 30

Region: Area 29 (29)

Super-regions:
Area 29 < Area 26 < Cingulate gyrus < GM-CerebralCortex < Brain

Sources:
Principal Sulcus, area 24

Descendant sources:
Area 9, Cortical area 46, Cortical area 9\/46d, Principal Sulcus, area 24

Targets:
Area 10, Area 23c, Area 31, Area 9, Cortical area 46, Cortical area 9\/46d, Inferior parietal lobule (lateral posterior cortex below the intraparietal sulcus), Medial area 9, Principal Sulcus, Temporal area TAa, Temporoparietal asscociated area (caudal part), Temporoparietal cortex, area 24

Descendant targets:
Area 11, Area 12, Area 25, Area 32, Area 36, Area 8, Area 9, Cortical area 46, Entorhinal cortex, Entorhinal cortex, Medial area 11, Orbitofrontal area 13, Orbitofrontal area 14, Principal Sulcus, Rostral part of area 36, Temporal area TF (lateral part), Temporal proisocortex

Sub-regions:
Area 29d, Caudomedial lobule, Cortical area 29a-c

Region: Caudomedial lobule (CML)

Super-regions:
Caudomedial lobule < Area 29 < Area 26 < Cingulate gyrus < GM-CerebralCortex < Brain

Sources:
Principal Sulcus

Targets:
Principal Sulcus

```
        ----------------------------------------------------------------
        Region: Area 29d (29d)
        ----------------------------------------------------------------

           Super-regions:
               Area 29d   <   Area 29   <   Area 26   <   Cingulate
               gyrus   <   GM-CerebralCortex   <   Brain

           Sources:
               Area 9,  Cortical area 9\/46d

           Targets:
               Area 11,  Area 36,  Entorhinal cortex,  Entorhinal
               cortex,  Medial area 11,  Rostral part of area 36,
               Temporal area TF (lateral part)


        ----------------------------------------------------------------
        Region: Cortical area 29a-c (29a-c)
        ----------------------------------------------------------------

           Super-regions:
               Cortical area 29a-c   <   Area 29   <   Area 26   <
               Cingulate gyrus   <   GM-CerebralCortex   <   Brain

           Sources:
               Area 9,  Cortical area 46,  Cortical area 9\/46d,  area
               24

           Targets:
               Area 11,  Area 12,  Area 25,  Area 32,  Area 36,  Area
               8,  Area 9,  Cortical area 46,  Entorhinal cortex,
               Entorhinal cortex,  Medial area 11,  Orbitofrontal area
               13,  Orbitofrontal area 14,  Rostral part of area 36,
               Temporal area TF (lateral part),  Temporal proisocortex


     ----------------------------------------------------------------------
     Region: Retrosplenial area 30 (30)
     ----------------------------------------------------------------------

        Super-regions:
            Retrosplenial area 30   <   Area 26   <   Cingulate gyrus
            <   GM-CerebralCortex   <   Brain

        Sources:
            Area 9,  Cortical area 9\/46d,  Principal Sulcus

        Targets:
            Area 23c,  Area 31,  Area 8B,  Area 9,  Cortical area 46,
            Cortical area 9\/46d,  Entorhinal cortex,  Entorhinal
            cortex,  Inferior parietal lobule (lateral posterior cortex
            below the intraparietal sulcus),  Medial area 11,  Principal
            Sulcus,  Temporal area TAa,  Temporal area TF,  Temporal
            area TF (lateral part),  Temporal area TH,  Temporoparietal
            asscociated area (caudal part),  Temporoparietal cortex


--------------------------------------------------------------------------
Region: Area 25 (25)
--------------------------------------------------------------------------

   Super-regions:
       Area 25   <   Cingulate gyrus   <   GM-CerebralCortex   <   Brain

   Sources:
       Amygdala,  Area 11,  Area 23b,  Area 24b,  Area 24c (rostral part
       of the cingulate sulcus),  Area 32,  Area 35,  Area 36,  Area 9,
       Basolateral nucleus of amygdala,  CA1 subfield of Ammon`s horn,
       Cortical area 29a-c,  Dysgranular Temporopolar Cortex,
       Entorhinal cortex,  Hypothalamus,  Inferotemporal area TE,
       Intermediate agranula insular cortex,  Lateral auditory field,
       Medial agranular insular cortex,  Medial basal nucleus of the
       amygdala,  Nucleus basalis thalami,  Nucleus medialis dorsalis
       thalami,  Nucleus medialis dorsalis thalami, pars
       magnocellularis,  Orbital area 12,  Orbitofrontal area 13,
       Orbitofrontal area 13a,  Orbitofrontal area 14,  Parasubiculum,
       Presubiculum,  Primary auditory cortex,  Primary sensory cortex,
       Principal Sulcus,  Rostral area 14,  Secondary auditory cortex,
       Superior temporal area 1,  Superior temporal area 2,  Superior
       temporal area 3,  Superior temporal sulcus,  Supratemporal
       cortex, granular,  Temporal area TF,  Temporal area TH,
       Temporopolar area TG,  periamygdaloid cortex,  prosubiculum,
       ventral striatal shell

   Targets:
```

Area 10, Area 11, Area 23c, Area 32, Area 36, Basal amygdaloid nucleus, intermediate part, Dysgranular Temporopolar Cortex, Entorhinal cortex, Entorhinal cortex, Intermediate agranula insular cortex, Lateral area 11, Lateral nucleus (amygdala), dorsal division, Lateral nucleus (amygdala), dorsal intermediate division, Lateral nucleus (amygdala), ventral division, Medial area 11, Medial area 9, Nucleus caudatus, Nucleus caudatus; tail, Nucleus medialis dorsalis thalami, Orbital area 12, Orbitofrontal area 13, lateral part, Orbitofrontal area 13, medial part, Orbitofrontal area 13a, Orbitofrontal area 14, Posteromedial agranular insular cortex, Primary sensory cortex, Principal Sulcus, Rostral area 14, Rostral part of area 36, Superior temporal area 1, Superior temporal area 2, Temporal area TF (lateral part), Temporal parietooccipital associated area in superior temporal sulcus, Temporopolar area TG, accessory basal nucleus (amygdala), magnocellular subdivision, dorsal area 9, lateral nucleus (amygdala), ventrolateral subdivision

---

Region: Insula (Insula)

Super-regions:
Insula < GM-CerebralCortex < Brain

Sources:
Corpus geniculatum mediale, Hypothalamus, Lateral auditory field, Nucleus limitans thalami, Nucleus medialis dorsalis thalami, pars parvocellularis, Nucleus paracentralis thalami, Nucleus parafascicularis thalami, Nucleus pulvinaris medialis thalami, Nucleus reuniens thalami, Nucleus supragenicularus thalami, Nucleus ventralis anterior thalami, pars magnocellularis, Nucleus ventralis posterior inferior thalami, Nucleus ventralis posterior medialis thalami, Primary sensory cortex

Descendant sources:
Accessor basal nucleus (amygdala), ventromedial division, Accessory basal amygdaloid nucleus, parvicellular part, Agranular area of temporal polar cortex, Agranular frontal area 5 (= rostral ventrolateral premotor area), Agranular insula, Area 1, Area 24a, Area 24b, Area 24c (rostral part of the cingulate sulcus), Area 25, Area 32, Area 35, Area 36, Area 7b, Area 9, Basal amygdaloid nucleus, intermediate part, Cortical area 45, Dorsal dysgranular area of temporal polar cortex, Dysgranular insular cortex, Entorhinal cortex, Granular area of temporal polar cortex, Granular insular cortex, Gustatory cortex, Hypothalamus, Inferotemporal area TE, Intermediate agranula insular cortex, Intermediate field of entorhinal cortex, LGN external magnocellular layer, LGN layer 2, Lateral agranular insular cortex, Lateral area 11, Lateral area 12, Lateral auditory field, Lateral field (rostral part) of entorhinal cortex, Lateral intraparietal area, Medial agranular insular cortex, Medial area 10, Medial area 11, Medial area 12, Nucleus basalis thalami, Nucleus medialis dorsalis thalami, Nucleus medialis dorsalis thalami, pars caudodorsalis, Nucleus medialis dorsalis thalami, pars fibrosa, Nucleus medialis dorsalis thalami, pars paramediana, Nucleus parafascicularis thalami, Nucleus reuniens thalami, Nucleus ventralis posterior lateralis thalami, pars caudalis, Nucleus ventralis posterior medialis thalami, Olfactory Complex, Olfactory field of entorhinal cortex, Orbital area 10, Orbital area 12, Orbitofrontal area 13, lateral part, Orbitofrontal area 13, medial part, Orbitofrontal area 13a, Parietal area PG, medial part, Piriform cortex, Postcentral area 3b, Posteromedial agranular insular cortex, Precentral opercular area, Premotor area 6Va, Premotor area 6Vb, Primary auditory cortex, Primary sensory cortex, Primary somatosensory cortex, Principal Sulcus, Retroinsular area, Rostral area 14, Rostral field of entorhinal cortex, Rostral inferior parietal lobule, Secondary auditory cortex, Secondary somatosensory cortex, Supratemporal cortex, granular, Temporal area TA, Ventral dysgranular area of temporal polar cortex, accessory basal nucleus (amygdala), magnocellular subdivision, area 24, central nucleus of the amygdala, cortical nucleus, anterior division, periamygdaloid cortex

Targets:
Agranular area of temporal polar cortex, Amygdala, Area 1, Area 23, Area 3, Area 35, Area 6, Centrum medianum thalami, Claustrum, Cortical area 46, Inferotemporal area TE, LGN layer 2, Lateral auditory parakoniocortex, Lateral field of entorhinal cortex, Nucleus medialis dorsalis thalami, pars magnocellularis, Nucleus medialis dorsalis thalami, pars parvocellularis, Nucleus parafascicularis thalami, Nucleus paraventricularis thalami, Nucleus pulvinaris medialis thalami, Nucleus pulvinaris oralis thalami, Nucleus reticularis thalami, Nucleus reuniens thalami, Nucleus subthalamicus, Nucleus ventralis posterior inferior thalami, Nucleus ventralis posterior medialis thalami, Orbital prefrontal cortex, Orbitofrontal cortex, agranular periallocortical, Precentral

opercular area, Primary auditory cortex, Primary somatosensory cortex, Rostral inferior parietal lobule, Secondary auditory cortex, Secondary somatosensory cortex, Superior temporal area 3, Superior temporal sulcus, Supratemporal cortex, granular, Temporoparietal cortex, area 24

Descendant targets:
Agranular area of temporal polar cortex, Agranular frontal area 3 (= SMA-proper), Agranular frontal area 6 (= pre-SMA), Agranular insula, Area 1, Area 10, Area 11, Area 23, Area 23c, Area 24a, Area 24b, Area 25, Area 3, Area 32, Area 35, Area 36, Area 6 (ventral part), Area 7, Area 7b, Area 8A, Basal amygdaloid nucleus, intermediate part, Caudal part of area 36, Cortical area 45, Cortical area 46, Dorsal dysgranular area of temporal polar cortex, Dysgranular Temporopolar Cortex, Dysgranular insular cortex, Entorhinal cortex, Entorhinal cortex, Granular area of temporal polar cortex, Granular insular cortex, Gustatory cortex, Inferotemporal area TE, Intermediate agranula insular cortex, Intermediate field of entorhinal cortex, LGN external magnocellular layer, LGN layer 2, Lateral agranular insular cortex, Lateral area 11, Lateral area 12, Lateral auditory field, Lateral auditory parakoniocortex, Lateral field (rostral part) of entorhinal cortex, Lateral intraparietal area, Lateral nucleus (amygdala), dorsal division, Lateral nucleus (amygdala), dorsal intermediate division, Lateral nucleus (amygdala), ventral division, Medial area 10, Medial area 11, Medial area 12, Medial area 9, Medial premotor area 6M, Nucleus caudatus, Nucleus medialis dorsalis thalami, Nucleus medialis dorsalis thalami, pars fibrosa, Nucleus medialis dorsalis thalami, pars magnocellularis, Nucleus medialis dorsalis thalami, pars paramediana, Olfactory field of entorhinal cortex, Orbital area 10, Orbital area 12, Orbitofrontal area 13, Orbitofrontal area 13, lateral part, Orbitofrontal area 13, medial part, Orbitofrontal area 13a, Orbitofrontal area 14, Parietal area PE (cingulate part), Parietal area PG, medial part, Postcentral area 3a, Posteromedial agranular insular cortex, Precentral opercular area, Premotor area 6Vb, Primary motor area, Primary sensory cortex, Primary somatosensory cortex, Principal Sulcus, Pro motor area, Putamen, Putamen; rostral, Retroinsular area, Rostral area 12, Rostral area 14, Rostral field of entorhinal cortex, Rostral inferior parietal lobule, Rostral part of area 36, Secondary auditory cortex, Secondary somatosensory cortex, Superior temporal area 2, Superior temporal area 3, Superior temporal sulcus, Supratemporal cortex, granular, Temporal area TA, Temporal area TAa, Temporal area TF (lateral part), Temporal area TF (medial part), Temporal area TH, Temporal proisocortex, Temporopolar area TG, Transitional sensory area, Ventral dysgranular area of temporal polar cortex, accessory basal nucleus (amygdala), magnocellular subdivision, area 24, belt line of the sensory system according to CP99, belt line of the sensorymotor system according to CP99, central nucleus of the amygdala, lateral nucleus (amygdala), ventrolateral subdivision, periamygdaloid cortex, superior parietal lobule (posterior dorsomedial parietal cortex above the intraparietal sulcus)

Sub-regions:
Anterior insula, Granular insular cortex, Insular proisocortex, Piriform cortex, Retroinsular area

---
Region: Granular insular cortex (Ig#1)

Super-regions:
Granular insular cortex < Insula < GM-CerebralCortex < Brain

Sources:
Agranular frontal area 5 (= rostral ventrolateral premotor area), Area 1, Area 7b, Dysgranular insular cortex, Hypothalamus, LGN layer 2, Lateral intraparietal area, Parietal area PG, medial part, Postcentral area 3b, Primary sensory cortex, Retroinsular area, Secondary somatosensory cortex, area 24

Targets:
Agranular frontal area 3 (= SMA-proper), Agranular frontal area 6 (= pre-SMA), Area 1, Area 10, Area 11, Area 23c, Area 3, Area 32, Area 36, Area 7, Area 7b, Caudal part of area 36, Cortical area 46, Dysgranular insular cortex, Lateral intraparietal area, Lateral nucleus (amygdala), dorsal division, Lateral nucleus (amygdala), dorsal intermediate division, Lateral nucleus (amygdala), ventral division, Medial area 12, Medial premotor area 6M, Orbital area 12, Parietal area PE (cingulate part), Parietal area PG, medial part, Primary somatosensory cortex, Pro motor area, Retroinsular area, Rostral inferior parietal lobule, Rostral part of area 36, Secondary somatosensory cortex, Temporal area TF (lateral part), Temporal area TF (medial part), Temporal area TH, area 24, lateral nucleus (amygdala), ventrolateral subdivision, superior

parietal lobule (posterior dorsomedial parietal cortex above the intraparietal sulcus)

Region: Retroinsular area (Ri#1)

Super-regions:
Retroinsular area < Insula < GM-CerebralCortex < Brain

Sources:
Area 1, Area 7b, Granular insular cortex, LGN layer 2, Postcentral area 3b, Secondary auditory cortex, Secondary somatosensory cortex

Targets:
Area 1, Area 6 (ventral part), Area 7, Area 7b, Area 8A, Cortical area 46, Granular insular cortex, LGN layer 2, Lateral auditory parakoniocortex, Primary somatosensory cortex, Secondary auditory cortex, Secondary somatosensory cortex, Superior temporal area 3, Transitional sensory area, superior parietal lobule (posterior dorsomedial parietal cortex above the intraparietal sulcus)

Region: Insular proisocortex (IPro)

Super-regions:
Insular proisocortex < Insula < GM-CerebralCortex < Brain

Sources:
Agranular frontal area 5 (= rostral ventrolateral premotor area)

Targets:
Area 3, Pro motor area

Region: Piriform cortex (Pi#1)

Super-regions:
Piriform cortex < Insula < GM-CerebralCortex < Brain

Sources:
Secondary auditory cortex, Supratemporal cortex, granular, area 24

Targets:
Area 32, Area 36, Caudal part of area 36, Dysgranular Temporopolar Cortex, Entorhinal cortex, Entorhinal cortex, Inferotemporal area TE, Intermediate agranula insular cortex, Lateral area 12, Lateral auditory parakoniocortex, Lateral nucleus (amygdala), dorsal division, Lateral nucleus (amygdala), dorsal intermediate division, Lateral nucleus (amygdala), ventral division, Medial area 9, Orbital area 12, Orbitofrontal area 13a, Orbitofrontal area 14, Rostral part of area 36, Secondary auditory cortex, Superior temporal area 2, Superior temporal area 3, Superior temporal sulcus, Supratemporal cortex, granular, Temporal area TA, Temporal area TAa, Temporal area TF (lateral part), Temporal area TF (medial part), Temporal area TH, Temporal proisocortex, Temporopolar area TG, lateral nucleus (amygdala), ventrolateral subdivision

---

Region: Anterior insula (IA#1)

Super-regions:
Anterior insula < Insula < GM-CerebralCortex < Brain

Descendant sources:
Accessor basal nucleus (amygdala), ventromedial division, Accessory basal amygdaloid nucleus, parvicellular part, Agranular area of temporal polar cortex, Agranular frontal area 5 (= rostral ventrolateral premotor area), Agranular insula, Area 24a, Area 24b, Area 24c (rostral part of the cingulate sulcus), Area 25, Area 32, Area 35, Area 36, Area 7b, Area 9, Basal amygdaloid nucleus, intermediate part, Cortical area 45, Dorsal dysgranular area of temporal polar cortex, Dysgranular insular cortex, Entorhinal cortex, Granular area of temporal polar cortex, Granular insular cortex, Gustatory

cortex, Inferotemporal area TE, Intermediate agranula insular cortex, Intermediate field of entorhinal cortex, LGN external magnocellular layer, Lateral agranular insular cortex, Lateral area 11, Lateral area 12, Lateral auditory field, Lateral field (rostral part) of entorhinal cortex, Lateral intraparietal area, Medial agranular insular cortex, Medial area 10, Medial area 11, Medial area 12, Nucleus basalis thalami, Nucleus medialis dorsalis thalami, Nucleus medialis dorsalis thalami, pars caudodorsalis, Nucleus medialis dorsalis thalami, pars fibrosa, Nucleus medialis dorsalis thalami, pars paramediana, Nucleus parafascicularis thalami, Nucleus reuniens thalami, Nucleus ventralis posterior lateralis thalami, pars caudalis, Nucleus ventralis posterior medialis thalami, Olfactory Complex, Olfactory field of entorhinal cortex, Orbital area 10, Orbital area 12, Orbitofrontal area 13, lateral part, Orbitofrontal area 13, medial part, Orbitofrontal area 13a, Parietal area PG, medial part, Piriform cortex, Postcentral area 3b, Posteromedial agranular insular cortex, Precentral opercular area, Premotor area 6Va, Premotor area 6Vb, Primary auditory cortex, Primary somatosensory cortex, Principal Sulcus, Rostral area 14, Rostral field of entorhinal cortex, Rostral inferior parietal lobule, Secondary somatosensory cortex, Temporal area TA, Ventral dysgranular area of temporal polar cortex, accessory basal nucleus (amygdala), magnocellular subdivision, area 24, central nucleus of the amygdala, cortical nucleus, anterior division, periamygdaloid cortex

Descendant targets:
Agranular area of temporal polar cortex, Agranular frontal area 3 (= SMA-proper), Agranular frontal area 6 (= pre-SMA), Agranular insula, Area 10, Area 11, Area 23, Area 23c, Area 24a, Area 24b, Area 25, Area 3, Area 32, Area 35, Area 36, Area 7, Area 7b, Basal amygdaloid nucleus, intermediate part, Caudal part of area 36, Cortical area 45, Cortical area 46, Dorsal dysgranular area of temporal polar cortex, Dysgranular insular cortex, Entorhinal cortex, Entorhinal cortex, Granular area of temporal polar cortex, Granular insular cortex, Gustatory cortex, Inferotemporal area TE, Intermediate agranula insular cortex, Intermediate field of entorhinal cortex, LGN external magnocellular layer, LGN layer 2, Lateral agranular insular cortex, Lateral area 11, Lateral area 12, Lateral auditory field, Lateral field (rostral part) of entorhinal cortex, Lateral intraparietal area, Lateral nucleus (amygdala), dorsal division, Lateral nucleus (amygdala), dorsal intermediate division, Lateral nucleus (amygdala), ventral division, Medial area 10, Medial area 11, Medial area 12, Medial area 9, Medial premotor area 6M, Nucleus caudatus, Nucleus medialis dorsalis thalami, Nucleus medialis dorsalis thalami, pars fibrosa, Nucleus medialis dorsalis thalami, pars magnocellularis, Nucleus medialis dorsalis thalami, pars paramediana, Olfactory field of entorhinal cortex, Orbital area 10, Orbital area 12, Orbitofrontal area 13, Orbitofrontal area 13, lateral part, Orbitofrontal area 13, medial part, Orbitofrontal area 13a, Orbitofrontal area 14, Parietal area PE (cingulate part), Parietal area PG, medial part, Postcentral area 3a, Posteromedial agranular insular cortex, Precentral opercular area, Premotor area 6Vb, Primary motor area, Primary sensory cortex, Principal Sulcus, Pro motor area, Putamen, Putamen; rostral, Rostral area 12, Rostral area 14, Rostral field of entorhinal cortex, Rostral inferior parietal lobule, Rostral part of area 36, Secondary somatosensory cortex, Temporal area TF (lateral part), Temporal area TF (medial part), Temporal area TH, Temporopolar area TG, Ventral dysgranular area of temporal polar cortex, accessory basal nucleus (amygdala), magnocellular subdivision, area 24, belt line of the sensory system according to CP99, belt line of the sensorymotor system according to CP99, central nucleus of the amygdala, lateral nucleus (amygdala), ventrolateral subdivision, periamygdaloid cortex, superior parietal lobule (posterior dorsomedial parietal cortex above the intraparietal sulcus)

Sub-regions:
Agranular insula, Dysgranular insular cortex

Region: Dysgranular insular cortex (Idg)

Super-regions:
Dysgranular insular cortex < Anterior insula < Insula < GM-CerebralCortex < Brain

Sources:
Agranular frontal area 5 (= rostral ventrolateral premotor area), Agranular insula, Area 35, Area 36, Area 7b, Granular insular cortex, Lateral auditory field, Lateral intraparietal area, Nucleus ventralis posterior lateralis

thalami, pars caudalis, Parietal area PG, medial part, Principal Sulcus, Rostral inferior parietal lobule, Secondary somatosensory cortex, area 24

Targets:
Agranular frontal area 3 (= SMA-proper), Agranular frontal area 6 (= pre-SMA), Agranular insula, Area 10, Area 11, Area 23, Area 23c, Area 3, Area 32, Area 35, Area 36, Area 7, Area 7b, Caudal part of area 36, Cortical area 46, Entorhinal cortex, Granular insular cortex, LGN layer 2, Lateral intraparietal area, Lateral nucleus (amygdala), dorsal division, Lateral nucleus (amygdala), dorsal intermediate division, Lateral nucleus (amygdala), ventral division, Medial area 9, Medial premotor area 6M, Nucleus medialis dorsalis thalami, Orbital area 12, Orbitofrontal area 13, Orbitofrontal area 13, lateral part, Orbitofrontal area 14, Parietal area PE (cingulate part), Parietal area PG, medial part, Principal Sulcus, Pro motor area, Rostral inferior parietal lobule, Rostral part of area 36, Secondary somatosensory cortex, Temporal area TF (lateral part), Temporal area TF (medial part), Temporal area TH, Temporopolar area TG, belt line of the sensory system according to CP99, belt line of the sensorymotor system according to CP99, lateral nucleus (amygdala), ventrolateral subdivision, superior parietal lobule (posterior dorsomedial parietal cortex above the intraparietal sulcus)

Region: Agranular insula (Ia#2)

Super-regions:
Agranular insula < Anterior insula < Insula < GM-CerebralCortex < Brain

Sources:
Agranular frontal area 5 (= rostral ventrolateral premotor area), Area 7b, Dysgranular insular cortex, Lateral auditory field, Nucleus basalis thalami, Parietal area PG, medial part, area 24

Descendant sources:
Accessor basal nucleus (amygdala), ventromedial division, Accessory basal amygdaloid nucleus, parvicellular part, Agranular area of temporal polar cortex, Area 24a, Area 24b, Area 24c (rostral part of the cingulate sulcus), Area 25, Area 32, Area 35, Area 9, Basal amygdaloid nucleus, intermediate part, Cortical area 45, Dorsal dysgranular area of temporal polar cortex, Entorhinal cortex, Granular area of temporal polar cortex, Gustatory cortex, Inferotemporal area TE, Intermediate agranula insular cortex, Intermediate field of entorhinal cortex, LGN external magnocellular layer, Lateral agranular insular cortex, Lateral area 11, Lateral area 12, Lateral auditory field, Lateral field (rostral part) of entorhinal cortex, Medial agranular insular cortex, Medial area 10, Medial area 11, Medial area 12, Nucleus basalis thalami, Nucleus medialis dorsalis thalami, Nucleus medialis dorsalis thalami, pars caudodorsalis, Nucleus medialis dorsalis thalami, pars fibrosa, Nucleus medialis dorsalis thalami, pars paramediana, Nucleus parafascicularis thalami, Nucleus reuniens thalami, Nucleus ventralis posterior medialis thalami, Olfactory Complex, Olfactory field of entorhinal cortex, Orbital area 10, Orbital area 12, Orbitofrontal area 13, lateral part, Orbitofrontal area 13, medial part, Orbitofrontal area 13a, Piriform cortex, Postcentral area 3b, Posteromedial agranular insular cortex, Precentral opercular area, Premotor area 6Va, Premotor area 6Vb, Primary auditory cortex, Primary somatosensory cortex, Rostral area 14, Rostral field of entorhinal cortex, Temporal area TA, Ventral dysgranular area of temporal polar cortex, accessory basal nucleus (amygdala), magnocellular subdivision, central nucleus of the amygdala, cortical nucleus, anterior division, periamygdaloid cortex

Targets:
Area 32, Area 36, Area 7b, Basal amygdaloid nucleus, intermediate part, Caudal part of area 36, Cortical area 46, Dysgranular insular cortex, Entorhinal cortex, Entorhinal cortex, Lateral nucleus (amygdala), dorsal division, Lateral nucleus (amygdala), dorsal intermediate division, Lateral nucleus (amygdala), ventral division, Nucleus medialis dorsalis thalami, Nucleus medialis dorsalis thalami, pars magnocellularis, Orbital area 12, Orbitofrontal area 13, Orbitofrontal area 14, Parietal

area PG, medial part, Pro motor area, Rostral inferior parietal lobule, Rostral part of area 36, Temporal area TF (lateral part), Temporal area TF (medial part), Temporal area TH, Temporopolar area TG, accessory basal nucleus (amygdala), magnocellular subdivision, area 24, belt line of the sensory system according to CP99, belt line of the sensorymotor system according to CP99, lateral nucleus (amygdala), ventrolateral subdivision

Descendant targets:
Agranular area of temporal polar cortex, Area 11, Area 24a, Area 24b, Area 25, Area 32, Area 35, Area 36, Basal amygdaloid nucleus, intermediate part, Cortical area 45, Dorsal dysgranular area of temporal polar cortex, Entorhinal cortex, Granular area of temporal polar cortex, Gustatory cortex, Inferotemporal area TE, Intermediate agranula insular cortex, Intermediate field of entorhinal cortex, LGN external magnocellular layer, Lateral agranular insular cortex, Lateral area 11, Lateral area 12, Lateral auditory field, Lateral field (rostral part) of entorhinal cortex, Medial area 10, Medial area 11, Medial area 12, Nucleus caudatus, Nucleus medialis dorsalis thalami, pars fibrosa, Nucleus medialis dorsalis thalami, pars paramediana, Olfactory field of entorhinal cortex, Orbital area 10, Orbital area 12, Orbitofrontal area 13, Orbitofrontal area 13, lateral part, Orbitofrontal area 13, medial part, Orbitofrontal area 13a, Postcentral area 3a, Posteromedial agranular insular cortex, Precentral opercular area, Premotor area 6Vb, Primary motor area, Primary sensory cortex, Putamen, Putamen; rostral, Rostral area 12, Rostral area 14, Rostral field of entorhinal cortex, Ventral dysgranular area of temporal polar cortex, accessory basal nucleus (amygdala), magnocellular subdivision, central nucleus of the amygdala, periamygdaloid cortex

Sub-regions:
Intermediate agranula insular cortex, Lateral agranular insular cortex, Medial agranular insular cortex, Posteromedial agranular insular cortex

---
Region: Lateral agranular insular cortex (Ial)

Super-regions:
Lateral agranular insular cortex < Agranular insula < Anterior insula < Insula < GM-CerebralCortex < Brain

Sources:
Medial agranular insular cortex, Nucleus medialis dorsalis thalami, Nucleus medialis dorsalis thalami, pars fibrosa, Orbitofrontal area 13a

Targets:
Area 11, Gustatory cortex, Intermediate agranula insular cortex, Lateral area 11, Lateral area 12, Medial area 12, Nucleus caudatus, Orbital area 10, Orbital area 12, Orbitofrontal area 13, Orbitofrontal area 13, lateral part, Orbitofrontal area 13, medial part, Orbitofrontal area 13a, Posteromedial agranular insular cortex, Primary sensory cortex, Putamen, Putamen; rostral, Rostral area 12, Rostral area 14

Region: Medial agranular insular cortex (Iam)

Super-regions:
Medial agranular insular cortex < Agranular insula < Anterior insula < Insula < GM-CerebralCortex < Brain

Sources:
Nucleus medialis dorsalis thalami, Nucleus medialis dorsalis thalami, pars fibrosa, Nucleus medialis dorsalis thalami, pars paramediana, Orbitofrontal area 13a, Rostral area 14

Targets:
Agranular area of temporal polar cortex, Area 11, Area 24b, Area 25, Area 32, Area 35, Area 36, Basal amygdaloid nucleus, intermediate part, Cortical area 45, Entorhinal cortex, Granular area of temporal polar cortex, Gustatory cortex, Inferotemporal area

TE, Intermediate agranula insular cortex, LGN external magnocellular layer, Lateral agranular insular cortex, Lateral area 11, Lateral area 12, Lateral auditory field, Lateral field (rostral part) of entorhinal cortex, Medial area 10, Medial area 11, Medial area 12, Nucleus medialis dorsalis thalami, pars fibrosa, Nucleus medialis dorsalis thalami, pars paramediana, Olfactory field of entorhinal cortex, Orbital area 10, Orbital area 12, Orbitofrontal area 13, lateral part, Orbitofrontal area 13, medial part, Orbitofrontal area 13a, Postcentral area 3a, Posteromedial agranular insular cortex, Precentral opercular area, Premotor area 6Vb, Primary motor area, Primary sensory cortex, Putamen; rostral, Rostral area 12, Rostral area 14, Rostral field of entorhinal cortex, Ventral dysgranular area of temporal polar cortex, accessory basal nucleus (amygdala), magnocellular subdivision, central nucleus of the amygdala

---

Region: Posteromedial agranular insular cortex (Iapm)

Super-regions:
Posteromedial agranular insular cortex < Agranular insula < Anterior insula < Insula < GM-CerebralCortex < Brain

Sources:
Accessor basal nucleus (amygdala), ventromedial division, Accessory basal amygdaloid nucleus, parvicellular part, Agranular area of temporal polar cortex, Area 24b, Area 25, Area 35, Basal amygdaloid nucleus, intermediate part, Entorhinal cortex, Granular area of temporal polar cortex, Gustatory cortex, Inferotemporal area TE, Intermediate agranula insular cortex, Intermediate field of entorhinal cortex, LGN external magnocellular layer, Lateral agranular insular cortex, Lateral area 11, Lateral auditory field, Lateral field (rostral part) of entorhinal cortex, Medial agranular insular cortex, Medial area 12, Nucleus parafascicularis thalami, Nucleus reuniens thalami, Nucleus ventralis posterior medialis thalami, Olfactory Complex, Olfactory field of entorhinal cortex, Orbital area 12, Orbitofrontal area 13, lateral part, Orbitofrontal area 13, medial part, Orbitofrontal area 13a, Postcentral area 3b, Precentral opercular area, Primary somatosensory cortex, Rostral area 14, Rostral field of entorhinal cortex, Ventral dysgranular area of temporal polar cortex, accessory basal nucleus (amygdala), magnocellular subdivision, central nucleus of the amygdala, cortical nucleus, anterior division, periamygdaloid cortex

Targets:
Intermediate agranula insular cortex, Medial area 12, Nucleus caudatus, Orbital area 10, Orbital area 12, Orbitofrontal area 13, Orbitofrontal area 13, lateral part, Orbitofrontal area 13, medial part, Orbitofrontal area 13a, Primary sensory cortex, Putamen; rostral, Rostral area 14

Region: Intermediate agranula insular cortex (Iai)

Super-regions:
Intermediate agranula insular cortex < Agranular insula < Anterior insula < Insula < GM-CerebralCortex < Brain

Sources:
Accessor basal nucleus (amygdala), ventromedial division, Accessory basal amygdaloid nucleus, parvicellular part, Agranular area of temporal polar cortex, Area 24a, Area 24b, Area 24c (rostral part of the cingulate sulcus), Area 25, Area 32, Area 35, Area 9, Basal amygdaloid nucleus, intermediate part, Cortical area 45, Dorsal dysgranular area of temporal polar cortex, Entorhinal cortex, Granular area of temporal polar cortex, Inferotemporal area TE, Intermediate field of entorhinal cortex, LGN external magnocellular layer, Lateral agranular insular cortex, Lateral area 12, Lateral auditory field, Lateral

field (rostral part) of entorhinal cortex, Medial agranular insular cortex, Medial area 10, Medial area 11, Nucleus basalis thalami, Nucleus medialis dorsalis thalami, Nucleus medialis dorsalis thalami, pars caudodorsalis, Nucleus medialis dorsalis thalami, pars fibrosa, Nucleus medialis dorsalis thalami, pars paramediana, Olfactory Complex, Olfactory field of entorhinal cortex, Orbital area 10, Orbital area 12, Orbitofrontal area 13, lateral part, Orbitofrontal area 13, medial part, Orbitofrontal area 13a, Piriform cortex, Posteromedial agranular insular cortex, Precentral opercular area, Premotor area 6Va, Premotor area 6Vb, Primary auditory cortex, Rostral area 14, Rostral field of entorhinal cortex, Temporal area TA, Ventral dysgranular area of temporal polar cortex, accessory basal nucleus (amygdala), magnocellular subdivision, cortical nucleus, anterior division, periamygdaloid cortex

Targets:
Agranular area of temporal polar cortex, Area 11, Area 24a, Area 24b, Area 25, Area 32, Area 35, Basal amygdaloid nucleus, intermediate part, Dorsal dysgranular area of temporal polar cortex, Granular area of temporal polar cortex, Intermediate field of entorhinal cortex, LGN external magnocellular layer, Lateral area 11, Lateral area 12, Lateral auditory field, Lateral field (rostral part) of entorhinal cortex, Medial area 10, Medial area 11, Medial area 12, Nucleus caudatus, Olfactory field of entorhinal cortex, Orbital area 10, Orbital area 12, Orbitofrontal area 13, Orbitofrontal area 13, lateral part, Orbitofrontal area 13, medial part, Orbitofrontal area 13a, Posteromedial agranular insular cortex, Primary sensory cortex, Putamen; rostral, Rostral area 14, Rostral field of entorhinal cortex, Ventral dysgranular area of temporal polar cortex, accessory basal nucleus (amygdala), magnocellular subdivision, central nucleus of the amygdala, periamygdaloid cortex

---

Region: Temporal Lobe according to GM-Definition (TL#2)

Super-regions:
Temporal Lobe according to GM-Definition < GM-CerebralCortex < Brain

Descendant sources:
Accessor basal nucleus (amygdala), ventromedial division, Accessory basal amygdaloid nucleus, dorsal division, Accessory basal amygdaloid nucleus, parvicellular part, Accessory basal amygdaloid nucleus, ventral division, Agranular frontal area 5 (= rostral ventrolateral premotor area), Agranular insula, Anterior inferotemporal area (dorsal), Anterior inferotemporal area (ventral), Anterior medial nucleus, Anterior nuclei of the thalamus, Area 10, Area 11, Area 12, Area 20, Area 23, Area 24a, Area 24b, Area 25, Area 29, Area 29d, Area 31, Area 32, Area 35, Area 36, Area 6, Area 6 (ventral part), Area 7, Area 7a, Area 7b, Area 8, Area 8A, Area 8B, Area 9, Basal amygdaloid nucleus, intermediate part, Basal amygdaloid nucleus, ventral lateral division, Basolateral nucleus of amygdala, CA1 subfield of Ammon`s horn, CA3 subfield of Ammons horn, Caudal area 8A, Caudal auditory parakoniocortex, Caudal inferior parietal lobule, Caudal limiting field of entorhinal cortex, Caudal part of area 36, Central amygdaloid nucleus, lateral part, Central inferotemporal area, Central inferotemporal area (dorsal), Central inferotemporal area (ventral), Centrum medianum thalami, Claustrum, Corpus geniculatum mediale, Cortical amygdaloid nucleus, Cortical area 29a-c, Cortical area 36p, Cortical area 45, Cortical area 45A, Cortical area 45B, Cortical area 46, Cortical area 9\/46d, Cortical area OAa, Cortical area PGa, Cortical area TEm, Dorsal area 46, Dorsal prelunate gyrus, Dorsal visual area 3, Dysgranular Temporopolar Cortex, Dysgranular insular cortex, Entorhinal cortex, Entorhinal cortex, Extrastriate area OA, Floor of superior temporal sulcus, Frontal eye field, Granular insular cortex, Hippocampus, Hypothalamus, Inferior parietal lobule (lateral posterior cortex below the intraparietal sulcus), Inferotemporal area TE, Insula, Intermediate agranula insular cortex, Intermediate field of entorhinal cortex, Intraparietal sulcus associated area in the superior temporal sulcus, LGN external magnocellular layer, Lateral Geniculate Nucleus, Lateral area 12, Lateral auditory field, Lateral auditory field, Lateral auditory parakoniocortex, Lateral field (caudal part) of entorhinal cortex, Lateral field (rostral part) of entorhinal cortex, Lateral field of entorhinal cortex, Lateral intraparietal area, Lateral intraparietal area (external part), Lateral intraparietal area (internal part), Lateral nucleus

(amygdala), dorsal division, Laterodorsal nucleus (thalamus), Medial agranular insular cortex, Medial area 11, Medial area 9, Medial basal nucleus of the amygdala, Medial basal nucleus of the amygdala, Medial intraparietal area, Medial premotor area 6M, Medial superior temporal area, Medial superior temporal area (dorsal), Medial superior temporal area (posterior), Middle temporal area, Midline nuclei of the thalamus, Nucleus basalis thalami, Nucleus centralis densocellularis thalami, Nucleus dorsalis tegmenti, Nucleus limitans thalami, Nucleus medialis dorsalis thalami, Nucleus medialis dorsalis thalami, pars densocellularis, Nucleus of the lateral olfactory tract, Nucleus paracentralis thalami, Nucleus parafascicularis thalami, Nucleus paraventricularis thalami, Nucleus paraventricularis thalami, pars anterior, Nucleus peripeduncularis thalami, Nucleus pulvinaris inferior thalami, Nucleus pulvinaris inferior thalami, central subdivision, Nucleus pulvinaris inferior thalami, lateral subdivision, Nucleus pulvinaris inferior thalami, pars medialis, Nucleus pulvinaris inferior thalami, pars posterior, Nucleus pulvinaris lateralis thalami pars ventrolateralis, Nucleus pulvinaris lateralis thalami pars ventromedialis, Nucleus pulvinaris medialis thalami, Nucleus pulvinaris oralis thalami, Nucleus pulvinaris thalami, Nucleus pulvinaris thalami, pars oralis, Nucleus reuniens thalami, Nucleus supragenicularus thalami, Nucleus ventralis anterior thalami, pars magnocellularis, Nucleus ventralis posterior inferior thalami, Occipitoparietal area, Olfactory Complex, Olfactory field of entorhinal cortex, Orbital area 12, Orbital prefrontal cortex, Orbitofrontal area 13, Orbitofrontal area 13a, Orbitofrontal area 14, Orbitofrontal cortex, agranular periallocortical, Parahippocampal cortex, Parasubiculum, Parietal area PG, medial part, Periamygdaloid cortex 2, Piriform cortex, Posterior inferotemporal area, Posterior inferotemporal area (dorsal), Posterior inferotemporal area (ventral), Posterior intraparietal area, Posterior parietal area, Precentral opercular area, Premotor area 6 (dorsal part), Presubiculum, Primary auditory cortex, Primary sensory cortex, Principal Sulcus, Prostriate cortex, Putamen; rostral, Retroinsular area, Retrosplenial area 30, Rostral area 14, Rostral field of entorhinal cortex, Rostral part of area 36, Rostral superior parietal lobule, Secondary auditory cortex, Secondary somatosensory cortex, Superior temporal area 1, Superior temporal area 2, Superior temporal area 3, Superior temporal sulcus, Superior temporal sulcus, dorsal, Supratemporal cortex, granular, Temporal area TA, Temporal area TAa, Temporal area TF, Temporal area TF (lateral part), Temporal area TF (medial part), Temporal area TH, Temporal parietooccipital associated area in superior temporal sulcus, Temporal proisocortex, Temporoparietal asscociated area (caudal part), Temporoparietal associated area (intermediate part), Temporoparietal associated area (rostral part), Temporoparietal cortex, Temporopolar area TG, V4 transitional area, Ventral area 46, Ventral intraparietal area, Ventral occipitotemporal area, Ventral posterior lateral nucleus (thalamus), Ventral visual area 3, Visual area 1, Visual area 2, Visual area 3, Visual area 3A, Visual area 4, Visual area 4 (dorsal part), Visual area 4 (ventral part), Visual area V6A, accessory basal nucleus (amygdala), magnocellular subdivision, amygdalohippocampal area, anterior amygdaloid area, anterior lateral auditory belt, area 24, auditory prokoniocortex, caudal lateral auditory (belt), central nucleus of the amygdala, cortical nucleus (amygdala), cortical nucleus, anterior division, cortical nucleus, posterior division, lateral nucleus (amygdala), ventrolateral subdivision, medial entorhinal cortex, periamygdaloid cortex, posterior lateral auditory area, prosubiculum, superior temporal gyrus, temporal visual association area in the lower bank of the superior temporal sulcus, ventral striatal shell

Descendant targets:

Accessory basal amygdaloid nucleus, parvicellular part, Agranular area of temporal polar cortex, Agranular frontal area 2 (= caudal dorsolateral premotor area), Agranular frontal area 4 (= caudal ventrolateral premotor area), Agranular frontal area 5 (= rostral ventrolateral premotor area), Agranular frontal area 6 (= pre-SMA), Agranular frontal area 7 (= rostral dorsolateral premotor area), Anterior inferotemporal area (dorsal), Anterior inferotemporal area (ventral), Area 10, Area 11, Area 12, Area 20, Area 23, Area 23a, Area 23b, Area 23c, Area 24a, Area 24b, Area 24c (rostral part of the cingulate sulcus), Area 25, Area 31, Area 32, Area 35, Area 36, Area 6, Area 6 (ventral part), Area 6 (ventral part), Area 7, Area 7a, Area 7b, Area 8, Area 8A, Area 8B, Area 9, Basal amygdaloid nucleus, intermediate part, Basolateral nucleus of amygdala, CA1 subfield of Ammon`s horn, CA3 subfield of Ammons horn, Caudal and medial superior parietal lobule, Caudal auditory parakoniocortex, Caudal inferior parietal lobule, Caudal limiting field of entorhinal cortex, Caudal part of area 36, Central amygdaloid nucleus, lateral part, Central inferotemporal area, Central inferotemporal area (dorsal), Central inferotemporal area (ventral), Claustrum, Corpus geniculatum mediale, Cortical area 36p, Cortical area 45, Cortical area 45A, Cortical area 45B, Cortical area 46, Cortical area 9\/46d, Cortical area OAa, Cortical area PGa, Cortical area TEm, Dorsal area 46, Dorsal portion of area 8A, Dorsal prelunate gyrus, Dorsal visual area 3, Dysgranular

Temporopolar Cortex, Dysgranular insular cortex, Entorhinal cortex, Entorhinal cortex, Extrastriate area OA, Floor of superior temporal sulcus, Frontal eye field, Granular area of temporal polar cortex, Hippocampus, Inferior parietal lobule (lateral posterior cortex below the intraparietal sulcus), Inferotemporal area TE, Intermediate agranula insular cortex, Intermediate field of entorhinal cortex, Intraparietal sulcus associated area in the superior temporal sulcus, LGN external magnocellular layer, Lateral area 11, Lateral area 12, Lateral auditory field, Lateral auditory field, Lateral auditory parakoniocortex, Lateral field (caudal part) of entorhinal cortex, Lateral field (rostral part) of entorhinal cortex, Lateral field of entorhinal cortex, Lateral intraparietal area, Lateral intraparietal area (external part), Lateral intraparietal area (internal part), Lateral nucleus (amygdala), dorsal division, Lateral nucleus (amygdala), dorsal intermediate division, Lateral nucleus (amygdala), ventral division, Laterodorsal nucleus (thalamus), Medial area 11, Medial area 12, Medial area 9, Medial basal nucleus of the amygdala, Medial basal nucleus of the amygdala, Medial premotor area 6M, Medial superior temporal area (dorsal), Medial superior temporal area (posterior), Middle temporal area, Nucleus anterior ventralis thalami, Nucleus basalis thalami, Nucleus caudatus, Nucleus caudatus; genu, Nucleus caudatus; tail, Nucleus centralis superior lateralis thalami, Nucleus dorsalis tegmenti, Nucleus limitans thalami, Nucleus medialis dorsalis thalami, Nucleus medialis dorsalis thalami, pars fibrosa, Nucleus medialis dorsalis thalami, pars magnocellularis, Nucleus medialis dorsalis thalami, pars paramediana, Nucleus medialis dorsalis thalami, pars parvocellularis, Nucleus of the lateral olfactory tract, Nucleus paracentralis thalami, Nucleus parataenialis thalami, Nucleus paraventricularis thalami, Nucleus peripeduncularis thalami, Nucleus pulvinaris inferior thalami, Nucleus pulvinaris inferior thalami, central subdivision, Nucleus pulvinaris inferior thalami, lateral subdivision, Nucleus pulvinaris inferior thalami, pars medialis, Nucleus pulvinaris inferior thalami, pars posterior, Nucleus pulvinaris lateralis thalami pars ventrolateralis, Nucleus pulvinaris lateralis thalami pars ventromedialis, Nucleus pulvinaris lateralis thalami, dorsal division, Nucleus pulvinaris medialis thalami, Nucleus pulvinaris medialis thalami, lateral division, Nucleus pulvinaris medialis thalami, medial division, Nucleus pulvinaris oralis thalami, Nucleus pulvinaris thalami, pars oralis, Nucleus reticularis thalami, Nucleus reuniens thalami, Nucleus supragenicularus thalami, Occipitoparietal area, Olfactory Complex, Olfactory field of entorhinal cortex, Orbital area 10, Orbital area 12, Orbitofrontal area 13, Orbitofrontal area 13, lateral part, Orbitofrontal area 13, medial part, Orbitofrontal area 13a, Orbitofrontal area 14, Parasubiculum, Parietal area PE (cingulate part), Parietal area PG, medial part, Periamygdaloid cortex 2, Piriform cortex, Posterior inferotemporal area, Posterior inferotemporal area (dorsal), Posterior inferotemporal area (ventral), Posterior intraparietal area, Posterior parietal area, Posteromedial agranular insular cortex, Prefrontal area 47\/12, Premotor area 6 (dorsal part), Presubiculum, Primary auditory cortex, Primary motor area, Principal Sulcus, Putamen, Putamen; caudal, Putamen; rostral, Retroinsular area, Rostral area 12, Rostral area 14, Rostral field of entorhinal cortex, Rostral part of area 36, Secondary auditory cortex, Superior temporal area 1, Superior temporal area 2, Superior temporal area 3, Superior temporal sulcus, Supratemporal cortex, granular, Temporal area TA, Temporal area TAa, Temporal area TF, Temporal area TF (lateral part), Temporal area TF (medial part), Temporal area TH, Temporal parietooccipital associated area in superior temporal sulcus, Temporal proisocortex, Temporoparietal asscociated area (caudal part), Temporoparietal associated area (intermediate part), Temporoparietal associated area (rostral part), Temporoparietal cortex, Temporopolar area TG, Transitional sensory area, V4 transitional area, Ventral area 46, Ventral intraparietal area, Ventral posterior lateral nucleus (thalamus), Ventral visual area 3, Visual area 1, Visual area 2, Visual area 3, Visual area 3A, Visual area 4, accessory basal nucleus (amygdala), magnocellular subdivision, amygdalohippocampal area, anterior amygdaloid area, area 24, auditory prokoniocortex, central nucleus of the amygdala, cortical nucleus (amygdala), cortical nucleus, anterior division, cortical nucleus, posterior division, dorsal area 9, lateral nucleus (amygdala), ventrolateral subdivision, medial entorhinal cortex, posterior lateral auditory area, prosubiculum, superior parietal lobule (posterior dorsomedial parietal cortex above the intraparietal sulcus), temporal visual association area in the lower bank of the superior temporal sulcus, ventral striatal shell

Sub-regions:
Hippocampus, Inferotemporal area TE, Parahippocampal cortex, Superior temporal sulcus, Ventral temporal cortex (anterior part of lateral occipito-temporal cortex = fusiform gyrus), superior temporal gyrus

---

Region: Ventral temporal cortex (anterior part of lateral occipito-temporal cortex = fusiform gyrus) (TCv)

Super-regions:
Ventral temporal cortex (anterior part of lateral occipito-temporal cortex = fusiform gyrus) < Temporal Lobe according to GM-Definition < GM-CerebralCortex < Brain

Descendant sources:
Accessory basal amygdaloid nucleus, parvicellular part, Agranular insula, Anterior inferotemporal area (dorsal), Anterior inferotemporal area (ventral), Anterior medial nucleus, Area 10, Area 11, Area 12, Area 23, Area 25, Area 29d, Area 32, Area 35, Area 36, Area 6, Area 7a, Area 8, Area 9, Basal amygdaloid nucleus, intermediate part, Basolateral nucleus of amygdala, CA1 subfield of Ammon`s horn, Caudal limiting field of entorhinal cortex, Caudal part of area 36, Central inferotemporal area, Claustrum, Cortical area 29a-c, Cortical area 36p, Cortical area 45, Cortical area 46, Cortical area OAa, Cortical area PGa, Cortical area TEm, Dysgranular Temporopolar Cortex, Dysgranular insular cortex, Entorhinal cortex, Entorhinal cortex, Extrastriate area OA, Floor of superior temporal sulcus, Granular insular cortex, Hippocampus, Hypothalamus, Inferior parietal lobule (lateral posterior cortex below the intraparietal sulcus), Inferotemporal area TE, Insula, Intermediate agranula insular cortex, Intermediate field of entorhinal cortex, Intraparietal sulcus associated area in the superior temporal sulcus, LGN external magnocellular layer, Lateral auditory field, Lateral field of entorhinal cortex, Lateral intraparietal area, Lateral nucleus (amygdala), dorsal division, Medial agranular insular cortex, Medial area 11, Medial basal nucleus of the amygdala, Medial basal nucleus of the amygdala, Middle temporal area, Midline nuclei of the thalamus, Nucleus basalis thalami, Nucleus centralis densocellularis thalami, Nucleus limitans thalami, Nucleus medialis dorsalis thalami, pars densocellularis, Nucleus of the lateral olfactory tract, Nucleus parafascicularis thalami, Nucleus paraventricularis thalami, pars anterior, Nucleus pulvinaris medialis thalami, Nucleus pulvinaris thalami, Nucleus reuniens thalami, Nucleus supragenicularus thalami, Olfactory Complex, Olfactory field of entorhinal cortex, Orbital area 12, Orbital prefrontal cortex, Orbitofrontal area 13, Orbitofrontal area 13a, Orbitofrontal area 14, Orbitofrontal cortex, agranular periallocortical, Parahippocampal cortex, Parasubiculum, Parietal area PG, medial part, Periamygdaloid cortex 2, Piriform cortex, Posterior inferotemporal area, Precentral opercular area, Presubiculum, Primary auditory cortex, Primary sensory cortex, Prostriate cortex, Retrosplenial area 30, Rostral area 14, Rostral field of entorhinal cortex, Rostral part of area 36, Secondary somatosensory cortex, Superior temporal area 1, Superior temporal area 2, Superior temporal area 3, Superior temporal sulcus, Superior temporal sulcus, dorsal, Temporal area TA, Temporal area TAa, Temporal area TF, Temporal area TH, Temporal parietooccipital associated area in superior temporal sulcus, Temporal proisocortex, Temporoparietal asscociated area (caudal part), Temporoparietal associated area (rostral part), Ventral visual area 3, Visual area 2, Visual area 3, Visual area 4, accessory basal nucleus (amygdala), magnocellular subdivision, amygdalohippocampal area, anterior amygdaloid area, area 24, central nucleus of the amygdala, cortical nucleus (amygdala), cortical nucleus, anterior division, cortical nucleus, posterior division, lateral nucleus (amygdala), ventrolateral subdivision, medial entorhinal cortex, periamygdaloid cortex, posterior lateral auditory area, prosubiculum, superior temporal gyrus, temporal visual association area in the lower bank of the superior temporal sulcus, ventral striatal shell

Descendant targets:
Accessory basal amygdaloid nucleus, parvicellular part, Agranular area of temporal polar cortex, Anterior inferotemporal area (dorsal), Anterior inferotemporal area (ventral), Area 10, Area 11, Area 12, Area 23, Area 23a, Area 23b, Area 23c, Area 24a, Area 24b, Area 24c (rostral part of the cingulate sulcus), Area 25, Area 31, Area 32, Area 35, Area 36, Area 7a, Area 7b, Area 8, Area 8B, Area 9, Basal amygdaloid nucleus, intermediate part, Basolateral nucleus of amygdala, CA1 subfield of Ammon`s horn, Caudal inferior parietal lobule, Caudal limiting field of entorhinal cortex, Caudal part of area 36, Central inferotemporal area, Central inferotemporal area (ventral), Corpus geniculatum mediale, Cortical area 46, Dysgranular insular cortex, Entorhinal cortex, Entorhinal cortex, Extrastriate area OA, Floor of superior temporal sulcus, Granular area of temporal polar cortex, Inferotemporal area TE, Intermediate agranula insular cortex, Intermediate field of entorhinal cortex, LGN external magnocellular layer, Lateral area 11, Lateral area 12, Lateral auditory field, Lateral auditory parakoniocortex, Lateral field (caudal part) of

entorhinal cortex, Lateral field (rostral part) of entorhinal cortex, Lateral field of entorhinal cortex, Lateral intraparietal area, Lateral nucleus (amygdala), dorsal division, Lateral nucleus (amygdala), dorsal intermediate division, Lateral nucleus (amygdala), ventral division, Laterodorsal nucleus (thalamus), Medial area 11, Medial area 12, Medial area 9, Medial basal nucleus of the amygdala, Medial superior temporal area (dorsal), Nucleus basalis thalami, Nucleus caudatus, Nucleus caudatus; genu, Nucleus caudatus; tail, Nucleus centralis superior lateralis thalami, Nucleus dorsalis tegmenti, Nucleus medialis dorsalis thalami, Nucleus medialis dorsalis thalami, pars magnocellularis, Nucleus medialis dorsalis thalami, pars parvocellularis, Nucleus of the lateral olfactory tract, Nucleus parataenialis thalami, Nucleus pulvinaris medialis thalami, Nucleus pulvinaris thalami, pars oralis, Nucleus reuniens thalami, Olfactory Complex, Olfactory field of entorhinal cortex, Orbital area 10, Orbital area 12, Orbitofrontal area 13, Orbitofrontal area 13, lateral part, Orbitofrontal area 13, medial part, Orbitofrontal area 13a, Orbitofrontal area 14, Parietal area PG, medial part, Periamygdaloid cortex 2, Posterior inferotemporal area, Posterior inferotemporal area (ventral), Posteromedial agranular insular cortex, Prefrontal area 47\/12, Presubiculum, Putamen, Putamen; caudal, Putamen; rostral, Rostral area 14, Rostral field of entorhinal cortex, Rostral part of area 36, Secondary auditory cortex, Superior temporal area 1, Superior temporal area 2, Superior temporal area 3, Superior temporal sulcus, Temporal area TA, Temporal area TAa, Temporal area TF, Temporal area TF (lateral part), Temporal area TF (medial part), Temporal area TH, Temporoparietal asscociated area (caudal part), Temporoparietal associated area (rostral part), Temporoparietal cortex, Temporopolar area TG, Ventral visual area 3, Visual area 1, Visual area 2, Visual area 3, Visual area 4, accessory basal nucleus (amygdala), magnocellular subdivision, amygdalohippocampal area, anterior amygdaloid area, area 24, central nucleus of the amygdala, cortical nucleus (amygdala), cortical nucleus, anterior division, cortical nucleus, posterior division, dorsal area 9, lateral nucleus (amygdala), ventrolateral subdivision, medial entorhinal cortex, prosubiculum, superior parietal lobule (posterior dorsomedial parietal cortex above the intraparietal sulcus), ventral striatal shell

Sub-regions:
Nucleus peripeduncularis thalami, Temporal area TF

Region: Temporal area TF (TF)

Super-regions:
Temporal area TF < Ventral temporal cortex (anterior part of lateral occipito-temporal cortex = fusiform gyrus) < Temporal Lobe according to GM-Definition < GM-CerebralCortex < Brain

Sources:
Accessory basal amygdaloid nucleus, parvicellular part, Anterior inferotemporal area (dorsal), Anterior inferotemporal area (ventral), Area 23, Area 36, Area 7a, Area 9, Basal amygdaloid nucleus, intermediate part, CA1 subfield of Ammon`s horn, Caudal limiting field of entorhinal cortex, Central inferotemporal area, Cortical area 46, Cortical area OAa, Cortical area PGa, Entorhinal cortex, Entorhinal cortex, Extrastriate area OA, Floor of superior temporal sulcus, Hippocampus, Inferior parietal lobule (lateral posterior cortex below the intraparietal sulcus), Intermediate field of entorhinal cortex, Intraparietal sulcus associated area in the superior temporal sulcus, Lateral auditory field, Lateral field of entorhinal cortex, Lateral intraparietal area, Nucleus basalis thalami, Nucleus pulvinaris medialis thalami, Nucleus pulvinaris thalami, Olfactory field of entorhinal cortex, Orbitofrontal area 13a, Parasubiculum, Parietal area PG, medial part, Posterior inferotemporal area, Presubiculum, Prostriate cortex, Retrosplenial area 30, Rostral field of entorhinal cortex, Temporal area TAa, Temporal area TH, Temporal proisocortex, Temporoparietal asscociated area (caudal part), Temporoparietal associated area (rostral part), Ventral visual area 3, Visual area 2, Visual area 3, Visual area 4, accessory basal nucleus (amygdala), magnocellular subdivision, anterior amygdaloid area, area 24, cortical nucleus, posterior division, periamygdaloid cortex, prosubiculum, temporal visual association area in the lower bank of the superior temporal sulcus

Descendant sources:
Agranular insula, Anterior inferotemporal area (dorsal), Area 10, Area 11, Area 12, Area 23, Area 25, Area 29d, Area 32, Area 35, Area 6, Area 8, Area 9, CA1 subfield of Ammon`s horn, Caudal limiting field of entorhinal cortex, Caudal part of area 36, Cortical area 29a-c, Cortical area 45, Cortical area 46, Dysgranular insular cortex, Entorhinal cortex, Granular insular cortex, Inferotemporal area TE, Intermediate field of entorhinal cortex, Lateral field of entorhinal cortex, Orbitofrontal area 13, Orbitofrontal area 14, Piriform cortex, Posterior inferotemporal area, Precentral opercular area, Retrosplenial area 30, Rostral field of entorhinal cortex, Rostral part of area 36, Secondary somatosensory cortex, Superior temporal sulcus, dorsal, Temporal area TH, Temporal proisocortex, Visual area 4, area 24, prosubiculum, superior temporal gyrus, ventral striatal shell

Targets:
Accessory basal amygdaloid nucleus, parvicellular part, Anterior inferotemporal area (dorsal), Anterior inferotemporal area (ventral), Area 23, Area 23b, Area 23c, Area 25, Area 31, Area 32, Area 35, Area 36, Area 7a, Area 8B, Basal amygdaloid nucleus, intermediate part, CA1 subfield of Ammon`s horn, Caudal limiting field of entorhinal cortex, Caudal part of area 36, Central inferotemporal area, Central inferotemporal area (ventral), Cortical area 46, Entorhinal cortex, Entorhinal cortex, Extrastriate area OA, Floor of superior temporal sulcus, Inferotemporal area TE, Intermediate field of entorhinal cortex, Lateral area 12, Lateral auditory field, Lateral field (caudal part) of entorhinal cortex, Lateral field (rostral part) of entorhinal cortex, Lateral field of entorhinal cortex, Lateral intraparietal area, Lateral nucleus (amygdala), dorsal division, Lateral nucleus (amygdala), dorsal intermediate division, Lateral nucleus (amygdala), ventral division, Laterodorsal nucleus (thalamus), Medial area 11, Medial area 9, Medial superior temporal area (dorsal), Nucleus basalis thalami, Nucleus caudatus, Nucleus caudatus; genu, Nucleus caudatus; tail, Nucleus medialis dorsalis thalami, Nucleus pulvinaris medialis thalami, Nucleus pulvinaris thalami, pars oralis, Olfactory field of entorhinal cortex, Orbital area 12, Orbitofrontal area 13a, Parietal area PG, medial part, Posterior inferotemporal area, Posterior inferotemporal area (ventral), Presubiculum, Putamen, Putamen; rostral, Rostral area 14, Rostral field of entorhinal cortex, Rostral part of area 36, Temporal area TH, Temporoparietal asscociated area (caudal part), Temporoparietal associated area (rostral part), Temporoparietal cortex, Temporopolar area TG, Ventral visual area 3, Visual area 1, Visual area 2, Visual area 3, Visual area 4, accessory basal nucleus (amygdala), magnocellular subdivision, area 24, central nucleus of the amygdala, lateral nucleus (amygdala), ventrolateral subdivision, prosubiculum, superior parietal lobule (posterior dorsomedial parietal cortex above the intraparietal sulcus)

Descendant targets:
CA1 subfield of Ammon`s horn, prosubiculum

Sub-regions:
Temporal area TF (lateral part), Temporal area TF (medial part)

Region: Temporal area TF (medial part) (TFM)

Super-regions:
Temporal area TF (medial part) < Temporal area TF < Ventral temporal cortex (anterior part of lateral occipito-temporal cortex = fusiform gyrus) < Temporal Lobe according to GM-Definition < GM-CerebralCortex < Brain

Sources:
Agranular insula, Anterior inferotemporal area (dorsal), Area 10, Area 11, Area 12, Area 35, Area 6, Area 8, Area 9, CA1 subfield of Ammon`s horn, Caudal limiting field of entorhinal cortex, Caudal part of area 36, Cortical area 45, Cortical area 46, Dysgranular insular cortex, Entorhinal cortex, Granular insular cortex, Inferotemporal area TE, Intermediate field of entorhinal cortex, Lateral field

of entorhinal cortex, Orbitofrontal area 13, Orbitofrontal area 14, Piriform cortex, Posterior inferotemporal area, Rostral field of entorhinal cortex, Rostral part of area 36, Secondary somatosensory cortex, Superior temporal sulcus, dorsal, Temporal area TH, Temporal proisocortex, Visual area 4, prosubiculum, superior temporal gyrus, ventral striatal shell

Targets:
CA1 subfield of Ammon`s horn

Region: Temporal area TF (lateral part) (TFL)

Super-regions:
Temporal area TF (lateral part) < Temporal area TF < Ventral temporal cortex (anterior part of lateral occipito-temporal cortex = fusiform gyrus) < Temporal Lobe according to GM-Definition < GM-CerebralCortex < Brain

Sources:
Agranular insula, Anterior inferotemporal area (dorsal), Area 10, Area 11, Area 12, Area 23, Area 25, Area 29d, Area 32, Area 35, Area 6, Area 8, Area 9, CA1 subfield of Ammon`s horn, Caudal limiting field of entorhinal cortex, Caudal part of area 36, Cortical area 29a-c, Cortical area 45, Cortical area 46, Dysgranular insular cortex, Entorhinal cortex, Granular insular cortex, Inferotemporal area TE, Intermediate field of entorhinal cortex, Lateral field of entorhinal cortex, Orbitofrontal area 13, Orbitofrontal area 14, Piriform cortex, Posterior inferotemporal area, Precentral opercular area, Retrosplenial area 30, Rostral field of entorhinal cortex, Rostral part of area 36, Secondary somatosensory cortex, Superior temporal sulcus, dorsal, Temporal area TH, Temporal proisocortex, Visual area 4, area 24, prosubiculum, superior temporal gyrus

Targets:
CA1 subfield of Ammon`s horn, prosubiculum

Region: Nucleus peripeduncularis thalami (Per#1)

Super-regions:
Nucleus peripeduncularis thalami < Ventral temporal cortex (anterior part of lateral occipito-temporal cortex = fusiform gyrus) < Temporal Lobe according to GM-Definition < GM-CerebralCortex < Brain

Sources:
Anterior inferotemporal area (dorsal), Anterior inferotemporal area (ventral), Central inferotemporal area, Medial basal nucleus of the amygdala, Nucleus basalis thalami, Posterior inferotemporal area, area 24

Descendant sources:
Accessory basal amygdaloid nucleus, parvicellular part, Agranular insula, Anterior inferotemporal area (dorsal), Anterior inferotemporal area (ventral), Anterior medial nucleus, Area 10, Area 11, Area 12, Area 23, Area 25, Area 29d, Area 32, Area 35, Area 6, Area 8, Area 9, Basal amygdaloid nucleus, intermediate part, Basolateral nucleus of amygdala, CA1 subfield of Ammon`s horn, Caudal limiting field of entorhinal cortex, Caudal part of area 36, Claustrum, Cortical area 29a-c, Cortical area 36p, Cortical area 45, Cortical area 46, Cortical area OAa, Cortical area PGa, Cortical area TEm, Dysgranular Temporopolar Cortex, Dysgranular insular cortex, Entorhinal cortex, Entorhinal cortex, Extrastriate area OA, Granular insular cortex, Hippocampus, Hypothalamus, Inferior parietal lobule (lateral posterior cortex below the intraparietal sulcus), Inferotemporal area TE, Insula, Intermediate agranula insular cortex, Intermediate field of entorhinal cortex, Intraparietal sulcus associated area in the superior temporal sulcus, LGN external magnocellular layer, Lateral auditory field, Lateral field of entorhinal cortex, Lateral nucleus (amygdala), dorsal division, Medial agranular insular cortex, Medial area 11, Medial basal nucleus of the amygdala, Medial basal nucleus of the

amygdala, Middle temporal area, Midline nuclei of the thalamus, Nucleus basalis thalami, Nucleus centralis densocellularis thalami, Nucleus limitans thalami, Nucleus medialis dorsalis thalami, pars densocellularis, Nucleus of the lateral olfactory tract, Nucleus parafascicularis thalami, Nucleus paraventricularis thalami, pars anterior, Nucleus pulvinaris medialis thalami, Nucleus reuniens thalami, Nucleus supragenicularus thalami, Olfactory Complex, Olfactory field of entorhinal cortex, Orbital area 12, Orbital prefrontal cortex, Orbitofrontal area 13, Orbitofrontal area 13a, Orbitofrontal area 14, Orbitofrontal cortex, agranular periallocortical, Parahippocampal cortex, Parasubiculum, Periamygdaloid cortex 2, Piriform cortex, Posterior inferotemporal area, Precentral opercular area, Presubiculum, Primary auditory cortex, Primary sensory cortex, Rostral area 14, Rostral field of entorhinal cortex, Rostral part of area 36, Secondary somatosensory cortex, Superior temporal area 1, Superior temporal area 2, Superior temporal area 3, Superior temporal sulcus, Superior temporal sulcus, dorsal, Temporal area TA, Temporal area TAa, Temporal area TF, Temporal area TH, Temporal parietooccipital associated area in superior temporal sulcus, Temporal proisocortex, Temporoparietal asscociated area (caudal part), Temporoparietal associated area (rostral part), accessory basal nucleus (amygdala), magnocellular subdivision, amygdalohippocampal area, anterior amygdaloid area, area 24, central nucleus of the amygdala, cortical nucleus (amygdala), cortical nucleus, anterior division, lateral nucleus (amygdala), ventrolateral subdivision, medial entorhinal cortex, periamygdaloid cortex, posterior lateral auditory area, prosubiculum, superior temporal gyrus

Targets:
Anterior inferotemporal area (dorsal), Anterior inferotemporal area (ventral), Central inferotemporal area, Nucleus medialis dorsalis thalami, Posterior inferotemporal area

Descendant targets:
Accessory basal amygdaloid nucleus, parvicellular part, Agranular area of temporal polar cortex, Anterior inferotemporal area (dorsal), Anterior inferotemporal area (ventral), Area 10, Area 11, Area 12, Area 23, Area 23a, Area 23b, Area 23c, Area 24a, Area 24b, Area 24c (rostral part of the cingulate sulcus), Area 25, Area 31, Area 32, Area 35, Area 36, Area 7b, Area 8, Area 9, Basal amygdaloid nucleus, intermediate part, Basolateral nucleus of amygdala, CA1 subfield of Ammon`s horn, Caudal inferior parietal lobule, Caudal limiting field of entorhinal cortex, Caudal part of area 36, Central inferotemporal area (ventral), Corpus geniculatum mediale, Dysgranular insular cortex, Entorhinal cortex, Entorhinal cortex, Floor of superior temporal sulcus, Granular area of temporal polar cortex, Inferotemporal area TE, Intermediate agranula insular cortex, Intermediate field of entorhinal cortex, LGN external magnocellular layer, Lateral area 11, Lateral area 12, Lateral auditory field, Lateral auditory parakoniocortex, Lateral field (caudal part) of entorhinal cortex, Lateral field (rostral part) of entorhinal cortex, Lateral field of entorhinal cortex, Lateral nucleus (amygdala), dorsal division, Lateral nucleus (amygdala), dorsal intermediate division, Lateral nucleus (amygdala), ventral division, Medial area 11, Medial area 12, Medial area 9, Medial basal nucleus of the amygdala, Nucleus basalis thalami, Nucleus caudatus, Nucleus caudatus; tail, Nucleus centralis superior lateralis thalami, Nucleus dorsalis tegmenti, Nucleus medialis dorsalis thalami, Nucleus medialis dorsalis thalami, pars magnocellularis, Nucleus medialis dorsalis thalami, pars parvocellularis, Nucleus of the lateral olfactory tract, Nucleus parataenialis thalami, Nucleus pulvinaris medialis thalami, Nucleus reuniens thalami, Olfactory Complex, Olfactory field of entorhinal cortex, Orbital area 10, Orbital area 12, Orbitofrontal area 13, Orbitofrontal area 13, lateral part, Orbitofrontal area 13, medial part, Orbitofrontal area 13a, Orbitofrontal area 14, Periamygdaloid cortex 2, Posterior inferotemporal area, Posteromedial agranular insular cortex, Prefrontal area 47\/12, Putamen; caudal, Putamen; rostral, Rostral area 14, Rostral field of entorhinal cortex, Rostral part of area 36, Secondary auditory cortex, Superior temporal area 1, Superior temporal area 2, Superior temporal area 3, Superior temporal sulcus, Temporal area TA, Temporal area TAa, Temporal area TF, Temporal area TF (lateral part), Temporal area TF (medial part), Temporal area TH, Temporoparietal cortex, accessory basal nucleus (amygdala),

magnocellular subdivision, amygdalohippocampal area, anterior amygdaloid area, area 24, central nucleus of the amygdala, cortical nucleus (amygdala), cortical nucleus, anterior division, cortical nucleus, posterior division, dorsal area 9, lateral nucleus (amygdala), ventrolateral subdivision, medial entorhinal cortex, ventral striatal shell

Sub-regions:
Area 35, Area 36

Region: Area 35 (35)

Super-regions:
Area 35 < Nucleus peripeduncularis thalami < Ventral temporal cortex (anterior part of lateral occipito-temporal cortex = fusiform gyrus) < Temporal Lobe according to GM-Definition < GM-CerebralCortex < Brain

Sources:
Accessory basal amygdaloid nucleus, parvicellular part, Anterior inferotemporal area (dorsal), Anterior inferotemporal area (ventral), Basolateral nucleus of amygdala, Claustrum, Cortical area 36p, Dysgranular insular cortex, Entorhinal cortex, Hippocampus, Inferior parietal lobule (lateral posterior cortex below the intraparietal sulcus), Insula, Intermediate agranula insular cortex, Intermediate field of entorhinal cortex, Lateral auditory field, Medial agranular insular cortex, Medial basal nucleus of the amygdala, Nucleus basalis thalami, Orbitofrontal area 13, Orbitofrontal area 13a, Superior temporal sulcus, Temporal area TF, anterior amygdaloid area, area 24, prosubiculum, superior temporal gyrus

Targets:
Anterior inferotemporal area (dorsal), Anterior inferotemporal area (ventral), Area 10, Area 25, Area 32, Area 36, Basal amygdaloid nucleus, intermediate part, CA1 subfield of Ammon`s horn, Caudal limiting field of entorhinal cortex, Caudal part of area 36, Dysgranular insular cortex, Entorhinal cortex, Entorhinal cortex, Inferotemporal area TE, Intermediate agranula insular cortex, Intermediate field of entorhinal cortex, Lateral area 11, Lateral auditory field, Lateral field (rostral part) of entorhinal cortex, Lateral nucleus (amygdala), dorsal division, Lateral nucleus (amygdala), dorsal intermediate division, Lateral nucleus (amygdala), ventral division, Medial area 9, Nucleus basalis thalami, Nucleus caudatus, Nucleus caudatus; tail, Nucleus dorsalis tegmenti, Nucleus medialis dorsalis thalami, Nucleus medialis dorsalis thalami, pars magnocellularis, Nucleus pulvinaris medialis thalami, Olfactory field of entorhinal cortex, Orbital area 12, Orbitofrontal area 13, Orbitofrontal area 13, medial part, Orbitofrontal area 13a, Orbitofrontal area 14, Posterior inferotemporal area, Posteromedial agranular insular cortex, Putamen; rostral, Rostral field of entorhinal cortex, Rostral part of area 36, Temporal area TF (lateral part), Temporal area TF (medial part), Temporal area TH, Temporoparietal cortex, accessory basal nucleus (amygdala), magnocellular subdivision, area 24, lateral nucleus (amygdala), ventrolateral subdivision, medial entorhinal cortex

---
Region: Area 36 (36)

Super-regions:
Area 36 < Nucleus peripeduncularis thalami < Ventral temporal cortex (anterior part of lateral occipito-temporal cortex = fusiform gyrus) < Temporal Lobe according to GM-Definition < GM-CerebralCortex < Brain

Sources:
Agranular insula, Anterior inferotemporal area (dorsal), Anterior inferotemporal area (ventral), Area 11, Area 12, Area 23, Area 25, Area 29d, Area 32, Area 35, Area 6, Area 8, CA1 subfield of

Ammon`s horn, Cortical area 29a-c, Cortical area 45, Cortical area 46, Cortical area OAa, Cortical area PGa, Dysgranular insular cortex, Extrastriate area OA, Granular insular cortex, Inferior parietal lobule (lateral posterior cortex below the intraparietal sulcus), Inferotemporal area TE, Intraparietal sulcus associated area in the superior temporal sulcus, Lateral auditory field, Medial agranular insular cortex, Medial area 11, Middle temporal area, Nucleus basalis thalami, Orbitofrontal area 13, Orbitofrontal area 13a, Orbitofrontal area 14, Piriform cortex, Posterior inferotemporal area, Precentral opercular area, Secondary somatosensory cortex, Superior temporal sulcus, dorsal, Temporal area TAa, Temporal area TF, Temporal area TH, Temporoparietal asscociated area (caudal part), Temporoparietal associated area (rostral part), area 24, superior temporal gyrus

Descendant sources:
Accessory basal amygdaloid nucleus, parvicellular part, Agranular insula, Anterior inferotemporal area (dorsal), Anterior inferotemporal area (ventral), Anterior medial nucleus, Area 10, Area 11, Area 12, Area 23, Area 25, Area 29d, Area 32, Area 35, Area 6, Area 8, Area 9, Basal amygdaloid nucleus, intermediate part, Basolateral nucleus of amygdala, CA1 subfield of Ammon`s horn, Caudal limiting field of entorhinal cortex, Caudal part of area 36, Claustrum, Cortical area 29a-c, Cortical area 36p, Cortical area 45, Cortical area 46, Cortical area PGa, Cortical area TEm, Dysgranular Temporopolar Cortex, Dysgranular insular cortex, Entorhinal cortex, Entorhinal cortex, Granular insular cortex, Hippocampus, Hypothalamus, Inferotemporal area TE, Insula, Intermediate agranula insular cortex, Intermediate field of entorhinal cortex, LGN external magnocellular layer, Lateral auditory field, Lateral field of entorhinal cortex, Lateral nucleus (amygdala), dorsal division, Medial agranular insular cortex, Medial area 11, Medial basal nucleus of the amygdala, Medial basal nucleus of the amygdala, Midline nuclei of the thalamus, Nucleus basalis thalami, Nucleus centralis densocellularis thalami, Nucleus limitans thalami, Nucleus medialis dorsalis thalami, pars densocellularis, Nucleus of the lateral olfactory tract, Nucleus parafascicularis thalami, Nucleus paraventricularis thalami, pars anterior, Nucleus pulvinaris medialis thalami, Nucleus reuniens thalami, Nucleus supragenicularus thalami, Olfactory Complex, Olfactory field of entorhinal cortex, Orbital area 12, Orbital prefrontal cortex, Orbitofrontal area 13, Orbitofrontal area 13a, Orbitofrontal area 14, Orbitofrontal cortex, agranular periallocortical, Parahippocampal cortex, Parasubiculum, Periamygdaloid cortex 2, Piriform cortex, Posterior inferotemporal area, Precentral opercular area, Presubiculum, Primary auditory cortex, Primary sensory cortex, Rostral area 14, Rostral field of entorhinal cortex, Rostral part of area 36, Secondary somatosensory cortex, Superior temporal area 1, Superior temporal area 2, Superior temporal area 3, Superior temporal sulcus, Superior temporal sulcus, dorsal, Temporal area TA, Temporal area TAa, Temporal area TF, Temporal area TH, Temporal parietooccipital associated area in superior temporal sulcus, Temporal proisocortex, Temporoparietal asscociated area (caudal part), Temporoparietal associated area (rostral part), accessory basal nucleus (amygdala), magnocellular subdivision, amygdalohippocampal area, anterior amygdaloid area, area 24, central nucleus of the amygdala, cortical nucleus (amygdala), cortical nucleus, anterior division, lateral nucleus (amygdala), ventrolateral subdivision, medial entorhinal cortex, periamygdaloid cortex, posterior lateral auditory area, superior temporal gyrus

Targets:
Accessory basal amygdaloid nucleus, parvicellular part, Anterior inferotemporal area (ventral), Area 23, Area 23a, Area 23b, Area 23c, Area 24a, Area 24b, Area 25, Area 31, Basal amygdaloid nucleus, intermediate part, CA1 subfield of Ammon`s horn, Caudal limiting field of entorhinal cortex, Dysgranular insular cortex, Entorhinal cortex, Entorhinal cortex, Floor of superior temporal sulcus, Inferotemporal area TE, Intermediate field of entorhinal cortex, LGN external

magnocellular layer, Lateral area 12, Lateral auditory field, Lateral field of entorhinal cortex, Lateral nucleus (amygdala), dorsal division, Lateral nucleus (amygdala), dorsal intermediate division, Lateral nucleus (amygdala), ventral division, Nucleus medialis dorsalis thalami, Nucleus medialis dorsalis thalami, pars magnocellularis, Nucleus of the lateral olfactory tract, Olfactory Complex, Olfactory field of entorhinal cortex, Orbital area 12, Orbitofrontal area 13, Orbitofrontal area 13, lateral part, Orbitofrontal area 13a, Orbitofrontal area 14, Periamygdaloid cortex 2, Posterior inferotemporal area, Prefrontal area 47\/12, Rostral field of entorhinal cortex, Temporal area TAa, Temporal area TF, accessory basal nucleus (amygdala), magnocellular subdivision, amygdalohippocampal area, anterior amygdaloid area, area 24, central nucleus of the amygdala, cortical nucleus, anterior division, cortical nucleus, posterior division, lateral nucleus (amygdala), ventrolateral subdivision, ventral striatal shell

Descendant targets:
Accessory basal amygdaloid nucleus, parvicellular part, Agranular area of temporal polar cortex, Anterior inferotemporal area (dorsal), Anterior inferotemporal area (ventral), Area 10, Area 11, Area 12, Area 24a, Area 24b, Area 24c (rostral part of the cingulate sulcus), Area 25, Area 32, Area 35, Area 7b, Area 8, Area 9, Basal amygdaloid nucleus, intermediate part, Basolateral nucleus of amygdala, Caudal inferior parietal lobule, Caudal limiting field of entorhinal cortex, Caudal part of area 36, Central inferotemporal area (ventral), Corpus geniculatum mediale, Entorhinal cortex, Entorhinal cortex, Granular area of temporal polar cortex, Inferotemporal area TE, Intermediate agranula insular cortex, Intermediate field of entorhinal cortex, LGN external magnocellular layer, Lateral area 11, Lateral area 12, Lateral auditory field, Lateral auditory parakoniocortex, Lateral field (caudal part) of entorhinal cortex, Lateral field (rostral part) of entorhinal cortex, Lateral field of entorhinal cortex, Lateral nucleus (amygdala), dorsal division, Lateral nucleus (amygdala), dorsal intermediate division, Lateral nucleus (amygdala), ventral division, Medial area 11, Medial area 12, Medial area 9, Medial basal nucleus of the amygdala, Nucleus basalis thalami, Nucleus caudatus, Nucleus caudatus; tail, Nucleus centralis superior lateralis thalami, Nucleus medialis dorsalis thalami, Nucleus medialis dorsalis thalami, pars magnocellularis, Nucleus medialis dorsalis thalami, pars parvocellularis, Nucleus of the lateral olfactory tract, Nucleus parataenialis thalami, Nucleus pulvinaris medialis thalami, Nucleus reuniens thalami, Olfactory Complex, Olfactory field of entorhinal cortex, Orbital area 10, Orbital area 12, Orbitofrontal area 13, Orbitofrontal area 13, medial part, Orbitofrontal area 13a, Orbitofrontal area 14, Periamygdaloid cortex 2, Posterior inferotemporal area, Posteromedial agranular insular cortex, Putamen; caudal, Putamen; rostral, Rostral area 14, Rostral field of entorhinal cortex, Rostral part of area 36, Secondary auditory cortex, Superior temporal area 1, Superior temporal area 2, Superior temporal area 3, Superior temporal sulcus, Temporal area TA, Temporal area TF, Temporal area TF (lateral part), Temporal area TF (medial part), Temporal area TH, accessory basal nucleus (amygdala), magnocellular subdivision, anterior amygdaloid area, area 24, central nucleus of the amygdala, cortical nucleus (amygdala), cortical nucleus, anterior division, dorsal area 9, lateral nucleus (amygdala), ventrolateral subdivision

Sub-regions:
Caudal part of area 36, Rostral part of area 36, Temporopolar area TG

Region: Caudal part of area 36 (36c)

Super-regions:
Caudal part of area 36 < Area 36 < Nucleus peripeduncularis thalami < Ventral temporal cortex (anterior part of lateral occipito-temporal

cortex = fusiform gyrus) < Temporal Lobe according to GM-Definition < GM-CerebralCortex < Brain

Sources:
Accessory basal amygdaloid nucleus, parvicellular part, Agranular insula, Anterior inferotemporal area (dorsal), Anterior inferotemporal area (ventral), Area 35, Basal amygdaloid nucleus, intermediate part, CA1 subfield of Ammon`s horn, Caudal limiting field of entorhinal cortex, Cortical area 36p, Dysgranular insular cortex, Entorhinal cortex, Entorhinal cortex, Granular insular cortex, Hippocampus, Inferotemporal area TE, Intermediate field of entorhinal cortex, Lateral auditory field, Lateral field of entorhinal cortex, Nucleus basalis thalami, Olfactory field of entorhinal cortex, Orbitofrontal area 13, Orbitofrontal area 13a, Periamygdaloid cortex 2, Piriform cortex, Posterior inferotemporal area, Rostral field of entorhinal cortex, Rostral part of area 36, Superior temporal sulcus, dorsal, Temporal area TF, Temporal area TH, Temporal proisocortex, anterior amygdaloid area, periamygdaloid cortex, superior temporal gyrus

Targets:
Anterior inferotemporal area (ventral), Basal amygdaloid nucleus, intermediate part, Caudal limiting field of entorhinal cortex, Entorhinal cortex, Entorhinal cortex, Intermediate field of entorhinal cortex, Lateral auditory field, Lateral field of entorhinal cortex, Lateral nucleus (amygdala), dorsal division, Lateral nucleus (amygdala), dorsal intermediate division, Lateral nucleus (amygdala), ventral division, Nucleus basalis thalami, Rostral field of entorhinal cortex, Rostral part of area 36, Temporal area TF (lateral part), Temporal area TF (medial part), Temporal area TH, accessory basal nucleus (amygdala), magnocellular subdivision, lateral nucleus (amygdala), ventrolateral subdivision

---
Region: Rostral part of area 36 (36r)

Super-regions:
Rostral part of area 36 < Area 36 < Nucleus peripeduncularis thalami < Ventral temporal cortex (anterior part of lateral occipito-temporal cortex = fusiform gyrus) < Temporal Lobe according to GM-Definition < GM-CerebralCortex < Brain

Sources:
Accessory basal amygdaloid nucleus, parvicellular part, Agranular insula, Anterior inferotemporal area (dorsal), Anterior inferotemporal area (ventral), Area 10, Area 11, Area 12, Area 23, Area 25, Area 29d, Area 32, Area 35, Area 6, Area 8, Area 9, Basal amygdaloid nucleus, intermediate part, Caudal limiting field of entorhinal cortex, Caudal part of area 36, Cortical area 29a-c, Cortical area 45, Cortical area 46, Dysgranular insular cortex, Entorhinal cortex, Entorhinal cortex, Granular insular cortex, Hippocampus, Inferotemporal area TE, Intermediate field of entorhinal cortex, LGN external magnocellular layer, Lateral auditory field, Lateral field of entorhinal cortex, Lateral nucleus (amygdala), dorsal division, Nucleus basalis thalami, Nucleus of the lateral olfactory tract, Olfactory field of entorhinal cortex, Orbitofrontal area 13, Orbitofrontal area 14, Periamygdaloid cortex 2, Piriform cortex, Posterior inferotemporal area, Precentral opercular area, Rostral field of entorhinal cortex, Secondary somatosensory cortex, Superior temporal sulcus, dorsal, Temporal area TF, Temporal area TH, Temporal proisocortex, accessory basal nucleus (amygdala), magnocellular subdivision, amygdalohippocampal area, anterior amygdaloid area, area 24, central nucleus of the amygdala, cortical

nucleus, anterior division, lateral nucleus (amygdala), ventrolateral subdivision, periamygdaloid cortex, superior temporal gyrus

Targets:
Accessory basal amygdaloid nucleus, parvicellular part, Anterior inferotemporal area (dorsal), Anterior inferotemporal area (ventral), Basal amygdaloid nucleus, intermediate part, Caudal part of area 36, Entorhinal cortex, Entorhinal cortex, Intermediate field of entorhinal cortex, Lateral auditory field, Lateral field of entorhinal cortex, Lateral nucleus (amygdala), dorsal division, Lateral nucleus (amygdala), dorsal intermediate division, Lateral nucleus (amygdala), ventral division, Nucleus basalis thalami, Nucleus of the lateral olfactory tract, Olfactory Complex, Olfactory field of entorhinal cortex, Periamygdaloid cortex 2, Rostral field of entorhinal cortex, Temporal area TF (lateral part), Temporal area TF (medial part), Temporal area TH, accessory basal nucleus (amygdala), magnocellular subdivision, anterior amygdaloid area, central nucleus of the amygdala, cortical nucleus, anterior division, lateral nucleus (amygdala), ventrolateral subdivision

---
Region: Temporopolar area TG (TG)

Super-regions:
Temporopolar area TG < Area 36 < Nucleus peripeduncularis thalami < Ventral temporal cortex (anterior part of lateral occipito-temporal cortex = fusiform gyrus) < Temporal Lobe according to GM-Definition < GM-CerebralCortex < Brain

Sources:
Agranular insula, Anterior inferotemporal area (dorsal), Anterior inferotemporal area (ventral), Anterior medial nucleus, Area 10, Area 11, Area 12, Area 25, Basolateral nucleus of amygdala, Claustrum, Cortical area 46, Cortical area PGa, Cortical area TEm, Dysgranular insular cortex, Entorhinal cortex, Hypothalamus, Inferotemporal area TE, Intermediate field of entorhinal cortex, LGN external magnocellular layer, Lateral auditory field, Lateral field of entorhinal cortex, Medial basal nucleus of the amygdala, Medial basal nucleus of the amygdala, Midline nuclei of the thalamus, Nucleus basalis thalami, Nucleus centralis densocellularis thalami, Nucleus limitans thalami, Nucleus medialis dorsalis thalami, pars densocellularis, Nucleus parafascicularis thalami, Nucleus paraventricularis thalami, pars anterior, Nucleus pulvinaris medialis thalami, Nucleus reuniens thalami, Nucleus suprageniculatus thalami, Olfactory Complex, Orbital prefrontal cortex, Orbitofrontal area 13, Orbitofrontal area 14, Orbitofrontal cortex, agranular periallocortical, Parasubiculum, Periamygdaloid cortex 2, Piriform cortex, Primary auditory cortex, Primary sensory cortex, Superior temporal area 2, Superior temporal area 3, Temporal area TA, Temporal area TAa, Temporal area TF, Temporal area TH, Temporal parietooccipital associated area in superior temporal sulcus, Temporoparietal asscociated area (caudal part), Temporoparietal associated area (rostral part), anterior amygdaloid area, area 24, central nucleus of the amygdala, cortical nucleus (amygdala), medial entorhinal cortex, posterior lateral auditory area

Descendant sources:
Anterior inferotemporal area (dorsal), Anterior inferotemporal area (ventral), Area 10, Area 25, Area 32, Basolateral nucleus of amygdala, Cortical area 29a-c, Dysgranular Temporopolar Cortex, Entorhinal cortex, Hippocampus, Insula, Intermediate agranula insular cortex, Lateral auditory field, Lateral field of entorhinal cortex, Medial agranular insular cortex, Medial area 11, Medial basal nucleus of the amygdala,

Nucleus basalis thalami, Orbital area 12, Orbitofrontal area 13, Orbitofrontal area 13a, Orbitofrontal cortex, agranular periallocortical, Parahippocampal cortex, Piriform cortex, Presubiculum, Primary auditory cortex, Rostral area 14, Superior temporal area 1, Superior temporal area 2, Superior temporal area 3, Superior temporal sulcus, Temporal area TA, area 24, lateral nucleus (amygdala), ventrolateral subdivision, periamygdaloid cortex

Targets:
Anterior inferotemporal area (ventral), Area 10, Area 11, Area 12, Area 24a, Area 24b, Area 24c (rostral part of the cingulate sulcus), Area 25, Area 32, Area 7b, Area 8, Area 9, Basolateral nucleus of amygdala, Corpus geniculatum mediale, Inferotemporal area TE, LGN external magnocellular layer, Lateral auditory field, Medial basal nucleus of the amygdala, Nucleus basalis thalami, Nucleus caudatus, Nucleus caudatus; tail, Nucleus centralis superior lateralis thalami, Nucleus medialis dorsalis thalami, Nucleus medialis dorsalis thalami, pars magnocellularis, Nucleus medialis dorsalis thalami, pars parvocellularis, Nucleus parataenialis thalami, Nucleus pulvinaris medialis thalami, Nucleus reuniens thalami, Olfactory Complex, Orbitofrontal area 13, Orbitofrontal area 14, Periamygdaloid cortex 2, Posterior inferotemporal area, Putamen; caudal, Putamen; rostral, Temporal area TA, area 24, cortical nucleus (amygdala)

Descendant targets:
Agranular area of temporal polar cortex, Anterior inferotemporal area (ventral), Area 10, Area 11, Area 25, Area 32, Area 35, Basal amygdaloid nucleus, intermediate part, Caudal inferior parietal lobule, Caudal limiting field of entorhinal cortex, Caudal part of area 36, Central inferotemporal area (ventral), Entorhinal cortex, Entorhinal cortex, Granular area of temporal polar cortex, Inferotemporal area TE, Intermediate agranula insular cortex, Intermediate field of entorhinal cortex, Lateral area 11, Lateral area 12, Lateral auditory field, Lateral auditory parakoniocortex, Lateral field (caudal part) of entorhinal cortex, Lateral field (rostral part) of entorhinal cortex, Lateral nucleus (amygdala), dorsal division, Lateral nucleus (amygdala), dorsal intermediate division, Lateral nucleus (amygdala), ventral division, Medial area 11, Medial area 12, Medial area 9, Nucleus basalis thalami, Nucleus medialis dorsalis thalami, Olfactory Complex, Orbital area 10, Orbital area 12, Orbitofrontal area 13, Orbitofrontal area 13, medial part, Orbitofrontal area 13a, Orbitofrontal area 14, Posteromedial agranular insular cortex, Rostral area 14, Rostral field of entorhinal cortex, Rostral part of area 36, Secondary auditory cortex, Superior temporal area 1, Superior temporal area 2, Superior temporal area 3, Superior temporal sulcus, Temporal area TA, Temporal area TF, Temporal area TF (lateral part), Temporal area TF (medial part), Temporal area TH, accessory basal nucleus (amygdala), magnocellular subdivision, area 24, dorsal area 9, lateral nucleus (amygdala), ventrolateral subdivision

Sub-regions:
Cortical area 36p, Temporal proisocortex

Region: Temporal proisocortex (TPPro)

Super-regions:
Temporal proisocortex < Temporopolar area TG < Area 36 < Nucleus peripeduncularis thalami < Ventral temporal cortex (anterior part of lateral occipito-temporal cortex = fusiform gyrus) < Temporal Lobe according to GM-Definition < GM-CerebralCortex < Brain

Sources:
Area 32, Basolateral nucleus of amygdala, Cortical area 29a-c, Entorhinal cortex, Hippocampus, Lateral auditory field, Medial basal nucleus of the amygdala, Nucleus basalis thalami, Orbital area 12, Orbitofrontal area 13, Orbitofrontal cortex, agranular periallocortical, Piriform cortex, Presubiculum, Primary auditory cortex, Superior temporal area 1, Superior temporal area 2, Superior temporal area 3, Superior temporal sulcus, area 24, lateral nucleus (amygdala), ventrolateral subdivision, periamygdaloid cortex

Descendant sources:
Area 10, Area 25, Dysgranular Temporopolar Cortex, Entorhinal cortex, Insula, Intermediate agranula insular cortex, Lateral field of entorhinal cortex, Medial agranular insular cortex, Medial area 11, Orbitofrontal area 13a, Parahippocampal cortex, Piriform cortex, Rostral area 14, Temporal area TA

Targets:
Anterior inferotemporal area (ventral), Area 11, Area 32, Caudal inferior parietal lobule, Caudal part of area 36, Central inferotemporal area (ventral), Inferotemporal area TE, Lateral area 12, Lateral auditory field, Lateral auditory parakoniocortex, Lateral nucleus (amygdala), dorsal division, Lateral nucleus (amygdala), dorsal intermediate division, Lateral nucleus (amygdala), ventral division, Nucleus basalis thalami, Nucleus medialis dorsalis thalami, Orbital area 12, Rostral part of area 36, Secondary auditory cortex, Superior temporal area 1, Superior temporal area 2, Superior temporal area 3, Superior temporal sulcus, Temporal area TF, Temporal area TF (lateral part), Temporal area TF (medial part), Temporal area TH, area 24, lateral nucleus (amygdala), ventrolateral subdivision

Descendant targets:
Agranular area of temporal polar cortex, Area 10, Area 11, Area 25, Area 32, Granular area of temporal polar cortex, Intermediate agranula insular cortex, Lateral area 11, Lateral area 12, Medial area 11, Medial area 12, Medial area 9, Olfactory Complex, Orbital area 10, Orbital area 12, Orbitofrontal area 13, Orbitofrontal area 13, medial part, Orbitofrontal area 13a, Orbitofrontal area 14, Posteromedial agranular insular cortex, Rostral area 14, Temporal area TA, dorsal area 9

Sub-regions:
Agranular area of temporal polar cortex, Dysgranular Temporopolar Cortex, Granular area of temporal polar cortex

---
Region: Agranular area of temporal polar cortex (TPag)

Super-regions:
Agranular area of temporal polar cortex < Temporal proisocortex < Temporopolar area TG < Area 36 < Nucleus peripeduncularis thalami < Ventral temporal cortex (anterior part of lateral occipito-temporal cortex = fusiform gyrus) < Temporal Lobe according to GM-Definition < GM-CerebralCortex < Brain

Sources:
Dysgranular Temporopolar Cortex, Entorhinal cortex, Insula, Intermediate agranula insular cortex,

Lateral field of entorhinal cortex, Medial agranular insular cortex, Orbitofrontal area 13a, Parahippocampal cortex, Rostral area 14

Targets:
Intermediate agranula insular cortex, Orbital area 10, Orbital area 12, Orbitofrontal area 13, Orbitofrontal area 13, medial part, Orbitofrontal area 13a, Posteromedial agranular insular cortex, Rostral area 14

Region: Granular area of temporal polar cortex (TPg)

Super-regions:
Granular area of temporal polar cortex < Temporal proisocortex < Temporopolar area TG < Area 36 < Nucleus peripeduncularis thalami < Ventral temporal cortex (anterior part of lateral occipito-temporal cortex = fusiform gyrus) < Temporal Lobe according to GM-Definition < GM-CerebralCortex < Brain

Sources:
Area 10, Dysgranular Temporopolar Cortex, Entorhinal cortex, Intermediate agranula insular cortex, Medial agranular insular cortex, Medial area 11, Orbitofrontal area 13a, Parahippocampal cortex, Rostral area 14, Temporal area TA

Targets:
Area 11, Area 32, Intermediate agranula insular cortex, Lateral area 11, Lateral area 12, Medial area 11, Medial area 12, Orbital area 10, Orbital area 12, Orbitofrontal area 13, Orbitofrontal area 13, medial part, Orbitofrontal area 13a, Posteromedial agranular insular cortex, Rostral area 14

Region: Dysgranular Temporopolar Cortex (TPproD)

Super-regions:
Dysgranular Temporopolar Cortex < Temporal proisocortex < Temporopolar area TG < Area 36 < Nucleus peripeduncularis thalami < Ventral temporal cortex (anterior part of lateral occipito-temporal cortex = fusiform gyrus) < Temporal Lobe according to GM-Definition < GM-CerebralCortex < Brain

Sources:
Area 25, Entorhinal cortex, Lateral field of entorhinal cortex, Piriform cortex, Temporal area TA

Descendant sources:
Intermediate agranula insular cortex, Medial agranular insular cortex, Orbitofrontal area 13a, Rostral area 14

Targets:
Agranular area of temporal polar cortex, Area 10, Area 25, Area 32, Granular area of temporal polar cortex, Medial area 9, Olfactory Complex, Orbitofrontal area 14, Temporal area TA, dorsal area 9

Descendant targets:
Area 11, Area 32, Intermediate agranula insular cortex, Lateral area 12, Medial area 12, Orbital area 10, Orbital area 12, Orbitofrontal area 13,

Orbitofrontal area 13, medial part, Orbitofrontal area 13a, Posteromedial agranular insular cortex, Rostral area 14

Sub-regions:
Dorsal dysgranular area of temporal polar cortex, Ventral dysgranular area of temporal polar cortex

---
Region: Ventral dysgranular area of temporal polar cortex (TPdgv)

Super-regions:
Ventral dysgranular area of temporal polar cortex < Dysgranular Temporopolar Cortex < Temporal proisocortex < Temporopolar area TG < Area 36 < Nucleus peripeduncularis thalami < Ventral temporal cortex (anterior part of lateral occipito-temporal cortex = fusiform gyrus) < Temporal Lobe according to GM-Definition < GM-CerebralCortex < Brain

Sources:
Intermediate agranula insular cortex, Medial agranular insular cortex, Orbitofrontal area 13a

Targets:
Intermediate agranula insular cortex, Orbital area 10, Orbital area 12, Orbitofrontal area 13, Orbitofrontal area 13, medial part, Orbitofrontal area 13a, Posteromedial agranular insular cortex

---
Region: Dorsal dysgranular area of temporal polar cortex (TPdgd)

Super-regions:
Dorsal dysgranular area of temporal polar cortex < Dysgranular Temporopolar Cortex < Temporal proisocortex < Temporopolar area TG < Area 36 < Nucleus peripeduncularis thalami < Ventral temporal cortex (anterior part of lateral occipito-temporal cortex = fusiform gyrus) < Temporal Lobe according to GM-Definition < GM-CerebralCortex < Brain

Sources:
Intermediate agranula insular cortex, Rostral area 14

Targets:
Area 11, Area 32, Intermediate agranula insular cortex, Lateral area 12, Medial area 12, Orbital area 10, Orbital area 12, Rostral area 14

Region: Cortical area 36p (36p)

Super-regions:
Cortical area 36p < Temporopolar area TG < Area 36 < Nucleus peripeduncularis thalami < Ventral temporal cortex (anterior part of lateral occipito-temporal cortex = fusiform gyrus) < Temporal Lobe according to GM-Definition < GM-CerebralCortex < Brain

Sources:

Anterior inferotemporal area (dorsal),
Anterior inferotemporal area (ventral)

Targets:
Anterior inferotemporal area (ventral), Area 35, Basal amygdaloid nucleus, intermediate part, Caudal limiting field of entorhinal cortex, Caudal part of area 36, Entorhinal cortex, Entorhinal cortex, Intermediate field of entorhinal cortex, Lateral field (caudal part) of entorhinal cortex, Lateral field (rostral part) of entorhinal cortex, Rostral field of entorhinal cortex, accessory basal nucleus (amygdala), magnocellular subdivision

---

Region: Parahippocampal cortex (PHC)

Super-regions:
Parahippocampal cortex < Temporal Lobe according to GM-Definition < GM-CerebralCortex < Brain

Sources:
Principal Sulcus

Descendant sources:
Accessor basal nucleus (amygdala), ventromedial division, Accessory basal amygdaloid nucleus, dorsal division, Accessory basal amygdaloid nucleus, parvicellular part, Accessory basal amygdaloid nucleus, ventral division, Agranular insula, Anterior inferotemporal area (dorsal), Anterior inferotemporal area (ventral), Anterior nuclei of the thalamus, Area 10, Area 11, Area 12, Area 20, Area 23, Area 25, Area 29d, Area 32, Area 35, Area 36, Area 6, Area 7a, Area 8, Area 9, Basal amygdaloid nucleus, ventral lateral division, Basolateral nucleus of amygdala, CA1 subfield of Ammon`s horn, CA3 subfield of Ammons horn, Caudal limiting field of entorhinal cortex, Caudal part of area 36, Central inferotemporal area, Claustrum, Cortical area 29a-c, Cortical area 36p, Cortical area 46, Cortical area 9\/46d, Dysgranular insular cortex, Entorhinal cortex, Entorhinal cortex, Granular insular cortex, Hippocampus, Hypothalamus, Inferior parietal lobule (lateral posterior cortex below the intraparietal sulcus), Inferotemporal area TE, Insula, Intermediate agranula insular cortex, Intermediate field of entorhinal cortex, LGN external magnocellular layer, Lateral auditory field, Lateral field (caudal part) of entorhinal cortex, Lateral field (rostral part) of entorhinal cortex, Lateral field of entorhinal cortex, Lateral intraparietal area, Laterodorsal nucleus (thalamus), Medial agranular insular cortex, Medial area 11, Medial basal nucleus of the amygdala, Nucleus basalis thalami, Nucleus dorsalis tegmenti, Olfactory Complex, Orbitofrontal area 13, Orbitofrontal area 13a, Orbitofrontal area 14, Parietal area PG, medial part, Piriform cortex, Posterior inferotemporal area, Precentral opercular area, Presubiculum, Primary sensory cortex, Retrosplenial area 30, Rostral field of entorhinal cortex, Rostral part of area 36, Superior temporal area 3, Superior temporal sulcus, dorsal, Temporal area TF, Temporal area TF (lateral part), Temporal area TH, Temporal proisocortex, Temporoparietal asscociated area (caudal part), Temporoparietal associated area (rostral part), Visual area 4, accessory basal nucleus (amygdala), magnocellular subdivision, anterior amygdaloid area, area 24, cortical nucleus (amygdala), periamygdaloid cortex, prosubiculum, superior temporal gyrus, ventral striatal shell

Targets:
Agranular area of temporal polar cortex, Granular area of temporal polar cortex, Lateral nucleus (amygdala), dorsal division, Lateral nucleus (amygdala), dorsal intermediate division, Lateral nucleus (amygdala), ventral division, Principal Sulcus, lateral nucleus (amygdala), ventrolateral subdivision

Descendant targets:
Accessory basal amygdaloid nucleus, parvicellular part, Agranular area of temporal polar cortex, Agranular frontal area 5 (= rostral ventrolateral premotor area), Anterior inferotemporal area (dorsal), Anterior inferotemporal area (ventral), Area 10, Area 11, Area 12, Area 20, Area 23, Area 23a, Area 23b, Area 23c, Area 24a, Area 24b, Area 24c (rostral part of the cingulate sulcus), Area 25, Area 31, Area 32, Area 35, Area 36, Area 7a, Area 8, Area 8B, Area 9, Basal amygdaloid nucleus, intermediate part, CA1 subfield of Ammon`s horn, CA3 subfield of Ammons horn, Caudal limiting

field of entorhinal cortex, Caudal part of area 36, Central inferotemporal area, Cortical area 46, Cortical area 9\/46d, Dysgranular Temporopolar Cortex, Entorhinal cortex, Entorhinal cortex, Floor of superior temporal sulcus, Granular area of temporal polar cortex, Hippocampus, Inferotemporal area TE, Intermediate agranula insular cortex, Intermediate field of entorhinal cortex, Lateral auditory field, Lateral field (caudal part) of entorhinal cortex, Lateral field (rostral part) of entorhinal cortex, Lateral field of entorhinal cortex, Lateral intraparietal area, Lateral nucleus (amygdala), dorsal division, Lateral nucleus (amygdala), dorsal intermediate division, Lateral nucleus (amygdala), ventral division, Laterodorsal nucleus (thalamus), Medial area 11, Medial area 9, Medial basal nucleus of the amygdala, Medial superior temporal area (dorsal), Nucleus anterior ventralis thalami, Nucleus basalis thalami, Nucleus caudatus; tail, Nucleus dorsalis tegmenti, Nucleus medialis dorsalis thalami, Nucleus medialis dorsalis thalami, pars fibrosa, Nucleus medialis dorsalis thalami, pars magnocellularis, Nucleus medialis dorsalis thalami, pars paramediana, Nucleus pulvinaris medialis thalami, Olfactory Complex, Orbital area 10, Orbital area 12, Orbitofrontal area 13, Orbitofrontal area 13a, Orbitofrontal area 14, Parasubiculum, Parietal area PG, medial part, Posterior inferotemporal area, Posterior inferotemporal area (ventral), Posteromedial agranular insular cortex, Presubiculum, Rostral area 14, Rostral part of area 36, Temporal area TA, Temporal area TAa, Temporal area TF, Temporal area TF (lateral part), Temporal area TF (medial part), Temporal area TH, Temporal proisocortex, Temporoparietal asscociated area (caudal part), Temporoparietal associated area (rostral part), Temporoparietal cortex, Temporopolar area TG, Ventral posterior lateral nucleus (thalamus), Visual area 1, Visual area 4, accessory basal nucleus (amygdala), magnocellular subdivision, area 24, dorsal area 9, lateral nucleus (amygdala), ventrolateral subdivision, medial entorhinal cortex, ventral striatal shell

Sub-regions:
Entorhinal cortex, Parasubiculum, Presubiculum, Temporal area TH, prosubiculum, ventral striatal shell

---
Region: Entorhinal cortex (ENT)

Super-regions:
Entorhinal cortex < Parahippocampal cortex < Temporal Lobe according to GM-Definition < GM-CerebralCortex < Brain

Sources:
Accessory basal amygdaloid nucleus, parvicellular part, Agranular insula, Anterior inferotemporal area (dorsal), Anterior inferotemporal area (ventral), Area 10, Area 11, Area 12, Area 23, Area 25, Area 29d, Area 32, Area 35, Area 36, Area 6, Area 8, Area 9, Basolateral nucleus of amygdala, CA1 subfield of Ammon`s horn, CA3 subfield of Ammons horn, Caudal part of area 36, Central inferotemporal area, Claustrum, Cortical area 29a-c, Cortical area 36p, Cortical area 46, Dysgranular insular cortex, Hippocampus, LGN external magnocellular layer, Lateral auditory field, Laterodorsal nucleus (thalamus), Medial basal nucleus of the amygdala, Nucleus basalis thalami, Nucleus dorsalis tegmenti, Olfactory Complex, Orbitofrontal area 13, Orbitofrontal area 13a, Orbitofrontal area 14, Piriform cortex, Presubiculum, Retrosplenial area 30, Rostral part of area 36, Superior temporal area 3, Temporal area TF, Temporal area TH, anterior amygdaloid area, area 24, cortical nucleus (amygdala), periamygdaloid cortex, prosubiculum, superior temporal gyrus, ventral striatal shell

Descendant sources:
Agranular insula, Anterior inferotemporal area (ventral), Area 12, Area 23, Area 25, Area 29d, Area 35, Area 36, CA1 subfield of Ammon`s horn, CA3 subfield of Ammons horn, Caudal part of area 36, Central inferotemporal area, Claustrum, Cortical area 29a-c, Cortical area 36p, Cortical area 46, Hippocampus, Inferotemporal area TE, Insula, Intermediate agranula insular cortex, LGN external magnocellular layer, Lateral auditory field, Lateral field (caudal part) of entorhinal cortex, Lateral field of entorhinal cortex, Medial agranular insular cortex, Medial area 11, Medial basal nucleus of the amygdala, Nucleus basalis thalami, Olfactory Complex, Orbitofrontal area 13, Orbitofrontal area 13a, Orbitofrontal area 14, Piriform cortex, Presubiculum, Primary sensory cortex,

Retrosplenial area 30, Rostral part of area 36, Superior temporal area 3, Temporal area TF, Temporal area TH, anterior amygdaloid area, area 24, prosubiculum, superior temporal gyrus, ventral striatal shell

Targets:
Agranular area of temporal polar cortex, Anterior inferotemporal area (ventral), Area 10, Area 25, Area 32, Area 35, Basal amygdaloid nucleus, intermediate part, CA1 subfield of Ammon`s horn, CA3 subfield of Ammons horn, Caudal part of area 36, Central inferotemporal area, Dysgranular Temporopolar Cortex, Granular area of temporal polar cortex, Hippocampus, Inferotemporal area TE, Intermediate agranula insular cortex, Lateral nucleus (amygdala), dorsal division, Lateral nucleus (amygdala), dorsal intermediate division, Lateral nucleus (amygdala), ventral division, Medial area 11, Nucleus dorsalis tegmenti, Nucleus medialis dorsalis thalami, Nucleus medialis dorsalis thalami, pars fibrosa, Nucleus medialis dorsalis thalami, pars magnocellularis, Nucleus medialis dorsalis thalami, pars paramediana, Olfactory Complex, Orbitofrontal area 13a, Orbitofrontal area 14, Parasubiculum, Posteromedial agranular insular cortex, Presubiculum, Rostral part of area 36, Temporal area TA, Temporal area TF, Temporal area TH, Temporal proisocortex, Temporopolar area TG, accessory basal nucleus (amygdala), magnocellular subdivision, area 24, lateral nucleus (amygdala), ventrolateral subdivision, ventral striatal shell

Descendant targets:
Agranular area of temporal polar cortex, Anterior inferotemporal area (ventral), Area 35, CA1 subfield of Ammon`s horn, CA3 subfield of Ammons horn, Caudal part of area 36, Central inferotemporal area, Dysgranular Temporopolar Cortex, Hippocampus, Intermediate agranula insular cortex, Medial area 11, Nucleus dorsalis tegmenti, Olfactory Complex, Orbitofrontal area 13a, Parasubiculum, Posterior inferotemporal area, Posteromedial agranular insular cortex, Presubiculum, Rostral area 14, Rostral part of area 36, Temporal area TF, Temporal area TF (lateral part), Temporal area TF (medial part), Temporal area TH, Temporopolar area TG, medial entorhinal cortex, ventral striatal shell

Sub-regions:
Caudal limiting field of entorhinal cortex, Entorhinal cortex, Intermediate field of entorhinal cortex, Lateral field of entorhinal cortex, Olfactory field of entorhinal cortex, Rostral field of entorhinal cortex, medial entorhinal cortex

---
Region: Lateral field of entorhinal cortex (EL)

Super-regions:
Lateral field of entorhinal cortex < Entorhinal cortex < Parahippocampal cortex < Temporal Lobe according to GM-Definition < GM-CerebralCortex < Brain

Sources:
Anterior inferotemporal area (ventral), Area 36, Caudal part of area 36, Central inferotemporal area, Hippocampus, Insula, Lateral auditory field, Nucleus basalis thalami, Rostral part of area 36, Temporal area TF, ventral striatal shell

Descendant sources:
Area 35, Cortical area 36p, Hippocampus, Intermediate agranula insular cortex, Lateral auditory field, Medial agranular insular cortex, Medial area 11, Orbitofrontal area 13, Orbitofrontal area 13a, Temporal area TF, superior temporal gyrus, ventral striatal shell

Targets:
Agranular area of temporal polar cortex, Anterior inferotemporal area (ventral), Caudal part of area 36, Central inferotemporal area, Dysgranular Temporopolar Cortex, Nucleus dorsalis tegmenti, Olfactory Complex, Orbitofrontal area 13a, Posterior inferotemporal area, Rostral part of area 36, Temporal area TF, Temporal area TF (lateral part), Temporal area TF (medial part), Temporal area TH, Temporopolar area TG, medial entorhinal cortex

Descendant targets:
CA1 subfield of Ammon`s horn, CA3 subfield of Ammons horn, Hippocampus, Intermediate agranula insular cortex, Nucleus dorsalis tegmenti, Orbitofrontal area 13a, Parasubiculum, Posteromedial agranular insular cortex, Presubiculum, medial entorhinal cortex, ventral striatal shell

Sub-regions:
Lateral field (caudal part) of entorhinal cortex, Lateral field (rostral part) of entorhinal cortex

---
Region: Lateral field (rostral part) of entorhinal cortex (ELr)

Super-regions:
Lateral field (rostral part) of entorhinal cortex < Lateral field of entorhinal cortex < Entorhinal cortex < Parahippocampal cortex < Temporal Lobe according to GM-Definition < GM-CerebralCortex < Brain

Sources:
Area 35, Cortical area 36p, Intermediate agranula insular cortex, Lateral auditory field, Medial agranular insular cortex, Medial area 11, Orbitofrontal area 13, Orbitofrontal area 13a, Temporal area TF, superior temporal gyrus, ventral striatal shell

Targets:
CA1 subfield of Ammon`s horn, CA3 subfield of Ammons horn, Hippocampus, Intermediate agranula insular cortex, Nucleus dorsalis tegmenti, Orbitofrontal area 13a, Parasubiculum, Posteromedial agranular insular cortex, Presubiculum, ventral striatal shell

---
Region: Lateral field (caudal part) of entorhinal cortex (ELc)

Super-regions:
Lateral field (caudal part) of entorhinal cortex < Lateral field of entorhinal cortex < Entorhinal cortex < Parahippocampal cortex < Temporal Lobe according to GM-Definition < GM-CerebralCortex < Brain

Sources:
Cortical area 36p, Hippocampus, Lateral auditory field, Orbitofrontal area 13, Orbitofrontal area 13a, Temporal area TF, superior temporal gyrus, ventral striatal shell

Targets:
Orbitofrontal area 13a, medial entorhinal cortex

Region: Intermediate field of entorhinal cortex (EI)

Super-regions:
Intermediate field of entorhinal cortex < Entorhinal cortex < Parahippocampal cortex < Temporal Lobe according to GM-Definition < GM-CerebralCortex < Brain

Sources:
Area 35, Area 36, Caudal part of area 36, Cortical area 36p, Hippocampus, Intermediate agranula insular cortex, Lateral auditory field, Medial area 11, Nucleus basalis thalami, Orbitofrontal area 13a, Presubiculum, Primary sensory cortex, Rostral part of area 36, Temporal area TF, Temporal area TH, superior temporal gyrus

Targets:
Area 35, CA1 subfield of Ammon`s horn, CA3 subfield of Ammons horn, Caudal part of area 36, Hippocampus, Intermediate agranula insular cortex, Medial area 11, Nucleus dorsalis tegmenti, Orbitofrontal area 13a, Parasubiculum, Posterior inferotemporal area,

Posteromedial agranular insular cortex, Presubiculum, Rostral area 14, Rostral part of area 36, Temporal area TF, Temporal area TF (lateral part), Temporal area TF (medial part), Temporal area TH, Temporopolar area TG, ventral striatal shell

---

Region: Rostral field of entorhinal cortex (ER#1)

Super-regions:
Rostral field of entorhinal cortex < Entorhinal cortex < Parahippocampal cortex < Temporal Lobe according to GM-Definition < GM-CerebralCortex < Brain

Sources:
Area 35, Area 36, Caudal part of area 36, Cortical area 36p, Hippocampus, Intermediate agranula insular cortex, Medial agranular insular cortex, Medial area 11, Orbitofrontal area 13, Orbitofrontal area 13a, Rostral part of area 36, Temporal area TF, superior temporal gyrus

Targets:
Caudal part of area 36, Intermediate agranula insular cortex, Medial area 11, Nucleus dorsalis tegmenti, Orbitofrontal area 13a, Posterior inferotemporal area, Posteromedial agranular insular cortex, Rostral area 14, Rostral part of area 36, Temporal area TF, Temporal area TF (lateral part), Temporal area TF (medial part), Temporal area TH

Region: medial entorhinal cortex (28m)

Super-regions:
medial entorhinal cortex < Entorhinal cortex < Parahippocampal cortex < Temporal Lobe according to GM-Definition < GM-CerebralCortex < Brain

Sources:
Area 35, CA1 subfield of Ammon`s horn, CA3 subfield of Ammons horn, Claustrum, LGN external magnocellular layer, Lateral auditory field, Lateral field (caudal part) of entorhinal cortex, Lateral field of entorhinal cortex, Medial basal nucleus of the amygdala, Nucleus basalis thalami, Presubiculum, anterior amygdaloid area, prosubiculum, ventral striatal shell

Targets:
Temporopolar area TG

Region: Olfactory field of entorhinal cortex (EO)

Super-regions:
Olfactory field of entorhinal cortex < Entorhinal cortex < Parahippocampal cortex < Temporal Lobe according to GM-Definition < GM-CerebralCortex < Brain

Sources:
Area 35, Area 36, Hippocampus, Intermediate agranula insular cortex, Medial agranular insular cortex, Orbitofrontal area 13, Orbitofrontal area 13a, Rostral part of area 36, Temporal area TF

Targets:
Caudal part of area 36, Intermediate agranula insular cortex, Nucleus dorsalis tegmenti, Orbitofrontal area 13a, Posterior inferotemporal area, Posteromedial agranular insular cortex, Rostral part of area 36, Temporal area TF

Region: Caudal limiting field of entorhinal cortex (ECL)

Super-regions:
Caudal limiting field of entorhinal cortex <

Entorhinal cortex < Parahippocampal cortex < Temporal Lobe according to GM-Definition < GM-CerebralCortex < Brain

Sources:
Area 35, Area 36, Caudal part of area 36, Cortical area 36p, Hippocampus, Orbitofrontal area 13, Orbitofrontal area 13a, Temporal area TF, Temporal area TH, superior temporal gyrus

Targets:
Caudal part of area 36, Medial area 11, Nucleus dorsalis tegmenti, Orbitofrontal area 13a, Posterior inferotemporal area, Rostral area 14, Rostral part of area 36, Temporal area TF, Temporal area TF (lateral part), Temporal area TF (medial part), Temporal area TH

Region: Entorhinal cortex (EC#2)

Super-regions:
Entorhinal cortex < Entorhinal cortex < Parahippocampal cortex < Temporal Lobe according to GM-Definition < GM-CerebralCortex < Brain

Sources:
Agranular insula, Area 12, Area 23, Area 25, Area 29d, Area 35, Area 36, Caudal part of area 36, Claustrum, Cortical area 29a-c, Cortical area 36p, Cortical area 46, Hippocampus, Inferotemporal area TE, Medial agranular insular cortex, Olfactory Complex, Orbitofrontal area 13, Orbitofrontal area 13a, Orbitofrontal area 14, Piriform cortex, Retrosplenial area 30, Rostral part of area 36, Superior temporal area 3, Temporal area TF, Temporal area TH, area 24, superior temporal gyrus

Targets:
CA1 subfield of Ammon`s horn, CA3 subfield of Ammons horn, Caudal part of area 36, Hippocampus, Medial area 11, Nucleus dorsalis tegmenti, Orbitofrontal area 13a, Parasubiculum, Posterior inferotemporal area, Presubiculum, Rostral area 14, Rostral part of area 36, Temporal area TF, Temporal area TF (lateral part), Temporal area TF (medial part), Temporal area TH, ventral striatal shell

---
Region: ventral striatal shell (S#1)

Super-regions:
ventral striatal shell < Parahippocampal cortex < Temporal Lobe according to GM-Definition < GM-CerebralCortex < Brain

Sources:
Accessor basal nucleus (amygdala), ventromedial division, Accessory basal amygdaloid nucleus, dorsal division, Accessory basal amygdaloid nucleus, ventral division, Area 36, Basal amygdaloid nucleus, ventral lateral division, CA1 subfield of Ammon`s horn, Entorhinal cortex, Entorhinal cortex, Hippocampus, Intermediate field of entorhinal cortex, Lateral field (rostral part) of entorhinal cortex, Medial area 11, Nucleus basalis thalami, Orbitofrontal area 13a

Descendant sources:
Medial area 11, Orbitofrontal area 13a

Targets:
Area 11, Area 12, Area 25, Area 32, Entorhinal cortex, Lateral field (caudal part) of entorhinal cortex, Lateral field (rostral part) of entorhinal cortex, Lateral field of entorhinal cortex, Nucleus medialis dorsalis thalami, Orbital area 10, Orbitofrontal area 13, Orbitofrontal area 13a, Orbitofrontal area 14, Rostral area 14, Temporal area TF (medial part), Temporal area TH, area 24, medial entorhinal cortex

Descendant targets:
Medial area 11, Orbitofrontal area 13a, Rostral area 14

Sub-regions:

Subiculum, body portion, Subiculum, uncal portion

Region: Subiculum, uncal portion (Su#2)

Super-regions:
Subiculum, uncal portion < ventral striatal shell
< Parahippocampal cortex < Temporal Lobe
according to GM-Definition < GM-CerebralCortex <
Brain

Sources:
Medial area 11, Orbitofrontal area 13a

Targets:
Medial area 11, Orbitofrontal area 13a, Rostral area
14

Region: Subiculum, body portion (Sb)

Super-regions:
Subiculum, body portion < ventral striatal shell
< Parahippocampal cortex < Temporal Lobe
according to GM-Definition < GM-CerebralCortex <
Brain

Sources:
Medial area 11, Orbitofrontal area 13a

Targets:
Medial area 11, Orbitofrontal area 13a, Rostral area
14

Region: prosubiculum (Pros.)

Super-regions:
prosubiculum < Parahippocampal cortex < Temporal
Lobe according to GM-Definition < GM-CerebralCortex <
Brain

Sources:
Accessor basal nucleus (amygdala), ventromedial division,
Anterior inferotemporal area (ventral), Area 20, Central
inferotemporal area, Medial area 11, Medial basal nucleus
of the amygdala, Orbitofrontal area 13a, Temporal area TF,
Temporal area TF (lateral part), area 24

Targets:
Area 11, Area 25, Area 32, Area 35, Entorhinal cortex,
Medial area 11, Medial basal nucleus of the amygdala,
Orbitofrontal area 13, Orbitofrontal area 13a,
Orbitofrontal area 14, Temporal area TF, Temporal area TF
(lateral part), Temporal area TF (medial part), Temporal
area TH, area 24, medial entorhinal cortex

Region: Parasubiculum (PaS)

Super-regions:
Parasubiculum < Parahippocampal cortex < Temporal
Lobe according to GM-Definition < GM-CerebralCortex <
Brain

Sources:
Anterior inferotemporal area (dorsal), Anterior
inferotemporal area (ventral), Anterior nuclei of the
thalamus, Central inferotemporal area, Entorhinal cortex,
Entorhinal cortex, Hippocampus, Intermediate field of
entorhinal cortex, Lateral field (rostral part) of
entorhinal cortex, Posterior inferotemporal area

Targets:
Agranular frontal area 5 (= rostral ventrolateral premotor
area), Anterior inferotemporal area (dorsal), Anterior
inferotemporal area (ventral), Area 20, Area 24c (rostral
part of the cingulate sulcus), Area 25, Area 8, Central
inferotemporal area, Cortical area 46, Posterior
inferotemporal area, Temporal area TF, Temporopolar area

TG

Region: Temporal area TH (TH)

Super-regions:
Temporal area TH < Parahippocampal cortex < Temporal Lobe according to GM-Definition < GM-CerebralCortex < Brain

Sources:
Accessory basal amygdaloid nucleus, parvicellular part, Agranular insula, Anterior inferotemporal area (dorsal), Anterior inferotemporal area (ventral), Area 10, Area 11, Area 12, Area 23, Area 35, Area 7a, Area 9, CA1 subfield of Ammon`s horn, Caudal limiting field of entorhinal cortex, Caudal part of area 36, Central inferotemporal area, Cortical area 46, Dysgranular insular cortex, Entorhinal cortex, Entorhinal cortex, Granular insular cortex, Hippocampus, Hypothalamus, Inferotemporal area TE, Intermediate field of entorhinal cortex, Lateral auditory field, Lateral field of entorhinal cortex, Nucleus basalis thalami, Orbitofrontal area 13, Orbitofrontal area 13a, Piriform cortex, Posterior inferotemporal area, Precentral opercular area, Primary sensory cortex, Retrosplenial area 30, Rostral field of entorhinal cortex, Rostral part of area 36, Superior temporal sulcus, dorsal, Temporal area TF, Temporal proisocortex, Temporoparietal asscociated area (caudal part), Temporoparietal associated area (rostral part), Visual area 4, accessory basal nucleus (amygdala), magnocellular subdivision, anterior amygdaloid area, area 24, periamygdaloid cortex, prosubiculum, superior temporal gyrus, ventral striatal shell

Targets:
Accessory basal amygdaloid nucleus, parvicellular part, Anterior inferotemporal area (dorsal), Anterior inferotemporal area (ventral), Area 23, Area 23a, Area 23b, Area 23c, Area 24a, Area 24b, Area 24c (rostral part of the cingulate sulcus), Area 25, Area 31, Area 32, Area 36, Area 7a, Area 8B, Area 9, CA1 subfield of Ammon`s horn, Caudal limiting field of entorhinal cortex, Caudal part of area 36, Central inferotemporal area, Cortical area 46, Cortical area 9\/46d, Entorhinal cortex, Entorhinal cortex, Floor of superior temporal sulcus, Inferotemporal area TE, Intermediate field of entorhinal cortex, Lateral auditory field, Lateral nucleus (amygdala), dorsal division, Lateral nucleus (amygdala), dorsal intermediate division, Lateral nucleus (amygdala), ventral division, Laterodorsal nucleus (thalamus), Medial area 11, Medial area 9, Medial superior temporal area (dorsal), Nucleus anterior ventralis thalami, Nucleus basalis thalami, Nucleus caudatus; tail, Nucleus medialis dorsalis thalami, Nucleus pulvinaris medialis thalami, Orbital area 12, Orbitofrontal area 13a, Posterior inferotemporal area, Posterior inferotemporal area (ventral), Rostral area 14, Rostral part of area 36, Temporal area TAa, Temporal area TF, Temporal area TF (lateral part), Temporal area TF (medial part), Temporoparietal asscociated area (caudal part), Temporoparietal associated area (rostral part), Temporoparietal cortex, Temporopolar area TG, Ventral posterior lateral nucleus (thalamus), Visual area 1, Visual area 4, area 24, dorsal area 9, lateral nucleus (amygdala), ventrolateral subdivision

---

Region: Presubiculum (PrS)

Super-regions:
Presubiculum < Parahippocampal cortex < Temporal Lobe according to GM-Definition < GM-CerebralCortex < Brain

Sources:
Anterior inferotemporal area (dorsal), Anterior inferotemporal area (ventral), Anterior nuclei of the thalamus, Area 23, Area 9, Central inferotemporal area, Cortical area 9\/46d, Entorhinal cortex, Entorhinal cortex, Inferior parietal lobule (lateral posterior cortex below the intraparietal sulcus), Intermediate field of entorhinal cortex, Lateral field (rostral part) of entorhinal cortex, Lateral intraparietal area, Parietal

area PG, medial part, Posterior inferotemporal area,
Temporal area TF, area 24

Targets:
Anterior inferotemporal area (dorsal), Anterior inferotemporal area (ventral), Area 11, Area 12, Area 20, Area 25, Area 32, Area 8, Area 9, Central inferotemporal area, Cortical area 46, Entorhinal cortex, Inferotemporal area TE, Intermediate field of entorhinal cortex, Lateral intraparietal area, Orbitofrontal area 13, Orbitofrontal area 14, Parietal area PG, medial part, Posterior inferotemporal area, Temporal area TF, Temporal proisocortex, medial entorhinal cortex

---
Region: Hippocampus (Hip)

Super-regions:
Hippocampus < Temporal Lobe according to GM-Definition < GM-CerebralCortex < Brain

Sources:
Entorhinal cortex, Entorhinal cortex, Intermediate field of entorhinal cortex, Lateral field (rostral part) of entorhinal cortex, Medial basal nucleus of the amygdala, Nucleus basalis thalami

Descendant sources:
Accessor basal nucleus (amygdala), ventromedial division, Accessory basal amygdaloid nucleus, dorsal division, Accessory basal amygdaloid nucleus, ventral division, Anterior inferotemporal area (ventral), Area 20, Area 35, Area 36, Area 7a, Area 7b, Caudal limiting field of entorhinal cortex, Central inferotemporal area, Entorhinal cortex, Entorhinal cortex, Inferotemporal area TE, Intermediate field of entorhinal cortex, Lateral field (rostral part) of entorhinal cortex, Lateral field of entorhinal cortex, Medial basal nucleus of the amygdala, Nucleus basalis thalami, Olfactory field of entorhinal cortex, Rostral field of entorhinal cortex, Temporal area TF, Temporal area TF (lateral part), Temporal area TF (medial part), Temporal area TH, area 24

Targets:
Area 35, Caudal limiting field of entorhinal cortex, Caudal part of area 36, Entorhinal cortex, Entorhinal cortex, Intermediate field of entorhinal cortex, Lateral field (caudal part) of entorhinal cortex, Lateral field of entorhinal cortex, Nucleus medialis dorsalis thalami, Olfactory field of entorhinal cortex, Orbitofrontal area 13, Parasubiculum, Rostral field of entorhinal cortex, Rostral part of area 36, Temporal area TF, Temporal area TH, Temporal proisocortex, ventral striatal shell

Descendant targets:
Anterior inferotemporal area (ventral), Area 11, Area 20, Area 25, Area 32, Area 36, Caudal part of area 36, Central inferotemporal area, Entorhinal cortex, Medial area 11, Medial basal nucleus of the amygdala, Nucleus basalis thalami, Orbitofrontal area 13, Orbitofrontal area 13a, Orbitofrontal area 14, Periamygdaloid cortex 2, Rostral area 14, Temporal area TF, Temporal area TF (lateral part), Temporal area TF (medial part), Temporal area TH, area 24, cortical nucleus (amygdala), medial entorhinal cortex, ventral striatal shell

Sub-regions:
CA1 subfield of Ammon`s horn, CA3 subfield of Ammons horn, Nucleus dorsalis tegmenti

---
Region: CA1 subfield of Ammon`s horn (CA1)

Super-regions:
CA1 subfield of Ammon`s horn < Hippocampus < Temporal Lobe according to GM-Definition < GM-CerebralCortex < Brain

Sources:
Accessor basal nucleus (amygdala), ventromedial division, Accessory basal amygdaloid nucleus, dorsal division, Accessory basal amygdaloid nucleus, ventral division, Anterior inferotemporal area (ventral), Area 20, Area 35, Area 36, Area 7a, Area 7b, Central inferotemporal area, Entorhinal cortex, Entorhinal cortex, Inferotemporal area TE, Intermediate field of entorhinal cortex, Lateral field (rostral part) of entorhinal cortex, Medial basal nucleus

of the amygdala, Nucleus basalis thalami, Temporal area TF, Temporal area TF (lateral part), Temporal area TF (medial part), Temporal area TH, area 24

Targets:
Anterior inferotemporal area (ventral), Area 11, Area 20, Area 25, Area 32, Area 36, Caudal part of area 36, Central inferotemporal area, Entorhinal cortex, Medial basal nucleus of the amygdala, Nucleus basalis thalami, Orbitofrontal area 13, Orbitofrontal area 13a, Orbitofrontal area 14, Periamygdaloid cortex 2, Temporal area TF, Temporal area TF (lateral part), Temporal area TF (medial part), Temporal area TH, area 24, cortical nucleus (amygdala), medial entorhinal cortex, ventral striatal shell

---
Region: Nucleus dorsalis tegmenti (DG)

Super-regions:
Nucleus dorsalis tegmenti < Hippocampus < Temporal Lobe according to GM-Definition < GM-CerebralCortex < Brain

Sources:
Area 35, Caudal limiting field of entorhinal cortex, Entorhinal cortex, Entorhinal cortex, Intermediate field of entorhinal cortex, Lateral field (rostral part) of entorhinal cortex, Lateral field of entorhinal cortex, Olfactory field of entorhinal cortex, Rostral field of entorhinal cortex

Targets:
Entorhinal cortex

Region: CA3 subfield of Ammons horn (CA3)

Super-regions:
CA3 subfield of Ammons horn < Hippocampus < Temporal Lobe according to GM-Definition < GM-CerebralCortex < Brain

Sources:
Accessory basal amygdaloid nucleus, dorsal division, Entorhinal cortex, Entorhinal cortex, Intermediate field of entorhinal cortex, Lateral field (rostral part) of entorhinal cortex, Medial basal nucleus of the amygdala, Nucleus basalis thalami

Targets:
Entorhinal cortex, Medial area 11, Orbitofrontal area 13a, Rostral area 14, medial entorhinal cortex

---
Region: superior temporal gyrus (STG)

Super-regions:
superior temporal gyrus < Temporal Lobe according to GM-Definition < GM-CerebralCortex < Brain

Sources:
Area 7b, Nucleus pulvinaris thalami, Parietal area PG, medial part

Descendant sources:
Area 10, Area 11, Area 23, Area 25, Area 29, Area 31, Area 32, Area 35, Area 7, Area 8A, Area 8B, Area 9, Caudal auditory parakoniocortex, Corpus geniculatum mediale, Cortical area 45, Cortical area 46, Cortical area PGa, Dorsal area 46, Dysgranular Temporopolar Cortex, Entorhinal cortex, Hypothalamus, Inferior parietal lobule (lateral posterior cortex below the intraparietal sulcus), Inferotemporal area TE, Insula, Intraparietal sulcus associated area in the superior temporal sulcus, Lateral area 12, Lateral auditory field, Lateral auditory field, Lateral auditory parakoniocortex, Medial area 9, Nucleus limitans thalami, Nucleus paraventricularis thalami, Nucleus pulvinaris medialis thalami, Nucleus suprageniculatus thalami, Orbital area 12, Orbitofrontal area 13, Orbitofrontal area 14, Parietal area PG, medial part, Piriform cortex, Premotor area 6 (dorsal part), Primary auditory cortex, Primary sensory cortex, Principal

Sulcus, Retroinsular area, Retrosplenial area 30, Rostral superior parietal lobule, Secondary auditory cortex, Superior temporal area 1, Superior temporal area 2, Superior temporal area 3, Supratemporal cortex, granular, Temporal area TAa, Temporal area TF, Temporal area TH, Temporal parietooccipital associated area in superior temporal sulcus, Temporal proisocortex, Temporoparietal asscociated area (caudal part), Temporoparietal associated area (rostral part), Temporoparietal cortex, Temporopolar area TG, Ventral area 46, anterior lateral auditory belt, auditory prokoniocortex, caudal lateral auditory (belt), posterior lateral auditory area

Targets:
Area 35, Area 36, Area 6, Area 7b, Caudal limiting field of entorhinal cortex, Caudal part of area 36, Entorhinal cortex, Entorhinal cortex, Intermediate field of entorhinal cortex, Lateral field (caudal part) of entorhinal cortex, Lateral field (rostral part) of entorhinal cortex, Lateral nucleus (amygdala), dorsal division, Lateral nucleus (amygdala), dorsal intermediate division, Lateral nucleus (amygdala), ventral division, Nucleus caudatus, Nucleus caudatus; genu, Nucleus caudatus; tail, Parietal area PG, medial part, Primary motor area, Putamen; rostral, Rostral field of entorhinal cortex, Rostral part of area 36, Temporal area TF (lateral part), Temporal area TF (medial part), Temporal area TH, lateral nucleus (amygdala), ventrolateral subdivision

Descendant targets:
Agranular frontal area 2 (= caudal dorsolateral premotor area), Agranular frontal area 4 (= caudal ventrolateral premotor area), Agranular frontal area 5 (= rostral ventrolateral premotor area), Agranular frontal area 7 (= rostral dorsolateral premotor area), Anterior inferotemporal area (ventral), Area 10, Area 11, Area 12, Area 23, Area 23c, Area 25, Area 31, Area 32, Area 6, Area 6 (ventral part), Area 7, Area 7b, Area 8, Area 8A, Area 8B, Area 9, Caudal auditory parakoniocortex, Corpus geniculatum mediale, Cortical area 45, Cortical area 46, Cortical area 9\/46d, Dorsal area 46, Dorsal portion of area 8A, Dysgranular Temporopolar Cortex, Entorhinal cortex, Entorhinal cortex, Granular area of temporal polar cortex, Inferotemporal area TE, Intermediate agranula insular cortex, Lateral area 12, Lateral auditory field, Lateral auditory parakoniocortex, Medial area 11, Medial area 12, Medial area 9, Medial premotor area 6M, Nucleus caudatus, Nucleus caudatus; genu, Nucleus caudatus; tail, Nucleus limitans thalami, Nucleus medialis dorsalis thalami, Nucleus paraventricularis thalami, Nucleus pulvinaris lateralis thalami, dorsal division, Nucleus pulvinaris medialis thalami, Nucleus pulvinaris medialis thalami, lateral division, Nucleus pulvinaris medialis thalami, medial division, Nucleus suprageniculatus thalami, Occipitoparietal area, Orbital area 10, Orbital area 12, Orbitofrontal area 13, Orbitofrontal area 13, lateral part, Orbitofrontal area 13a, Orbitofrontal area 14, Parietal area PE (cingulate part), Piriform cortex, Premotor area 6 (dorsal part), Primary auditory cortex, Primary motor area, Principal Sulcus, Putamen; rostral, Retroinsular area, Rostral area 12, Rostral area 14, Secondary auditory cortex, Superior temporal area 1, Superior temporal area 2, Superior temporal area 3, Superior temporal sulcus, Supratemporal cortex, granular, Temporal area TAa, Temporal proisocortex, Temporoparietal asscociated area (caudal part), Temporoparietal cortex, Temporopolar area TG, Transitional sensory area, Ventral area 46, area 24, auditory prokoniocortex, dorsal area 9

Sub-regions:
Superior temporal polysensory area, Temporal area TA

Region: Superior temporal polysensory area (STP#2)

Super-regions:
Superior temporal polysensory area < superior temporal gyrus < Temporal Lobe according to GM-Definition < GM-CerebralCortex < Brain

Descendant sources:
Area 10, Area 11, Area 8A, Area 8B, Area 9, Caudal auditory parakoniocortex, Corpus geniculatum mediale, Cortical area 45, Cortical area 46, Cortical area PGa, Dorsal area 46, Insula, Lateral area 12, Lateral auditory field, Lateral auditory parakoniocortex, Nucleus limitans thalami, Nucleus paraventricularis thalami, Nucleus pulvinaris medialis thalami, Nucleus suprageniculatus thalami, Orbital area 12, Orbitofrontal area 13, Orbitofrontal area 14, Piriform cortex, Premotor area 6

(dorsal part), Primary auditory cortex, Principal Sulcus, Retroinsular area, Secondary auditory cortex, Superior temporal area 1, Superior temporal area 2, Superior temporal area 3, Supratemporal cortex, granular, Temporal area TAa, Temporal parietooccipital associated area in superior temporal sulcus, Temporal proisocortex, Temporoparietal asscociated area (caudal part), Temporoparietal associated area (rostral part), Temporoparietal cortex, Ventral area 46, anterior lateral auditory belt, auditory prokoniocortex, caudal lateral auditory (belt), posterior lateral auditory area

Descendant targets:
Agranular frontal area 2 (= caudal dorsolateral premotor area), Agranular frontal area 4 (= caudal ventrolateral premotor area), Agranular frontal area 5 (= rostral ventrolateral premotor area), Agranular frontal area 7 (= rostral dorsolateral premotor area), Area 10, Area 11, Area 12, Area 23, Area 23c, Area 25, Area 31, Area 32, Area 6, Area 6 (ventral part), Area 7, Area 7b, Area 8, Area 8A, Area 8B, Area 9, Caudal auditory parakoniocortex, Corpus geniculatum mediale, Cortical area 45, Cortical area 46, Dorsal area 46, Dorsal portion of area 8A, Inferotemporal area TE, Intermediate agranula insular cortex, Lateral area 12, Lateral auditory field, Lateral auditory parakoniocortex, Medial area 9, Medial premotor area 6M, Nucleus limitans thalami, Nucleus medialis dorsalis thalami, Nucleus paraventricularis thalami, Nucleus pulvinaris lateralis thalami, dorsal division, Nucleus pulvinaris medialis thalami, Nucleus pulvinaris medialis thalami, lateral division, Nucleus pulvinaris medialis thalami, medial division, Nucleus suprageniculatus thalami, Orbital area 12, Orbitofrontal area 14, Parietal area PE (cingulate part), Piriform cortex, Premotor area 6 (dorsal part), Primary auditory cortex, Primary motor area, Principal Sulcus, Retroinsular area, Secondary auditory cortex, Superior temporal area 1, Superior temporal area 2, Superior temporal area 3, Superior temporal sulcus, Supratemporal cortex, granular, Temporal area TAa, Temporal proisocortex, Temporoparietal asscociated area (caudal part), Temporoparietal cortex, Temporopolar area TG, Ventral area 46, area 24, auditory prokoniocortex, dorsal area 9

Sub-regions:
Primary auditory cortex, Secondary auditory cortex, Supratemporal cortex, granular

---
Region: Primary auditory cortex (A1)

Super-regions:
Primary auditory cortex < Superior temporal polysensory area < superior temporal gyrus < Temporal Lobe according to GM-Definition < GM-CerebralCortex < Brain

Sources:
Area 10, Area 8A, Caudal auditory parakoniocortex, Corpus geniculatum mediale, Cortical area PGa, Dorsal area 46, Insula, Lateral area 12, Lateral auditory field, Lateral auditory parakoniocortex, Nucleus limitans thalami, Nucleus paraventricularis thalami, Nucleus pulvinaris medialis thalami, Nucleus suprageniculatus thalami, Orbitofrontal area 13, Orbitofrontal area 14, Secondary auditory cortex, Superior temporal area 1, Superior temporal area 2, Temporal area TAa, Temporal parietooccipital associated area in superior temporal sulcus, anterior lateral auditory belt, auditory prokoniocortex, posterior lateral auditory area

Targets:
Area 25, Area 32, Area 8A, Caudal auditory parakoniocortex, Dorsal area 46, Inferotemporal area TE, Intermediate agranula insular cortex, Lateral area 12, Lateral auditory field, Lateral auditory parakoniocortex, Nucleus paraventricularis thalami, Orbital area 12, Orbitofrontal area 14, Secondary auditory cortex, Superior temporal area 1, Superior temporal area 2, Superior temporal area 3, Superior temporal sulcus, Supratemporal cortex, granular, Temporal area TAa, Temporal proisocortex, Temporoparietal cortex, Temporopolar area TG, auditory prokoniocortex, dorsal area 9

Region: Supratemporal cortex, granular (STPg)

Super-regions:
Supratemporal cortex, granular < Superior temporal polysensory area < superior temporal gyrus < Temporal Lobe according to GM-Definition < GM-CerebralCortex < Brain

Sources:
Insula, Lateral auditory parakoniocortex, Piriform cortex, Primary auditory cortex, Superior temporal area 2, Superior temporal area 3, Temporoparietal cortex, auditory prokoniocortex

Targets:
Area 10, Area 12, Area 25, Area 32, Area 8, Area 9, Caudal auditory parakoniocortex, Cortical area 46, Lateral auditory parakoniocortex, Piriform cortex, Superior temporal area 1, Superior temporal area 2, Superior temporal area 3, Temporoparietal cortex, area 24, auditory prokoniocortex

---
Region: Secondary auditory cortex (A2)

Super-regions:
Secondary auditory cortex < Superior temporal polysensory area < superior temporal gyrus < Temporal Lobe according to GM-Definition < GM-CerebralCortex < Brain

Sources:
Insula, Piriform cortex, Primary auditory cortex, Retroinsular area, Superior temporal area 1, Superior temporal area 2, Superior temporal area 3, Temporal proisocortex, Temporoparietal cortex

Descendant sources:
Area 10, Area 11, Area 8A, Area 8B, Area 9, Caudal auditory parakoniocortex, Corpus geniculatum mediale, Cortical area 45, Cortical area 46, Cortical area PGa, Dorsal area 46, Insula, Lateral area 12, Lateral auditory field, Lateral auditory parakoniocortex, Nucleus limitans thalami, Nucleus paraventricularis thalami, Nucleus pulvinaris medialis thalami, Nucleus suprageniculatus thalami, Orbital area 12, Piriform cortex, Premotor area 6 (dorsal part), Primary auditory cortex, Principal Sulcus, Retroinsular area, Superior temporal area 2, Superior temporal area 3, Supratemporal cortex, granular, Temporal area TAa, Temporal parietooccipital associated area in superior temporal sulcus, Temporal proisocortex, Temporoparietal asscociated area (caudal part), Temporoparietal associated area (rostral part), Temporoparietal cortex, Ventral area 46, anterior lateral auditory belt, auditory prokoniocortex, caudal lateral auditory (belt), posterior lateral auditory area

Targets:
Area 10, Area 12, Area 25, Area 32, Area 6, Area 8, Area 8B, Area 9, Corpus geniculatum mediale, Cortical area 46, Dorsal area 46, Nucleus limitans thalami, Nucleus medialis dorsalis thalami, Nucleus pulvinaris medialis thalami, Nucleus pulvinaris medialis thalami, lateral division, Nucleus pulvinaris medialis thalami, medial division, Piriform cortex, Primary auditory cortex, Retroinsular area, Superior temporal area 1, Superior temporal area 2, Superior temporal area 3, Temporoparietal cortex, area 24

Descendant targets:
Agranular frontal area 2 (= caudal dorsolateral premotor area), Agranular frontal area 4 (= caudal ventrolateral premotor area), Agranular frontal area 5 (= rostral ventrolateral premotor area), Agranular frontal area 7 (= rostral dorsolateral premotor area), Area 10, Area 11, Area 23, Area 23c, Area 31, Area 32, Area 6 (ventral part), Area 7, Area 7b, Area 8A, Area 8B, Area 9, Caudal auditory parakoniocortex, Corpus geniculatum mediale, Cortical area 45, Cortical area 46, Dorsal area 46, Dorsal

portion of area 8A, Inferotemporal area TE, Lateral area 12, Lateral auditory field, Lateral auditory parakoniocortex, Medial area 9, Medial premotor area 6M, Nucleus paraventricularis thalami, Nucleus pulvinaris lateralis thalami, dorsal division, Nucleus pulvinaris medialis thalami, Nucleus pulvinaris medialis thalami, lateral division, Nucleus pulvinaris medialis thalami, medial division, Nucleus suprageniculatus thalami, Orbital area 12, Parietal area PE (cingulate part), Premotor area 6 (dorsal part), Primary auditory cortex, Primary motor area, Principal Sulcus, Superior temporal area 2, Superior temporal area 3, Superior temporal sulcus, Supratemporal cortex, granular, Temporal area TAa, Temporoparietal asscociated area (caudal part), Temporoparietal cortex, Ventral area 46, auditory prokoniocortex

Sub-regions:
Lateral auditory parakoniocortex, Nucleus paraventricularis thalami

---
Region: Nucleus paraventricularis thalami (Pa#2)

Super-regions:
Nucleus paraventricularis thalami < Secondary auditory cortex < Superior temporal polysensory area < superior temporal gyrus < Temporal Lobe according to GM-Definition < GM-CerebralCortex < Brain

Sources:
Area 8A, Corpus geniculatum mediale, Insula, Lateral auditory parakoniocortex, Nucleus suprageniculatus thalami, Primary auditory cortex

Descendant sources:
Area 8A, Corpus geniculatum mediale, Dorsal area 46, Lateral area 12, Lateral auditory field, Lateral auditory parakoniocortex, Nucleus limitans thalami, Nucleus pulvinaris medialis thalami, Nucleus suprageniculatus thalami, Primary auditory cortex, Superior temporal area 3, Supratemporal cortex, granular, Temporal area TAa, Temporal parietooccipital associated area in superior temporal sulcus, Temporoparietal cortex, anterior lateral auditory belt, auditory prokoniocortex, caudal lateral auditory (belt), posterior lateral auditory area

Targets:
Area 8A, Lateral auditory field, Lateral auditory parakoniocortex, Primary auditory cortex, Superior temporal area 2

Descendant targets:
Area 23c, Area 31, Area 32, Area 8A, Caudal auditory parakoniocortex, Dorsal area 46, Dorsal portion of area 8A, Inferotemporal area TE, Lateral area 12, Lateral auditory field, Lateral auditory parakoniocortex, Medial area 9, Parietal area PE (cingulate part), Primary auditory cortex, Superior temporal area 3, Superior temporal sulcus, Supratemporal cortex, granular, Temporal area TAa, Temporoparietal cortex

Sub-regions:
Caudal auditory parakoniocortex, auditory prokoniocortex

Region: auditory prokoniocortex (ProK)

Super-regions:
auditory prokoniocortex < Nucleus paraventricularis thalami < Secondary auditory cortex < Superior temporal polysensory area < superior temporal gyrus < Temporal Lobe according to GM-Definition < GM-CerebralCortex < Brain

Sources:
Corpus geniculatum mediale, Lateral auditory field, Lateral auditory parakoniocortex, Primary auditory cortex, Superior temporal area 3, Supratemporal cortex, granular

Targets:
Area 32, Caudal auditory parakoniocortex, Inferotemporal area TE, Lateral area 12, Lateral auditory field, Lateral auditory parakoniocortex, Medial area 9, Primary auditory cortex, Superior temporal area 3, Superior temporal sulcus, Supratemporal cortex, granular, Temporal area TAa, Temporoparietal cortex

---
Region: Caudal auditory parakoniocortex (paAc)

Super-regions:
Caudal auditory parakoniocortex < Nucleus paraventricularis thalami < Secondary auditory cortex < Superior temporal polysensory area < superior temporal gyrus < Temporal Lobe according to GM-Definition < GM-CerebralCortex < Brain

Sources:
Area 8A, Corpus geniculatum mediale, Dorsal area 46, Lateral area 12, Lateral auditory field, Lateral auditory parakoniocortex, Nucleus limitans thalami, Nucleus pulvinaris medialis thalami, Nucleus supragenicularus thalami, Primary auditory cortex, Supratemporal cortex, granular, Temporal area TAa, Temporal parietooccipital associated area in superior temporal sulcus, Temporoparietal cortex, anterior lateral auditory belt, auditory prokoniocortex, caudal lateral auditory (belt), posterior lateral auditory area

Targets:
Area 23c, Area 31, Area 8A, Dorsal area 46, Dorsal portion of area 8A, Lateral auditory field, Lateral auditory parakoniocortex, Parietal area PE (cingulate part), Primary auditory cortex, Superior temporal area 3

Region: Lateral auditory parakoniocortex (paAlt)

Super-regions:
Lateral auditory parakoniocortex < Secondary auditory cortex < Superior temporal polysensory area < superior temporal gyrus < Temporal Lobe according to GM-Definition < GM-CerebralCortex < Brain

Sources:
Caudal auditory parakoniocortex, Cortical area PGa, Insula, Nucleus paraventricularis thalami, Piriform cortex, Primary auditory cortex, Principal Sulcus, Retroinsular area, Superior temporal area 2, Superior temporal area 3, Supratemporal cortex, granular, Temporal area TAa, Temporal parietooccipital associated area in superior temporal sulcus, Temporal proisocortex, Temporoparietal asscociated area (caudal part), Temporoparietal associated area (rostral part), Temporoparietal cortex, auditory prokoniocortex

Descendant sources:
Area 10, Area 11, Area 8A, Area 8B, Area 9, Caudal auditory parakoniocortex, Corpus geniculatum mediale, Cortical area 45, Cortical area 46, Dorsal area 46, Lateral area 12, Nucleus paraventricularis thalami, Nucleus supragenicularus thalami, Orbital area 12, Premotor area 6 (dorsal part), Primary auditory cortex, Ventral area 46, anterior lateral auditory belt, auditory prokoniocortex

Targets:
Area 23, Area 32, Caudal auditory parakoniocortex, Corpus geniculatum mediale, Dorsal portion of area 8A, Inferotemporal area TE, Lateral area 12, Nucleus paraventricularis thalami, Nucleus pulvinaris lateralis thalami, dorsal division, Nucleus pulvinaris medialis thalami, Nucleus pulvinaris medialis thalami, lateral division, Nucleus pulvinaris medialis thalami, medial division, Nucleus suprageniculatus thalami, Primary auditory cortex, Principal Sulcus, Superior temporal area 2, Superior temporal area 3, Superior temporal sulcus, Supratemporal cortex, granular, Temporal area TAa, Temporoparietal asscociated area (caudal part), auditory prokoniocortex

Descendant targets:
Agranular frontal area 2 (= caudal dorsolateral premotor area), Agranular frontal area 4 (= caudal ventrolateral premotor area), Agranular frontal area 5 (= rostral ventrolateral premotor area), Agranular frontal area 7 (= rostral dorsolateral premotor area), Area 10, Area 11, Area 6 (ventral part), Area 7, Area 7b, Area 8A, Area 8B, Area 9, Caudal auditory parakoniocortex, Cortical area 45, Cortical area 46, Dorsal area 46, Lateral area 12, Lateral auditory field, Medial premotor area 6M, Orbital area 12, Premotor area 6 (dorsal part), Primary auditory cortex, Primary motor area, Superior temporal area 3, Temporoparietal cortex, Ventral area 46, auditory prokoniocortex

Sub-regions:
Lateral auditory field, anterior lateral auditory belt, caudal lateral auditory (belt)

Region: Lateral auditory field (L#1)

Super-regions:
Lateral auditory field < Lateral auditory parakoniocortex < Secondary auditory cortex < Superior temporal polysensory area < superior temporal gyrus < Temporal Lobe according to GM-Definition < GM-CerebralCortex < Brain

Sources:
Area 10, Area 11, Area 8A, Area 8B, Area 9, Caudal auditory parakoniocortex, Corpus geniculatum mediale, Cortical area 45, Cortical area 46, Dorsal area 46, Lateral area 12, Nucleus paraventricularis thalami, Nucleus suprageniculatus thalami, Orbital area 12, Primary auditory cortex, Ventral area 46, anterior lateral auditory belt, auditory prokoniocortex

Targets:
Area 10, Area 11, Area 8A, Area 8B, Area 9, Caudal auditory parakoniocortex, Cortical area 45, Cortical area 46, Dorsal area 46, Lateral area 12, Orbital area 12, Primary auditory cortex, Superior temporal area 3, Ventral area 46, auditory prokoniocortex

---
Region: caudal lateral auditory (belt) (CL#4)

Super-regions:
caudal lateral auditory (belt) < Lateral auditory parakoniocortex < Secondary auditory cortex < Superior temporal polysensory area < superior temporal gyrus < Temporal Lobe according to GM-Definition < GM-CerebralCortex < Brain

Sources:
Area 8A, Cortical area 45, Cortical area

46, Dorsal area 46, Premotor area 6 (dorsal part), Ventral area 46

Targets:
Agranular frontal area 2 (= caudal dorsolateral premotor area), Agranular frontal area 4 (= caudal ventrolateral premotor area), Agranular frontal area 5 (= rostral ventrolateral premotor area), Agranular frontal area 7 (= rostral dorsolateral premotor area), Area 6 (ventral part), Area 7, Area 7b, Area 8A, Caudal auditory parakoniocortex, Cortical area 45, Cortical area 46, Dorsal area 46, Medial premotor area 6M, Premotor area 6 (dorsal part), Primary motor area, Temporoparietal cortex, Ventral area 46

Region: anterior lateral auditory belt (AL#4)

Super-regions:
anterior lateral auditory belt < Lateral auditory parakoniocortex < Secondary auditory cortex < Superior temporal polysensory area < superior temporal gyrus < Temporal Lobe according to GM-Definition < GM-CerebralCortex < Brain

Sources:
Area 10, Area 11, Area 8B, Cortical area 45, Cortical area 46, Dorsal area 46, Lateral area 12, Orbital area 12, Ventral area 46

Targets:
Area 10, Area 11, Area 8B, Caudal auditory parakoniocortex, Cortical area 45, Cortical area 46, Dorsal area 46, Lateral area 12, Lateral auditory field, Orbital area 12, Primary auditory cortex, Ventral area 46

Region: Temporal area TA (TA)

Super-regions:
Temporal area TA < superior temporal gyrus < Temporal Lobe according to GM-Definition < GM-CerebralCortex < Brain

Sources:
Area 23, Dysgranular Temporopolar Cortex, Entorhinal cortex, Hypothalamus, Lateral auditory field, Piriform cortex, Primary sensory cortex, Temporopolar area TG, posterior lateral auditory area

Descendant sources:
Area 10, Area 25, Area 29, Area 31, Area 32, Area 35, Area 7, Area 8A, Caudal auditory parakoniocortex, Corpus geniculatum mediale, Cortical area PGa, Dorsal area 46, Inferior parietal lobule (lateral posterior cortex below the intraparietal sulcus), Inferotemporal area TE, Insula, Intraparietal sulcus associated area in the superior temporal sulcus, Lateral area 12, Lateral auditory field, Lateral auditory parakoniocortex, Medial area 9, Nucleus limitans thalami, Nucleus paraventricularis thalami, Nucleus pulvinaris medialis thalami, Nucleus suprageniculatus thalami, Orbitofrontal area 13, Orbitofrontal area 14, Parietal area PG, medial part, Piriform cortex, Primary auditory cortex, Principal Sulcus, Retroinsular area, Retrosplenial area 30, Rostral superior parietal lobule, Secondary auditory cortex, Superior temporal area 1, Superior temporal area 2, Superior temporal area 3, Supratemporal cortex, granular, Temporal area TAa, Temporal area TF, Temporal area TH, Temporal parietooccipital associated area in superior temporal sulcus, Temporal proisocortex, Temporoparietal asscociated area (caudal part), Temporoparietal associated area (rostral part), Temporoparietal cortex, auditory prokoniocortex, caudal lateral auditory (belt), posterior lateral auditory area

Targets:

Area 32, Dysgranular Temporopolar Cortex, Granular area of temporal polar cortex, Intermediate agranula insular cortex, Lateral area 12, Medial area 11, Medial area 12, Nucleus caudatus, Nucleus caudatus; genu, Nucleus caudatus; tail, Orbital area 10, Orbital area 12, Orbitofrontal area 13, Orbitofrontal area 13, lateral part, Orbitofrontal area 13a, Putamen; rostral, Rostral area 12, Rostral area 14, Temporopolar area TG

Descendant targets:
Anterior inferotemporal area (ventral), Area 10, Area 11, Area 12, Area 23, Area 23c, Area 25, Area 31, Area 32, Area 6, Area 8A, Area 8B, Area 9, Caudal auditory parakoniocortex, Corpus geniculatum mediale, Cortical area 46, Cortical area 9\/46d, Dorsal area 46, Dorsal portion of area 8A, Entorhinal cortex, Entorhinal cortex, Inferotemporal area TE, Lateral area 12, Lateral auditory parakoniocortex, Medial area 9, Medial premotor area 6M, Nucleus limitans thalami, Nucleus pulvinaris medialis thalami, Nucleus pulvinaris medialis thalami, lateral division, Nucleus suprageniculatus thalami, Occipitoparietal area, Orbitofrontal area 14, Parietal area PE (cingulate part), Primary auditory cortex, Principal Sulcus, Secondary auditory cortex, Superior temporal area 1, Superior temporal area 2, Superior temporal area 3, Superior temporal sulcus, Supratemporal cortex, granular, Temporal area TAa, Temporal proisocortex, Temporoparietal asscociated area (caudal part), Temporopolar area TG, Transitional sensory area, Ventral area 46, area 24, auditory prokoniocortex, dorsal area 9

Sub-regions:
Area temporalis superior, Temporoparietal cortex

Region: Area temporalis superior (Ts)

Super-regions:
Area temporalis superior < Temporal area TA < superior temporal gyrus < Temporal Lobe according to GM-Definition < GM-CerebralCortex < Brain

Descendant sources:
Area 10, Area 25, Area 32, Area 8A, Caudal auditory parakoniocortex, Corpus geniculatum mediale, Cortical area PGa, Dorsal area 46, Inferotemporal area TE, Insula, Intraparietal sulcus associated area in the superior temporal sulcus, Lateral area 12, Lateral auditory field, Lateral auditory parakoniocortex, Medial area 9, Nucleus limitans thalami, Nucleus paraventricularis thalami, Nucleus pulvinaris medialis thalami, Nucleus suprageniculatus thalami, Orbitofrontal area 13, Orbitofrontal area 14, Piriform cortex, Primary auditory cortex, Principal Sulcus, Retroinsular area, Secondary auditory cortex, Superior temporal area 1, Superior temporal area 2, Superior temporal area 3, Supratemporal cortex, granular, Temporal area TAa, Temporal parietooccipital associated area in superior temporal sulcus, Temporal proisocortex, Temporoparietal asscociated area (caudal part), Temporoparietal associated area (rostral part), Temporoparietal cortex, auditory prokoniocortex

Descendant targets:
Anterior inferotemporal area (ventral), Area 10, Area 11, Area 12, Area 23, Area 25, Area 32, Area 8B, Area 9, Corpus geniculatum mediale, Cortical area 46, Cortical area 9\/46d, Dorsal area 46, Dorsal portion of area 8A, Entorhinal cortex, Entorhinal cortex, Inferotemporal area TE, Lateral area 12, Lateral auditory parakoniocortex, Medial area 9, Nucleus limitans thalami, Nucleus pulvinaris medialis thalami, Nucleus pulvinaris medialis thalami, lateral division, Nucleus suprageniculatus thalami, Orbitofrontal area 14, Primary auditory cortex, Principal Sulcus, Secondary auditory cortex, Superior temporal area 1, Superior temporal area 2, Superior temporal area 3, Superior temporal sulcus, Supratemporal cortex, granular, Temporal area TAa, Temporal proisocortex, Temporoparietal asscociated area (caudal part), Temporopolar area TG, area 24, auditory prokoniocortex, dorsal area 9

Sub-regions:

Superior temporal area 1, Superior temporal area 2,
Superior temporal area 3

Region: Superior temporal area 3 (ST3)

Super-regions:
Superior temporal area 3 < Area temporalis superior < Temporal area TA < superior temporal gyrus < Temporal Lobe according to GM-Definition < GM-CerebralCortex < Brain

Sources:
Area 32, Caudal auditory parakoniocortex, Corpus geniculatum mediale, Cortical area PGa, Insula, Lateral auditory field, Lateral auditory parakoniocortex, Nucleus suprageniculatus thalami, Piriform cortex, Primary auditory cortex, Principal Sulcus, Retroinsular area, Secondary auditory cortex, Superior temporal area 1, Superior temporal area 2, Supratemporal cortex, granular, Temporal area TAa, Temporal parietooccipital associated area in superior temporal sulcus, Temporal proisocortex, Temporoparietal asscociated area (caudal part), Temporoparietal associated area (rostral part), Temporoparietal cortex, auditory prokoniocortex

Targets:
Area 10, Area 12, Area 23, Area 25, Area 32, Area 8B, Area 9, Corpus geniculatum mediale, Cortical area 46, Dorsal area 46, Dorsal portion of area 8A, Entorhinal cortex, Entorhinal cortex, Inferotemporal area TE, Lateral area 12, Lateral auditory parakoniocortex, Medial area 9, Nucleus limitans thalami, Nucleus pulvinaris medialis thalami, Nucleus pulvinaris medialis thalami, lateral division, Nucleus suprageniculatus thalami, Orbitofrontal area 14, Principal Sulcus, Secondary auditory cortex, Superior temporal area 2, Superior temporal sulcus, Supratemporal cortex, granular, Temporal area TAa, Temporal proisocortex, Temporoparietal asscociated area (caudal part), Temporopolar area TG, area 24, auditory prokoniocortex, dorsal area 9

Region: Superior temporal area 2 (ST2)

Super-regions:
Superior temporal area 2 < Area temporalis superior < Temporal area TA < superior temporal gyrus < Temporal Lobe according to GM-Definition < GM-CerebralCortex < Brain

Sources:
Area 10, Area 25, Area 32, Area 8A, Corpus geniculatum mediale, Cortical area PGa, Dorsal area 46, Inferotemporal area TE, Intraparietal sulcus associated area in the superior temporal sulcus, Lateral area 12, Lateral auditory parakoniocortex, Medial area 9, Nucleus limitans thalami, Nucleus paraventricularis thalami, Nucleus pulvinaris medialis thalami, Orbitofrontal area 13, Orbitofrontal area 14, Piriform cortex, Primary auditory cortex, Secondary auditory cortex, Superior temporal area 1, Superior temporal area 3, Supratemporal cortex, granular, Temporal area TAa, Temporal parietooccipital associated area in superior temporal sulcus, Temporal proisocortex, Temporoparietal asscociated area (caudal part), Temporoparietal associated area (rostral part)

Targets:
Area 10, Area 25, Area 32, Area 9, Cortical area 46, Cortical area 9\/46d, Inferotemporal area TE, Lateral area 12, Lateral auditory parakoniocortex, Medial area 9, Orbitofrontal area 14, Primary auditory cortex, Secondary auditory cortex, Superior temporal area 1, Superior temporal area 3, Superior temporal sulcus, Supratemporal cortex, granular, Temporal

area TAa, Temporal proisocortex, Temporoparietal asscociated area (caudal part), Temporopolar area TG, dorsal area 9

Region: Superior temporal area 1 (ST1)

Super-regions:
Superior temporal area 1 < Area temporalis superior < Temporal area TA < superior temporal gyrus < Temporal Lobe according to GM-Definition < GM-CerebralCortex < Brain

Sources:
Area 10, Area 25, Area 32, Corpus geniculatum mediale, Cortical area PGa, Lateral area 12, Nucleus limitans thalami, Nucleus pulvinaris medialis thalami, Orbitofrontal area 13, Orbitofrontal area 14, Primary auditory cortex, Secondary auditory cortex, Superior temporal area 2, Supratemporal cortex, granular, Temporal area TAa, Temporal parietooccipital associated area in superior temporal sulcus, Temporal proisocortex, Temporoparietal asscociated area (caudal part), Temporoparietal associated area (rostral part)

Targets:
Anterior inferotemporal area (ventral), Area 10, Area 11, Area 25, Area 32, Area 9, Cortical area 46, Inferotemporal area TE, Lateral area 12, Medial area 9, Orbitofrontal area 14, Primary auditory cortex, Secondary auditory cortex, Superior temporal area 2, Superior temporal area 3, Superior temporal sulcus, Temporal area TAa, Temporal proisocortex, Temporoparietal asscociated area (caudal part), dorsal area 9

Region: Temporoparietal cortex (Tpt)

Super-regions:
Temporoparietal cortex < Temporal area TA < superior temporal gyrus < Temporal Lobe according to GM-Definition < GM-CerebralCortex < Brain

Sources:
Area 29, Area 31, Area 35, Area 7, Cortical area PGa, Inferior parietal lobule (lateral posterior cortex below the intraparietal sulcus), Insula, Nucleus limitans thalami, Nucleus pulvinaris medialis thalami, Nucleus suprageniculatus thalami, Parietal area PG, medial part, Primary auditory cortex, Principal Sulcus, Retrosplenial area 30, Rostral superior parietal lobule, Secondary auditory cortex, Supratemporal cortex, granular, Temporal area TAa, Temporal area TF, Temporal area TH, Temporal parietooccipital associated area in superior temporal sulcus, Temporoparietal asscociated area (caudal part), Temporoparietal associated area (rostral part), auditory prokoniocortex, caudal lateral auditory (belt), posterior lateral auditory area

Targets:
Area 23, Area 23c, Area 31, Area 6, Area 8A, Area 8B, Caudal auditory parakoniocortex, Cortical area 46, Dorsal area 46, Dorsal portion of area 8A, Inferotemporal area TE, Lateral auditory parakoniocortex, Medial premotor area 6M, Occipitoparietal area, Parietal area PE (cingulate part), Principal Sulcus, Secondary auditory cortex, Superior temporal area 3, Superior temporal sulcus, Supratemporal cortex, granular, Temporal area TAa, Temporoparietal asscociated area (caudal part), Transitional sensory area, Ventral area 46

Region: Inferotemporal area TE (TE)

Super-regions:
Inferotemporal area TE < Temporal Lobe according to GM-Definition < GM-CerebralCortex < Brain

Sources:
Area 12, Area 35, Area 36, Area 8, Basolateral nucleus of amygdala, Cortical amygdaloid nucleus, Cortical area 45A, Cortical area 45B, Cortical area 46, Cortical area OAa, Cortical area PGa, Entorhinal cortex, Extrastriate area OA, Floor of superior temporal sulcus, Hypothalamus, Insula, Intraparietal sulcus associated area in the superior temporal sulcus, Lateral auditory field, Lateral auditory parakoniocortex, Lateral intraparietal area, Medial agranular insular cortex, Medial basal nucleus of the amygdala, Middle temporal area, Nucleus basalis thalami, Nucleus limitans thalami, Nucleus paracentralis thalami, Nucleus parafascicularis thalami, Nucleus pulvinaris inferior thalami, Nucleus pulvinaris medialis thalami, Nucleus pulvinaris thalami, Nucleus reuniens thalami, Nucleus ventralis anterior thalami, pars magnocellularis, Orbitofrontal area 13a, Piriform cortex, Presubiculum, Primary auditory cortex, Primary sensory cortex, Superior temporal area 1, Superior temporal area 2, Superior temporal area 3, Temporal area TAa, Temporal area TF, Temporal area TH, Temporal parietooccipital associated area in superior temporal sulcus, Temporal proisocortex, Temporoparietal asscociated area (caudal part), Temporoparietal associated area (rostral part), Temporoparietal cortex, Temporopolar area TG, Visual area 2, area 24, auditory prokoniocortex, cortical nucleus (amygdala), posterior lateral auditory area

Descendant sources:
Anterior inferotemporal area (dorsal), Anterior inferotemporal area (ventral), Area 12, Area 35, Area 36, Area 7a, Area 7b, Area 8, Basolateral nucleus of amygdala, CA1 subfield of Ammon`s horn, Caudal area 8A, Caudal limiting field of entorhinal cortex, Caudal part of area 36, Central inferotemporal area, Central inferotemporal area (dorsal), Central inferotemporal area (ventral), Claustrum, Cortical amygdaloid nucleus, Cortical area 36p, Cortical area 45, Cortical area 45A, Cortical area 45B, Cortical area 46, Cortical area OAa, Cortical area PGa, Cortical area TEm, Dorsal prelunate gyrus, Dorsal visual area 3, Entorhinal cortex, Entorhinal cortex, Floor of superior temporal sulcus, Frontal eye field, Intermediate field of entorhinal cortex, Intraparietal sulcus associated area in the superior temporal sulcus, Lateral Geniculate Nucleus, Lateral auditory field, Lateral field of entorhinal cortex, Lateral intraparietal area, Lateral intraparietal area (external part), Lateral intraparietal area (internal part), Medial basal nucleus of the amygdala, Medial superior temporal area, Medial superior temporal area (dorsal), Middle temporal area, Nucleus basalis thalami, Nucleus limitans thalami, Nucleus paracentralis thalami, Nucleus parafascicularis thalami, Nucleus peripeduncularis thalami, Nucleus pulvinaris inferior thalami, Nucleus pulvinaris medialis thalami, Nucleus pulvinaris thalami, Nucleus ventralis anterior thalami, pars magnocellularis, Olfactory field of entorhinal cortex, Orbitofrontal area 13, Parasubiculum, Periamygdaloid cortex 2, Posterior inferotemporal area, Posterior inferotemporal area (dorsal), Posterior inferotemporal area (ventral), Posterior parietal area, Presubiculum, Putamen; rostral, Rostral field of entorhinal cortex, Rostral part of area 36, Superior temporal area 1, Superior temporal sulcus, Temporal area TAa, Temporal area TF, Temporal area TH, Temporal parietooccipital associated area in superior temporal sulcus, Temporal proisocortex, Temporoparietal asscociated area (caudal part), Temporoparietal associated area (rostral part), Temporopolar area TG, V4 transitional area, Ventral intraparietal area, Ventral occipitotemporal area, Ventral visual area 3, Visual area 2, Visual area 3A, Visual area 4, Visual area 4 (dorsal part), Visual area 4 (ventral part), posterior lateral auditory area, temporal visual association area in the lower bank of the superior temporal sulcus

Targets:
Area 10, Area 11, Area 12, Area 25, Area 32, Area 36, Area 9, Basal amygdaloid nucleus, intermediate part, Basolateral nucleus of amygdala, CA1 subfield of Ammon`s horn, Caudal part of area 36, Cortical area 45A, Cortical area 45B, Cortical area 46, Cortical area OAa, Dorsal prelunate gyrus, Entorhinal cortex, Extrastriate area OA, Intermediate agranula insular cortex, Intraparietal sulcus associated area in the superior temporal sulcus, Lateral area 12, Lateral auditory field, Lateral intraparietal area, Lateral nucleus (amygdala), dorsal division, Lateral nucleus (amygdala), dorsal intermediate division, Lateral nucleus (amygdala), ventral division, Medial area 12, Medial basal nucleus of the amygdala, Nucleus caudatus, Nucleus caudatus; genu, Nucleus caudatus; tail, Nucleus medialis dorsalis thalami, Nucleus pulvinaris inferior thalami, Nucleus pulvinaris medialis thalami, Nucleus reticularis thalami, Orbital area 12, Orbitofrontal area 13,

Orbitofrontal area 13, lateral part, Orbitofrontal area 13a, Orbitofrontal area 14, Posteromedial agranular insular cortex, Putamen, Putamen; caudal, Putamen; rostral, Rostral area 12, Rostral part of area 36, Superior temporal area 2, Temporal area TAa, Temporal area TF (lateral part), Temporal area TF (medial part), Temporal area TH, Temporal parietooccipital associated area in superior temporal sulcus, Temporopolar area TG, Visual area 1, Visual area 2, Visual area 3, Visual area 4, accessory basal nucleus (amygdala), magnocellular subdivision, area 24, lateral nucleus (amygdala), ventrolateral subdivision, posterior lateral auditory area

Descendant targets:
Anterior inferotemporal area (dorsal), Anterior inferotemporal area (ventral), Area 10, Area 11, Area 12, Area 23b, Area 35, Area 36, Area 6, Area 7a, Area 7b, Area 8A, Basolateral nucleus of amygdala, CA1 subfield of Ammon`s horn, Caudal inferior parietal lobule, Caudal part of area 36, Central inferotemporal area, Central inferotemporal area (dorsal), Central inferotemporal area (ventral), Claustrum, Cortical area 36p, Cortical area 45, Cortical area 45A, Cortical area 46, Cortical area PGa, Cortical area TEm, Dorsal prelunate gyrus, Dorsal visual area 3, Entorhinal cortex, Floor of superior temporal sulcus, Frontal eye field, Inferior parietal lobule (lateral posterior cortex below the intraparietal sulcus), Intraparietal sulcus associated area in the superior temporal sulcus, Lateral area 12, Lateral auditory field, Lateral field of entorhinal cortex, Lateral intraparietal area, Lateral intraparietal area (external part), Lateral intraparietal area (internal part), Lateral nucleus (amygdala), dorsal division, Lateral nucleus (amygdala), dorsal intermediate division, Lateral nucleus (amygdala), ventral division, Medial basal nucleus of the amygdala, Medial basal nucleus of the amygdala, Medial superior temporal area (dorsal), Middle temporal area, Nucleus basalis thalami, Nucleus caudatus, Nucleus caudatus; genu, Nucleus peripeduncularis thalami, Nucleus pulvinaris inferior thalami, Nucleus pulvinaris medialis thalami, Nucleus reticularis thalami, Orbital area 12, Orbitofrontal area 13, Parasubiculum, Posterior inferotemporal area, Posterior inferotemporal area (dorsal), Posterior inferotemporal area (ventral), Posterior parietal area, Prefrontal area 47\/12, Presubiculum, Putamen, Putamen; caudal, Rostral part of area 36, Superior temporal sulcus, Temporal area TAa, Temporal area TF, Temporal area TF (lateral part), Temporal area TF (medial part), Temporal area TH, Temporal parietooccipital associated area in superior temporal sulcus, Temporopolar area TG, V4 transitional area, Ventral area 46, Ventral intraparietal area, Ventral visual area 3, Visual area 1, Visual area 2, Visual area 3A, Visual area 4, area 24, central nucleus of the amygdala, posterior lateral auditory area, prosubiculum, temporal visual association area in the lower bank of the superior temporal sulcus

Sub-regions:
Area 20, Area 21

Region: Area 20 (20)

Super-regions:
Area 20 < Inferotemporal area TE < Temporal Lobe according to GM-Definition < GM-CerebralCortex < Brain

Sources:
Basolateral nucleus of amygdala, CA1 subfield of Ammon`s horn, Lateral auditory field, Lateral intraparietal area, Medial basal nucleus of the amygdala, Nucleus pulvinaris medialis thalami, Nucleus pulvinaris thalami, Parasubiculum, Periamygdaloid cortex 2, Presubiculum

Descendant sources:
Anterior inferotemporal area (dorsal), Anterior inferotemporal area (ventral), Area 12, Area 35, Area 36, Basolateral nucleus of amygdala, CA1 subfield of Ammon`s horn, Caudal part of area 36, Central inferotemporal area, Central inferotemporal area (dorsal), Central inferotemporal area (ventral), Cortical area 36p, Cortical area 45, Cortical area 46, Cortical area OAa, Cortical area TEm, Entorhinal cortex, Floor of superior temporal sulcus, Frontal eye field, Intraparietal sulcus associated area in the superior temporal sulcus, Lateral auditory field, Lateral field of entorhinal cortex, Lateral intraparietal area (external part), Lateral intraparietal area (internal part), Medial basal nucleus of the amygdala, Middle temporal area, Nucleus peripeduncularis thalami,

Orbitofrontal area 13, Parasubiculum, Periamygdaloid cortex 2, Posterior inferotemporal area, Posterior inferotemporal area (dorsal), Posterior inferotemporal area (ventral), Presubiculum, Rostral part of area 36, Superior temporal area 1, Superior temporal sulcus, Temporal area TF, Temporal area TH, Temporal proisocortex, Temporoparietal asscociated area (caudal part), Temporopolar area TG, Visual area 4, temporal visual association area in the lower bank of the superior temporal sulcus

Targets:
Area 23b, Basolateral nucleus of amygdala, CA1 subfield of Ammon`s horn, Inferior parietal lobule (lateral posterior cortex below the intraparietal sulcus), Lateral auditory field, Lateral intraparietal area, Medial basal nucleus of the amygdala, area 24, prosubiculum

Descendant targets:
Anterior inferotemporal area (dorsal), Anterior inferotemporal area (ventral), Area 10, Area 11, Area 12, Area 35, Area 36, Area 6, Area 8A, Basolateral nucleus of amygdala, CA1 subfield of Ammon`s horn, Caudal part of area 36, Central inferotemporal area, Central inferotemporal area (ventral), Cortical area 36p, Cortical area 45, Cortical area 46, Cortical area PGa, Cortical area TEm, Entorhinal cortex, Floor of superior temporal sulcus, Frontal eye field, Intraparietal sulcus associated area in the superior temporal sulcus, Lateral area 12, Lateral auditory field, Lateral field of entorhinal cortex, Lateral intraparietal area (external part), Lateral intraparietal area (internal part), Medial basal nucleus of the amygdala, Nucleus basalis thalami, Nucleus peripeduncularis thalami, Orbital area 12, Orbitofrontal area 13, Parasubiculum, Posterior inferotemporal area, Posterior inferotemporal area (ventral), Prefrontal area 47\/12, Presubiculum, Rostral part of area 36, Temporal area TF, Temporal area TH, Temporal parietooccipital associated area in superior temporal sulcus, Temporopolar area TG, Ventral area 46, Visual area 4, central nucleus of the amygdala, prosubiculum, temporal visual association area in the lower bank of the superior temporal sulcus

Sub-regions:
Anterior inferotemporal area (ventral), Central inferotemporal area

---
Region: Anterior inferotemporal area (ventral) (AITv)

Super-regions:
Anterior inferotemporal area (ventral) < Area 20 < Inferotemporal area TE < Temporal Lobe according to GM-Definition < GM-CerebralCortex < Brain

Sources:
Anterior inferotemporal area (dorsal), Area 35, Area 36, Basolateral nucleus of amygdala, CA1 subfield of Ammon`s horn, Caudal part of area 36, Central inferotemporal area, Central inferotemporal area (dorsal), Central inferotemporal area (ventral), Cortical area 36p, Entorhinal cortex, Lateral auditory field, Lateral field of entorhinal cortex, Medial basal nucleus of the amygdala, Nucleus peripeduncularis thalami, Parasubiculum, Periamygdaloid cortex 2, Posterior inferotemporal area, Posterior inferotemporal area (dorsal), Posterior inferotemporal area (ventral), Presubiculum, Rostral part of area 36, Superior temporal area 1, Superior temporal sulcus, Temporal area TF, Temporal area TH, Temporal proisocortex, Temporopolar area TG, Visual area 4, temporal visual association area in the lower bank of the superior temporal sulcus

Targets:
Anterior inferotemporal area (dorsal), Area 10, Area 11, Area 35, Area 36, Area 8A, Basolateral nucleus of amygdala, CA1 subfield of Ammon`s horn, Caudal part of area 36, Central inferotemporal area, Central inferotemporal area (ventral), Cortical area 36p, Cortical area PGa, Cortical area TEm, Entorhinal cortex, Floor of superior temporal sulcus, Intraparietal sulcus associated area in the superior temporal sulcus, Lateral area 12, Lateral auditory field, Lateral field of entorhinal cortex, Medial

basal nucleus of the amygdala, Nucleus basalis thalami, Nucleus peripeduncularis thalami, Orbital area 12, Parasubiculum, Posterior inferotemporal area, Posterior inferotemporal area (ventral), Prefrontal area 47\/12, Presubiculum, Rostral part of area 36, Temporal area TF, Temporal area TH, Temporal parietooccipital associated area in superior temporal sulcus, Temporopolar area TG, Visual area 4, central nucleus of the amygdala, prosubiculum, temporal visual association area in the lower bank of the superior temporal sulcus

---

Region: Central inferotemporal area (CIT)

Super-regions:
Central inferotemporal area < Area 20 < Inferotemporal area TE < Temporal Lobe according to GM-Definition < GM-CerebralCortex < Brain

Sources:
Anterior inferotemporal area (ventral), Basolateral nucleus of amygdala, CA1 subfield of Ammon`s horn, Cortical area 46, Entorhinal cortex, Frontal eye field, Lateral field of entorhinal cortex, Medial basal nucleus of the amygdala, Nucleus peripeduncularis thalami, Parasubiculum, Presubiculum, Temporal area TF, Temporal area TH, Temporoparietal asscociated area (caudal part)

Descendant sources:
Anterior inferotemporal area (dorsal), Anterior inferotemporal area (ventral), Area 12, Cortical area 45, Cortical area OAa, Cortical area TEm, Floor of superior temporal sulcus, Intraparietal sulcus associated area in the superior temporal sulcus, Lateral intraparietal area (external part), Lateral intraparietal area (internal part), Middle temporal area, Orbitofrontal area 13, Posterior inferotemporal area (dorsal), Posterior inferotemporal area (ventral), Superior temporal sulcus, Temporal area TF, Temporal proisocortex, Visual area 4, temporal visual association area in the lower bank of the superior temporal sulcus

Targets:
Anterior inferotemporal area (ventral), Basolateral nucleus of amygdala, CA1 subfield of Ammon`s horn, Cortical area 46, Entorhinal cortex, Frontal eye field, Lateral auditory field, Lateral field of entorhinal cortex, Medial basal nucleus of the amygdala, Nucleus peripeduncularis thalami, Parasubiculum, Presubiculum, Temporal area TF, Temporal area TH, prosubiculum

Descendant targets:
Anterior inferotemporal area (dorsal), Anterior inferotemporal area (ventral), Area 10, Area 11, Area 12, Area 6, Area 8A, Cortical area 45, Floor of superior temporal sulcus, Lateral area 12, Lateral intraparietal area (external part), Lateral intraparietal area (internal part), Orbital area 12, Orbitofrontal area 13, Posterior inferotemporal area (ventral), Prefrontal area 47\/12, Ventral area 46, Visual area 4

Sub-regions:
Central inferotemporal area (dorsal), Central inferotemporal area (ventral)

Region: Central inferotemporal area (dorsal) (CITd)

Super-regions:
Central inferotemporal area (dorsal) < Central inferotemporal area < Area 20 < Inferotemporal area TE < Temporal Lobe according to GM-Definition < GM-CerebralCortex < Brain

Sources:
Superior temporal sulcus, Visual area 4, temporal visual association area in the lower bank of the superior temporal sulcus

Targets:
Anterior inferotemporal area (dorsal), Anterior inferotemporal area (ventral), Area 8A, Floor of superior temporal sulcus, Lateral area 12, Posterior inferotemporal area (ventral), Ventral area 46, Visual area 4

Region: Central inferotemporal area (ventral) (CITv)

Super-regions:
Central inferotemporal area (ventral) < Central inferotemporal area < Area 20 < Inferotemporal area TE < Temporal Lobe according to GM-Definition < GM-CerebralCortex < Brain

Sources:
Anterior inferotemporal area (dorsal), Anterior inferotemporal area (ventral), Area 12, Cortical area 45, Cortical area OAa, Cortical area TEm, Floor of superior temporal sulcus, Intraparietal sulcus associated area in the superior temporal sulcus, Lateral intraparietal area (external part), Lateral intraparietal area (internal part), Middle temporal area, Orbitofrontal area 13, Posterior inferotemporal area (dorsal), Posterior inferotemporal area (ventral), Superior temporal sulcus, Temporal area TF, Temporal proisocortex, Visual area 4, temporal visual association area in the lower bank of the superior temporal sulcus

Targets:
Anterior inferotemporal area (dorsal), Anterior inferotemporal area (ventral), Area 10, Area 11, Area 12, Area 6, Cortical area 45, Floor of superior temporal sulcus, Lateral area 12, Lateral intraparietal area (external part), Lateral intraparietal area (internal part), Orbital area 12, Orbitofrontal area 13, Posterior inferotemporal area (ventral), Prefrontal area 47\/12, Ventral area 46, Visual area 4

Region: Area 21 (21)

Super-regions:
Area 21 < Inferotemporal area TE < Temporal Lobe according to GM-Definition < GM-CerebralCortex < Brain

Sources:
Area 7b, Basolateral nucleus of amygdala, Lateral intraparietal area, Medial basal nucleus of the amygdala, Nucleus basalis thalami, Nucleus pulvinaris inferior thalami, Nucleus pulvinaris thalami

Descendant sources:
Anterior inferotemporal area (dorsal), Anterior inferotemporal area (ventral), Area 12, Area 35, Area 36, Area 7a, Area 8, Basolateral nucleus of amygdala, Caudal area 8A, Caudal limiting field of entorhinal cortex, Central inferotemporal area (dorsal), Central inferotemporal area (ventral), Claustrum, Cortical amygdaloid nucleus, Cortical area 45, Cortical area 45A, Cortical area 45B, Cortical area 46, Cortical area OAa, Cortical area PGa, Dorsal prelunate gyrus, Dorsal visual area 3, Entorhinal cortex, Floor of superior temporal sulcus, Frontal eye field, Intermediate field of entorhinal cortex, Intraparietal sulcus associated area in the superior temporal sulcus, Lateral Geniculate Nucleus, Lateral auditory field, Lateral field of entorhinal cortex, Lateral intraparietal area, Lateral intraparietal area (external part), Lateral intraparietal area (internal part), Medial basal nucleus of the amygdala, Medial superior temporal area, Medial superior temporal area (dorsal), Middle temporal area, Nucleus basalis thalami, Nucleus limitans thalami, Nucleus paracentralis thalami, Nucleus parafascicularis thalami, Nucleus peripeduncularis thalami, Nucleus pulvinaris inferior thalami, Nucleus pulvinaris medialis thalami, Nucleus pulvinaris thalami,

Nucleus ventralis anterior thalami, pars magnocellularis, Olfactory field of entorhinal cortex, Parasubiculum, Posterior inferotemporal area, Posterior inferotemporal area (dorsal), Posterior parietal area, Presubiculum, Putamen; rostral, Rostral field of entorhinal cortex, Rostral part of area 36, Superior temporal sulcus, Temporal area TAa, Temporal area TF, Temporal area TH, Temporal parietooccipital associated area in superior temporal sulcus, Temporoparietal associated area (rostral part), Temporopolar area TG, V4 transitional area, Ventral intraparietal area, Ventral occipitotemporal area, Ventral visual area 3, Visual area 2, Visual area 3A, Visual area 4, Visual area 4 (dorsal part), Visual area 4 (ventral part), posterior lateral auditory area, temporal visual association area in the lower bank of the superior temporal sulcus

Targets:
Area 7b, Basolateral nucleus of amygdala, Lateral auditory field, Lateral intraparietal area, Nucleus basalis thalami

Descendant targets:
Anterior inferotemporal area (dorsal), Anterior inferotemporal area (ventral), Area 10, Area 11, Area 35, Area 36, Area 7a, Area 7b, Area 8A, Basolateral nucleus of amygdala, Caudal inferior parietal lobule, Caudal part of area 36, Central inferotemporal area (dorsal), Central inferotemporal area (ventral), Claustrum, Cortical area 36p, Cortical area 45, Cortical area 45A, Cortical area 46, Cortical area PGa, Dorsal prelunate gyrus, Dorsal visual area 3, Entorhinal cortex, Floor of superior temporal sulcus, Frontal eye field, Inferior parietal lobule (lateral posterior cortex below the intraparietal sulcus), Intraparietal sulcus associated area in the superior temporal sulcus, Lateral area 12, Lateral auditory field, Lateral intraparietal area (external part), Lateral intraparietal area (internal part), Lateral nucleus (amygdala), dorsal division, Lateral nucleus (amygdala), dorsal intermediate division, Lateral nucleus (amygdala), ventral division, Medial basal nucleus of the amygdala, Medial basal nucleus of the amygdala, Medial superior temporal area (dorsal), Middle temporal area, Nucleus basalis thalami, Nucleus caudatus, Nucleus caudatus; genu, Nucleus peripeduncularis thalami, Nucleus pulvinaris inferior thalami, Nucleus pulvinaris medialis thalami, Nucleus reticularis thalami, Orbital area 12, Parasubiculum, Posterior inferotemporal area, Posterior inferotemporal area (dorsal), Posterior inferotemporal area (ventral), Posterior parietal area, Prefrontal area 47\/12, Presubiculum, Putamen, Putamen; caudal, Rostral part of area 36, Superior temporal sulcus, Temporal area TAa, Temporal area TF, Temporal area TF (lateral part), Temporal area TF (medial part), Temporal area TH, Temporal parietooccipital associated area in superior temporal sulcus, Temporopolar area TG, V4 transitional area, Ventral area 46, Ventral intraparietal area, Ventral visual area 3, Visual area 1, Visual area 2, Visual area 3A, Visual area 4, posterior lateral auditory area

Sub-regions:
Anterior inferotemporal area (dorsal), Posterior inferotemporal area

---
Region: Anterior inferotemporal area (dorsal) (AITd)

Super-regions:
Anterior inferotemporal area (dorsal) < Area 21 < Inferotemporal area TE < Temporal Lobe according to GM-Definition < GM-CerebralCortex < Brain

Sources:
Anterior inferotemporal area (ventral), Area 12, Area 35, Area 7a, Area 8, Basolateral nucleus of amygdala, Central inferotemporal area (dorsal), Central inferotemporal area (ventral), Cortical area 46, Frontal eye field, Intraparietal sulcus associated area in the superior temporal sulcus, Nucleus basalis thalami, Nucleus peripeduncularis thalami, Nucleus pulvinaris inferior thalami, Nucleus pulvinaris medialis thalami, Parasubiculum, Posterior inferotemporal area, Posterior inferotemporal area (dorsal), Presubiculum, Rostral part of area 36, Temporal area TAa, Temporal area TF, Temporal area TH, Temporal parietooccipital associated area in superior temporal sulcus, Temporoparietal associated

area (rostral part), posterior lateral auditory area

Descendant sources:
Anterior inferotemporal area (ventral), Basolateral nucleus of amygdala, Cortical area 46, Cortical area OAa, Cortical area PGa, Floor of superior temporal sulcus, Intraparietal sulcus associated area in the superior temporal sulcus, Medial basal nucleus of the amygdala, Nucleus basalis thalami, Nucleus pulvinaris medialis thalami, Superior temporal sulcus, Temporal parietooccipital associated area in superior temporal sulcus, posterior lateral auditory area

Targets:
Anterior inferotemporal area (ventral), Area 35, Area 36, Area 7a, Area 7b, Basolateral nucleus of amygdala, Caudal part of area 36, Central inferotemporal area (ventral), Cortical area 36p, Cortical area 46, Cortical area PGa, Entorhinal cortex, Frontal eye field, Inferior parietal lobule (lateral posterior cortex below the intraparietal sulcus), Intraparietal sulcus associated area in the superior temporal sulcus, Lateral auditory field, Nucleus basalis thalami, Nucleus peripeduncularis thalami, Parasubiculum, Posterior inferotemporal area, Posterior inferotemporal area (dorsal), Posterior inferotemporal area (ventral), Presubiculum, Rostral part of area 36, Temporal area TAa, Temporal area TF, Temporal area TF (lateral part), Temporal area TF (medial part), Temporal area TH, Temporal parietooccipital associated area in superior temporal sulcus, Temporopolar area TG

Descendant targets:
Anterior inferotemporal area (ventral), Area 10, Area 11, Area 7b, Area 8A, Basolateral nucleus of amygdala, Caudal inferior parietal lobule, Central inferotemporal area (dorsal), Central inferotemporal area (ventral), Cortical area 45A, Lateral area 12, Lateral auditory field, Medial basal nucleus of the amygdala, Nucleus basalis thalami, Orbital area 12, Posterior inferotemporal area, Prefrontal area 47\/12, Temporal area TF, Temporopolar area TG, Ventral area 46, Visual area 1, Visual area 2

Sub-regions:
Cortical area TEm, temporal visual association area in the lower bank of the superior temporal sulcus

---
Region: temporal visual association area in the lower bank of the superior temporal sulcus (TEa#3)

Super-regions:
temporal visual association area in the lower bank of the superior temporal sulcus < Anterior inferotemporal area (dorsal) < Area 21 < Inferotemporal area TE < Temporal Lobe according to GM-Definition < GM-CerebralCortex < Brain

Sources:
Anterior inferotemporal area (ventral), Basolateral nucleus of amygdala, Cortical area 46, Cortical area OAa, Cortical area PGa, Floor of superior temporal sulcus, Intraparietal sulcus associated area in the superior temporal sulcus, Medial basal nucleus of the amygdala, Nucleus basalis thalami, Superior temporal sulcus, Temporal parietooccipital associated area in superior temporal sulcus

Targets:
Anterior inferotemporal area (ventral), Area 10, Area 11, Area 7b, Area 8A, Basolateral nucleus of amygdala, Caudal inferior parietal lobule, Central inferotemporal area (dorsal), Central inferotemporal area (ventral), Cortical area 45A, Lateral area 12, Lateral auditory field, Medial basal nucleus of the amygdala, Nucleus basalis thalami, Orbital area 12, Posterior inferotemporal area, Prefrontal area 47\/12, Temporal area TF, Ventral area 46

Region: Cortical area TEm (TEm)

Super-regions:
Cortical area TEm < Anterior inferotemporal area (dorsal) < Area 21 < Inferotemporal area TE < Temporal Lobe according to GM-Definition < GM-CerebralCortex < Brain

Sources:
Anterior inferotemporal area (ventral), Cortical area 46, Nucleus pulvinaris medialis thalami, Superior temporal sulcus, posterior lateral auditory area

Targets:
Caudal inferior parietal lobule, Central inferotemporal area (ventral), Cortical area 45A, Lateral area 12, Orbital area 12, Temporopolar area TG, Ventral area 46, Visual area 1, Visual area 2

Region: Posterior inferotemporal area (PIT)

Super-regions:
Posterior inferotemporal area < Area 21 < Inferotemporal area TE < Temporal Lobe according to GM-Definition < GM-CerebralCortex < Brain

Sources:
Anterior inferotemporal area (dorsal), Anterior inferotemporal area (ventral), Area 12, Area 35, Area 36, Area 7a, Basolateral nucleus of amygdala, Caudal area 8A, Caudal limiting field of entorhinal cortex, Claustrum, Cortical amygdaloid nucleus, Cortical area 45, Cortical area 45A, Cortical area 45B, Cortical area 46, Cortical area OAa, Cortical area PGa, Dorsal prelunate gyrus, Dorsal visual area 3, Entorhinal cortex, Floor of superior temporal sulcus, Frontal eye field, Intermediate field of entorhinal cortex, Intraparietal sulcus associated area in the superior temporal sulcus, Lateral Geniculate Nucleus, Lateral auditory field, Lateral field of entorhinal cortex, Lateral intraparietal area (external part), Lateral intraparietal area (internal part), Medial basal nucleus of the amygdala, Medial superior temporal area, Medial superior temporal area (dorsal), Middle temporal area, Nucleus basalis thalami, Nucleus limitans thalami, Nucleus paracentralis thalami, Nucleus parafascicularis thalami, Nucleus peripeduncularis thalami, Nucleus pulvinaris inferior thalami, Nucleus pulvinaris medialis thalami, Nucleus pulvinaris thalami, Nucleus ventralis anterior thalami, pars magnocellularis, Olfactory field of entorhinal cortex, Parasubiculum, Posterior parietal area, Presubiculum, Putamen; rostral, Rostral field of entorhinal cortex, Superior temporal sulcus, Temporal area TF, Temporal area TH, Temporopolar area TG, V4 transitional area, Ventral intraparietal area, Ventral visual area 3, Visual area 2, Visual area 3A, Visual area 4, Visual area 4 (dorsal part), Visual area 4 (ventral part), posterior lateral auditory area, temporal visual association area in the lower bank of the superior temporal sulcus

Descendant sources:
Anterior inferotemporal area (dorsal), Anterior inferotemporal area (ventral), Central inferotemporal area (dorsal), Central inferotemporal area (ventral), Cortical area PGa, Floor of superior temporal sulcus, Intraparietal sulcus associated area in the superior temporal sulcus, Lateral intraparietal area, Lateral intraparietal area (external part), Middle temporal area, Temporal area TF, Temporal area TH, V4 transitional area, Ventral occipitotemporal area, Ventral visual area 3, Visual area 2, Visual area 3A, Visual area 4, Visual area 4 (dorsal part), Visual area 4 (ventral part)

Targets:
Anterior inferotemporal area (dorsal), Anterior inferotemporal area (ventral), Area 36, Area 8A, Basolateral nucleus of amygdala, Caudal part of area 36, Claustrum, Cortical area 45, Cortical area 45A, Cortical area 46, Dorsal prelunate gyrus, Dorsal

visual area 3, Floor of superior temporal sulcus, Frontal eye field, Intraparietal sulcus associated area in the superior temporal sulcus, Lateral area 12, Lateral auditory field, Lateral intraparietal area (external part), Lateral intraparietal area (internal part), Lateral nucleus (amygdala), dorsal division, Lateral nucleus (amygdala), dorsal intermediate division, Lateral nucleus (amygdala), ventral division, Medial basal nucleus of the amygdala, Medial superior temporal area (dorsal), Middle temporal area, Nucleus caudatus, Nucleus caudatus; genu, Nucleus peripeduncularis thalami, Nucleus pulvinaris inferior thalami, Nucleus pulvinaris medialis thalami, Nucleus reticularis thalami, Parasubiculum, Posterior parietal area, Presubiculum, Putamen, Putamen; caudal, Rostral part of area 36, Superior temporal sulcus, Temporal area TF, Temporal area TF (lateral part), Temporal area TF (medial part), Temporal area TH, V4 transitional area, Ventral intraparietal area, Ventral visual area 3, Visual area 1, Visual area 2, Visual area 3A, Visual area 4, posterior lateral auditory area

Descendant targets:
Anterior inferotemporal area (dorsal), Anterior inferotemporal area (ventral), Central inferotemporal area (ventral), Cortical area 45A, Visual area 4

Sub-regions:
Posterior inferotemporal area (dorsal), Posterior inferotemporal area (ventral)

Region: Posterior inferotemporal area (dorsal) (PITd)

Super-regions:
Posterior inferotemporal area (dorsal) < Posterior inferotemporal area < Area 21 < Inferotemporal area TE < Temporal Lobe according to GM-Definition < GM-CerebralCortex < Brain

Sources:
Anterior inferotemporal area (dorsal), Floor of superior temporal sulcus, Intraparietal sulcus associated area in the superior temporal sulcus, Lateral intraparietal area (external part), Middle temporal area, V4 transitional area, Ventral occipitotemporal area, Ventral visual area 3, Visual area 2, Visual area 3A, Visual area 4, Visual area 4 (dorsal part), Visual area 4 (ventral part)

Targets:
Anterior inferotemporal area (dorsal), Anterior inferotemporal area (ventral), Central inferotemporal area (ventral), Cortical area 45A, Visual area 4

Region: Posterior inferotemporal area (ventral) (PITv)

Super-regions:
Posterior inferotemporal area (ventral) < Posterior inferotemporal area < Area 21 < Inferotemporal area TE < Temporal Lobe according to GM-Definition < GM-CerebralCortex < Brain

Sources:
Anterior inferotemporal area (dorsal), Anterior inferotemporal area (ventral), Central inferotemporal area (dorsal), Central inferotemporal area (ventral), Cortical area PGa, Floor of superior temporal sulcus, Intraparietal sulcus associated area in the superior temporal sulcus, Lateral intraparietal area, Temporal area TF, Temporal area TH, V4 transitional area, Ventral occipitotemporal area, Ventral visual area 3, Visual area 2, Visual area 4, Visual area 4 (dorsal part), Visual area 4 (ventral part)

Targets:

Anterior inferotemporal area (ventral), Central inferotemporal area (ventral), Visual area 4

Region: Superior temporal sulcus (STS)

Super-regions:
Superior temporal sulcus < Temporal Lobe according to GM-Definition < GM-CerebralCortex < Brain

Sources:
Area 10, Area 11, Area 12, Area 32, Area 7a, Area 8, Area 9, Corpus geniculatum mediale, Cortical area 46, Insula, Lateral auditory parakoniocortex, Lateral intraparietal area, Nucleus pulvinaris medialis thalami, Nucleus pulvinaris oralis thalami, Orbitofrontal area 14, Piriform cortex, Posterior inferotemporal area, Primary auditory cortex, Superior temporal area 1, Superior temporal area 2, Superior temporal area 3, Temporal proisocortex, Temporoparietal cortex, area 24, auditory prokoniocortex

Descendant sources:
Agranular frontal area 5 (= rostral ventrolateral premotor area), Anterior inferotemporal area (dorsal), Anterior inferotemporal area (ventral), Area 10, Area 11, Area 12, Area 23, Area 24a, Area 24b, Area 25, Area 29, Area 32, Area 36, Area 6 (ventral part), Area 7, Area 7a, Area 7b, Area 8, Area 8A, Area 9, Basolateral nucleus of amygdala, Caudal area 8A, Caudal inferior parietal lobule, Central amygdaloid nucleus, lateral part, Central inferotemporal area (dorsal), Central inferotemporal area (ventral), Centrum medianum thalami, Corpus geniculatum mediale, Cortical area 46, Cortical area OAa, Dorsal prelunate gyrus, Extrastriate area OA, Floor of superior temporal sulcus, Frontal eye field, Inferior parietal lobule (lateral posterior cortex below the intraparietal sulcus), Inferotemporal area TE, Intraparietal sulcus associated area in the superior temporal sulcus, Lateral auditory parakoniocortex, Lateral intraparietal area, Lateral intraparietal area (external part), Lateral intraparietal area (internal part), Medial area 9, Medial intraparietal area, Medial premotor area 6M, Medial superior temporal area, Medial superior temporal area (dorsal), Medial superior temporal area (posterior), Middle temporal area, Nucleus limitans thalami, Nucleus medialis dorsalis thalami, Nucleus paracentralis thalami, Nucleus parafascicularis thalami, Nucleus pulvinaris inferior thalami, Nucleus pulvinaris inferior thalami, central subdivision, Nucleus pulvinaris inferior thalami, lateral subdivision, Nucleus pulvinaris inferior thalami, pars medialis, Nucleus pulvinaris inferior thalami, pars posterior, Nucleus pulvinaris lateralis thalami pars ventrolateralis, Nucleus pulvinaris lateralis thalami pars ventromedialis, Nucleus pulvinaris medialis thalami, Nucleus pulvinaris oralis thalami, Nucleus pulvinaris thalami, pars oralis, Nucleus reuniens thalami, Nucleus suprageniculatus thalami, Nucleus ventralis posterior inferior thalami, Occipitoparietal area, Orbitofrontal area 14, Parietal area PG, medial part, Piriform cortex, Posterior inferotemporal area, Posterior intraparietal area, Primary auditory cortex, Principal Sulcus, Retrosplenial area 30, Rostral superior parietal lobule, Superior temporal area 1, Superior temporal area 2, Superior temporal area 3, Temporal area TAa, Temporal area TF, Temporal area TH, Temporoparietal asscociated area (caudal part), Temporoparietal associated area (intermediate part), Temporoparietal associated area (rostral part), Temporoparietal cortex, V4 transitional area, Ventral area 46, Ventral intraparietal area, Ventral posterior lateral nucleus (thalamus), Ventral visual area 3, Visual area 1, Visual area 2, Visual area 3, Visual area 3A, Visual area 4, Visual area 4 (dorsal part), Visual area V6A, area 24, auditory prokoniocortex, posterior lateral auditory area

Targets:
Agranular frontal area 6 (= pre-SMA), Agranular frontal area 7 (= rostral dorsolateral premotor area), Anterior inferotemporal area (ventral), Area 10, Area 11, Area 12, Area 25, Area 32, Area 35, Area 6, Area 7a, Area 8, Area 9, Caudal inferior parietal lobule, Central inferotemporal area (dorsal), Central inferotemporal area (ventral), Cortical area 46, Cortical area TEm, Extrastriate area OA, Lateral intraparietal area, Nucleus caudatus; genu, Occipitoparietal area, Orbitofrontal area 13, Orbitofrontal area 14, Posterior inferotemporal area, Temporal proisocortex, Visual area 4, area 24, temporal visual association area in the lower bank of the superior temporal sulcus

Descendant targets:
Agranular frontal area 2 (= caudal dorsolateral premotor area),

Anterior inferotemporal area (dorsal), Area 10, Area 11, Area 12, Area 23, Area 23b, Area 23c, Area 31, Area 32, Area 36, Area 6, Area 6 (ventral part), Area 7, Area 7a, Area 7b, Area 8, Area 8A, Area 8B, Area 9, Caudal and medial superior parietal lobule, Caudal auditory parakoniocortex, Caudal inferior parietal lobule, Caudal part of area 36, Central amygdaloid nucleus, lateral part, Central inferotemporal area, Central inferotemporal area (ventral), Corpus geniculatum mediale, Cortical area 45A, Cortical area 46, Cortical area 9\/46d, Dorsal portion of area 8A, Dorsal prelunate gyrus, Floor of superior temporal sulcus, Frontal eye field, Inferior parietal lobule (lateral posterior cortex below the intraparietal sulcus), Inferotemporal area TE, Intraparietal sulcus associated area in the superior temporal sulcus, Lateral area 12, Lateral auditory parakoniocortex, Lateral intraparietal area, Lateral nucleus (amygdala), dorsal division, Lateral nucleus (amygdala), dorsal intermediate division, Lateral nucleus (amygdala), ventral division, Medial superior temporal area (dorsal), Medial superior temporal area (posterior), Middle temporal area, Nucleus caudatus; genu, Nucleus limitans thalami, Nucleus medialis dorsalis thalami, Nucleus paracentralis thalami, Nucleus pulvinaris inferior thalami, Nucleus pulvinaris inferior thalami, central subdivision, Nucleus pulvinaris inferior thalami, lateral subdivision, Nucleus pulvinaris inferior thalami, pars medialis, Nucleus pulvinaris inferior thalami, pars posterior, Nucleus pulvinaris lateralis thalami pars ventrolateralis, Nucleus pulvinaris lateralis thalami pars ventromedialis, Nucleus pulvinaris medialis thalami, Nucleus pulvinaris oralis thalami, Nucleus pulvinaris thalami, pars oralis, Nucleus suprageniculatus thalami, Occipitoparietal area, Orbital area 12, Parietal area PE (cingulate part), Parietal area PG, medial part, Posterior inferotemporal area, Posterior inferotemporal area (dorsal), Posterior inferotemporal area (ventral), Posterior intraparietal area, Primary auditory cortex, Principal Sulcus, Putamen; caudal, Rostral part of area 36, Superior temporal area 1, Superior temporal area 2, Superior temporal area 3, Temporal area TF, Temporal area TF (lateral part), Temporal area TF (medial part), Temporal area TH, Temporoparietal asscociated area (caudal part), Temporoparietal associated area (intermediate part), Temporoparietal associated area (rostral part), Temporoparietal cortex, Temporopolar area TG, Transitional sensory area, V4 transitional area, Ventral area 46, Ventral intraparietal area, Ventral visual area 3, Visual area 1, Visual area 2, Visual area 3, Visual area 3A, Visual area 4, area 24, lateral nucleus (amygdala), ventrolateral subdivision, posterior lateral auditory area, temporal visual association area in the lower bank of the superior temporal sulcus

Sub-regions:
Cortical area OAa, Superior temporal sulcus, dorsal, Superior temporal sulcus, fundus

---
Region: Superior temporal sulcus, dorsal (STSd)

Super-regions:
Superior temporal sulcus, dorsal < Superior temporal sulcus < Temporal Lobe according to GM-Definition < GM-CerebralCortex < Brain

Sources:
Area 10, Area 11, Area 12, Area 32, Area 8, Area 9, Cortical area 46, Orbitofrontal area 14, area 24

Descendant sources:
Agranular frontal area 5 (= rostral ventrolateral premotor area), Anterior inferotemporal area (dorsal), Anterior inferotemporal area (ventral), Area 23, Area 25, Area 29, Area 32, Area 36, Area 7, Area 8A, Caudal inferior parietal lobule, Central amygdaloid nucleus, lateral part, Centrum medianum thalami, Corpus geniculatum mediale, Cortical area 46, Extrastriate area OA, Floor of superior temporal sulcus, Frontal eye field, Inferior parietal lobule (lateral posterior cortex below the intraparietal sulcus), Inferotemporal area TE, Lateral auditory parakoniocortex, Lateral intraparietal area, Medial area 9, Medial superior temporal area (dorsal), Medial superior temporal area (posterior), Nucleus limitans thalami, Nucleus medialis dorsalis thalami, Nucleus paracentralis thalami, Nucleus parafascicularis thalami, Nucleus pulvinaris inferior thalami, Nucleus pulvinaris medialis thalami, Nucleus pulvinaris oralis thalami, Nucleus reuniens thalami, Nucleus suprageniculatus thalami, Nucleus ventralis posterior inferior thalami,

Occipitoparietal area, Piriform cortex, Primary auditory cortex, Principal Sulcus, Retrosplenial area 30, Rostral superior parietal lobule, Superior temporal area 1, Superior temporal area 2, Superior temporal area 3, Temporal area TAa, Temporal area TF, Temporal area TH, Temporoparietal asscociated area (caudal part), Temporoparietal associated area (rostral part), Temporoparietal cortex, Ventral posterior lateral nucleus (thalamus), auditory prokoniocortex, posterior lateral auditory area

Targets:
Area 10, Area 12, Area 36, Area 6, Area 8, Area 9, Caudal part of area 36, Cortical area 46, Lateral nucleus (amygdala), dorsal division, Lateral nucleus (amygdala), dorsal intermediate division, Lateral nucleus (amygdala), ventral division, Rostral part of area 36, Temporal area TF (lateral part), Temporal area TF (medial part), Temporal area TH, lateral nucleus (amygdala), ventrolateral subdivision

Descendant targets:
Anterior inferotemporal area (dorsal), Area 11, Area 23, Area 23b, Area 23c, Area 31, Area 32, Area 36, Area 7, Area 7b, Area 8A, Area 8B, Area 9, Caudal auditory parakoniocortex, Caudal inferior parietal lobule, Central amygdaloid nucleus, lateral part, Central inferotemporal area, Corpus geniculatum mediale, Cortical area 46, Cortical area 9\/46d, Dorsal portion of area 8A, Floor of superior temporal sulcus, Frontal eye field, Inferior parietal lobule (lateral posterior cortex below the intraparietal sulcus), Inferotemporal area TE, Intraparietal sulcus associated area in the superior temporal sulcus, Lateral area 12, Lateral auditory parakoniocortex, Lateral intraparietal area, Medial superior temporal area (dorsal), Medial superior temporal area (posterior), Middle temporal area, Nucleus limitans thalami, Nucleus medialis dorsalis thalami, Nucleus paracentralis thalami, Nucleus pulvinaris medialis thalami, Nucleus pulvinaris oralis thalami, Nucleus suprageniculatus thalami, Occipitoparietal area, Orbital area 12, Parietal area PE (cingulate part), Parietal area PG, medial part, Primary auditory cortex, Principal Sulcus, Superior temporal area 1, Superior temporal area 2, Superior temporal area 3, Temporal area TF, Temporal area TH, Temporoparietal asscociated area (caudal part), Temporoparietal associated area (intermediate part), Temporoparietal associated area (rostral part), Temporoparietal cortex, Temporopolar area TG, Transitional sensory area, Ventral area 46, area 24, posterior lateral auditory area, temporal visual association area in the lower bank of the superior temporal sulcus

Sub-regions:
Temporal area TAa, Temporal parietooccipital associated area in superior temporal sulcus

---
Region: Temporal parietooccipital associated area in superior temporal sulcus (TPO)

Super-regions:
Temporal parietooccipital associated area in superior temporal sulcus < Superior temporal sulcus, dorsal < Superior temporal sulcus < Temporal Lobe according to GM-Definition < GM-CerebralCortex < Brain

Sources:
Agranular frontal area 5 (= rostral ventrolateral premotor area), Anterior inferotemporal area (dorsal), Anterior inferotemporal area (ventral), Area 25, Area 32, Area 7, Area 8A, Caudal inferior parietal lobule, Central amygdaloid nucleus, lateral part, Centrum medianum thalami, Corpus geniculatum mediale, Extrastriate area OA, Inferior parietal lobule (lateral posterior cortex below the intraparietal sulcus), Inferotemporal area TE, Lateral intraparietal area, Medial area 9, Nucleus limitans thalami, Nucleus medialis dorsalis thalami, Nucleus paracentralis thalami, Nucleus parafascicularis thalami, Nucleus pulvinaris inferior thalami, Nucleus pulvinaris medialis thalami, Nucleus pulvinaris oralis thalami, Nucleus reuniens thalami, Nucleus suprageniculatus thalami, Nucleus ventralis posterior inferior thalami, Principal Sulcus, Rostral superior parietal lobule, Ventral posterior lateral nucleus

(thalamus), posterior lateral auditory area

Descendant sources:
Area 23, Area 29, Cortical area 46, Floor of superior temporal sulcus, Frontal eye field, Lateral auditory parakoniocortex, Medial superior temporal area (dorsal), Medial superior temporal area (posterior), Occipitoparietal area, Retrosplenial area 30, Superior temporal area 1, Superior temporal area 2, Superior temporal area 3, Temporal area TAa, Temporal area TF, Temporal area TH, Temporoparietal asscociated area (caudal part), Temporoparietal associated area (rostral part), Temporoparietal cortex

Targets:
Anterior inferotemporal area (dorsal), Area 11, Area 23, Area 23b, Area 23c, Area 31, Area 32, Area 7b, Area 8A, Area 8B, Area 9, Caudal auditory parakoniocortex, Caudal inferior parietal lobule, Central amygdaloid nucleus, lateral part, Corpus geniculatum mediale, Cortical area 46, Cortical area 9\/46d, Dorsal portion of area 8A, Inferotemporal area TE, Lateral area 12, Lateral auditory parakoniocortex, Lateral intraparietal area, Nucleus limitans thalami, Nucleus medialis dorsalis thalami, Nucleus paracentralis thalami, Nucleus pulvinaris medialis thalami, Nucleus pulvinaris oralis thalami, Nucleus suprageniculatus thalami, Orbital area 12, Parietal area PE (cingulate part), Primary auditory cortex, Principal Sulcus, Superior temporal area 1, Superior temporal area 2, Superior temporal area 3, Temporoparietal cortex, Temporopolar area TG, Transitional sensory area, Ventral area 46, area 24, posterior lateral auditory area, temporal visual association area in the lower bank of the superior temporal sulcus

Descendant targets:
Anterior inferotemporal area (dorsal), Area 36, Area 7, Area 7b, Caudal inferior parietal lobule, Central amygdaloid nucleus, lateral part, Central inferotemporal area, Corpus geniculatum mediale, Cortical area 46, Floor of superior temporal sulcus, Frontal eye field, Inferior parietal lobule (lateral posterior cortex below the intraparietal sulcus), Inferotemporal area TE, Lateral auditory parakoniocortex, Medial superior temporal area (dorsal), Medial superior temporal area (posterior), Middle temporal area, Nucleus limitans thalami, Nucleus medialis dorsalis thalami, Nucleus paracentralis thalami, Nucleus pulvinaris medialis thalami, Nucleus pulvinaris oralis thalami, Nucleus suprageniculatus thalami, Occipitoparietal area, Parietal area PG, medial part, Superior temporal area 1, Superior temporal area 2, Superior temporal area 3, Temporal area TF, Temporal area TH, Temporoparietal asscociated area (caudal part), Temporoparietal associated area (rostral part), Temporoparietal cortex, Temporopolar area TG, posterior lateral auditory area

Sub-regions:
Temporoparietal asscociated area (caudal part), Temporoparietal associated area (intermediate part), Temporoparietal associated area (rostral part)

Region: Temporoparietal asscociated area (caudal part) (TPOc)

Super-regions:
Temporoparietal asscociated area (caudal part) < Temporal parietooccipital associated area in superior temporal sulcus < Superior temporal sulcus, dorsal < Superior temporal sulcus < Temporal Lobe according to GM-Definition < GM-CerebralCortex < Brain

Sources:
Area 23, Area 29, Cortical area 46, Floor of superior temporal sulcus, Frontal eye field, Lateral auditory parakoniocortex, Medial superior temporal area (dorsal), Medial superior temporal area (posterior), Occipitoparietal area, Retrosplenial area 30, Superior temporal area 1, Superior temporal area 2, Superior temporal area 3, Temporal area TAa, Temporal area TF,

Temporal area TH, Temporoparietal associated area (rostral part), Temporoparietal cortex

Targets:
Area 36, Area 7, Area 7b, Caudal inferior parietal lobule, Central amygdaloid nucleus, lateral part, Central inferotemporal area, Corpus geniculatum mediale, Cortical area 46, Floor of superior temporal sulcus, Frontal eye field, Inferior parietal lobule (lateral posterior cortex below the intraparietal sulcus), Inferotemporal area TE, Lateral auditory parakoniocortex, Medial superior temporal area (dorsal), Medial superior temporal area (posterior), Middle temporal area, Nucleus limitans thalami, Nucleus medialis dorsalis thalami, Nucleus paracentralis thalami, Nucleus pulvinaris medialis thalami, Nucleus pulvinaris oralis thalami, Nucleus supragenicularus thalami, Occipitoparietal area, Parietal area PG, medial part, Superior temporal area 1, Superior temporal area 2, Superior temporal area 3, Temporal area TF, Temporal area TH, Temporoparietal associated area (rostral part), Temporoparietal cortex, Temporopolar area TG, posterior lateral auditory area

---
Region: Temporoparietal associated area (intermediate part) (TPOi)

Super-regions:
Temporoparietal associated area (intermediate part) < Temporal parietooccipital associated area in superior temporal sulcus < Superior temporal sulcus, dorsal < Superior temporal sulcus < Temporal Lobe according to GM-Definition < GM-CerebralCortex < Brain

Sources:
Cortical area 46, Occipitoparietal area, Temporal area TAa

Targets:
Area 7, Area 7b, Medial superior temporal area (dorsal)

Region: Temporoparietal associated area (rostral part) (TPOr)

Super-regions:
Temporoparietal associated area (rostral part) < Temporal parietooccipital associated area in superior temporal sulcus < Superior temporal sulcus, dorsal < Superior temporal sulcus < Temporal Lobe according to GM-Definition < GM-CerebralCortex < Brain

Sources:
Cortical area 46, Occipitoparietal area, Temporal area TAa, Temporal area TF, Temporal area TH, Temporoparietal asscociated area (caudal part)

Targets:
Anterior inferotemporal area (dorsal), Area 36, Area 7, Area 7b, Caudal inferior parietal lobule, Corpus geniculatum mediale, Cortical area 46, Inferior parietal lobule (lateral posterior cortex below the intraparietal sulcus), Inferotemporal area TE, Lateral auditory parakoniocortex, Medial superior temporal area (dorsal), Nucleus medialis dorsalis thalami, Nucleus pulvinaris medialis thalami, Nucleus pulvinaris oralis thalami, Occipitoparietal area, Parietal area PG, medial part, Superior temporal area 1, Superior temporal area 2, Superior temporal area 3, Temporal area TF, Temporal area TH, Temporoparietal asscociated area (caudal part), Temporoparietal cortex, Temporopolar area TG

Region: Temporal area TAa (TAa)

Super-regions:
Temporal area TAa < Superior temporal sulcus, dorsal < Superior temporal sulcus < Temporal Lobe according to GM-Definition < GM-CerebralCortex < Brain

Sources:
Anterior inferotemporal area (dorsal), Area 23, Area 29, Area 36, Area 7, Area 8A, Inferior parietal lobule (lateral posterior cortex below the intraparietal sulcus), Inferotemporal area TE, Lateral auditory parakoniocortex, Occipitoparietal area, Piriform cortex, Primary auditory cortex, Principal Sulcus, Retrosplenial area 30, Rostral superior parietal lobule, Superior temporal area 1, Superior temporal area 2, Superior temporal area 3, Temporal area TH, Temporoparietal cortex, auditory prokoniocortex

Targets:
Anterior inferotemporal area (dorsal), Area 36, Area 8A, Area 9, Caudal auditory parakoniocortex, Cortical area 46, Dorsal portion of area 8A, Floor of superior temporal sulcus, Inferior parietal lobule (lateral posterior cortex below the intraparietal sulcus), Inferotemporal area TE, Intraparietal sulcus associated area in the superior temporal sulcus, Lateral auditory parakoniocortex, Medial superior temporal area (dorsal), Primary auditory cortex, Principal Sulcus, Superior temporal area 1, Superior temporal area 2, Superior temporal area 3, Temporal area TF, Temporoparietal asscociated area (caudal part), Temporoparietal associated area (intermediate part), Temporoparietal associated area (rostral part), Temporoparietal cortex, Temporopolar area TG

Region: Superior temporal sulcus, fundus (STSf)

Super-regions:
Superior temporal sulcus, fundus < Superior temporal sulcus < Temporal Lobe according to GM-Definition < GM-CerebralCortex < Brain

Descendant sources:
Anterior inferotemporal area (dorsal), Anterior inferotemporal area (ventral), Area 23, Area 7, Caudal inferior parietal lobule, Cortical area 46, Cortical area OAa, Extrastriate area OA, Inferior parietal lobule (lateral posterior cortex below the intraparietal sulcus), Inferotemporal area TE, Lateral intraparietal area, Occipitoparietal area, Posterior inferotemporal area, Principal Sulcus, Rostral superior parietal lobule, Temporal area TAa

Descendant targets:
Anterior inferotemporal area (dorsal), Area 11, Area 32, Area 36, Area 7b, Area 8A, Caudal inferior parietal lobule, Central inferotemporal area (ventral), Cortical area 45A, Inferior parietal lobule (lateral posterior cortex below the intraparietal sulcus), Inferotemporal area TE, Lateral area 12, Lateral auditory parakoniocortex, Lateral intraparietal area, Medial superior temporal area (dorsal), Middle temporal area, Nucleus limitans thalami, Nucleus paracentralis thalami, Nucleus pulvinaris inferior thalami, Nucleus pulvinaris medialis thalami, Occipitoparietal area, Orbital area 12, Posterior inferotemporal area, Posterior inferotemporal area (dorsal), Posterior inferotemporal area (ventral), Primary auditory cortex, Principal Sulcus, Superior temporal area 1, Superior temporal area 2, Superior temporal area 3, Temporal area TF, Temporoparietal cortex, Temporopolar area TG, Ventral area 46, Ventral intraparietal area, Visual area 1, temporal visual association area in the lower bank of the superior temporal sulcus

Sub-regions:
Cortical area PGa, Intraparietal sulcus associated area in the superior temporal sulcus

---

Region: Cortical area PGa (PGa)

Super-regions:
Cortical area PGa < Superior temporal sulcus, fundus < Superior temporal sulcus < Temporal Lobe according to GM-Definition < GM-CerebralCortex < Brain

Sources:
Anterior inferotemporal area (dorsal), Anterior inferotemporal area (ventral), Area 23, Area 7, Caudal inferior parietal lobule, Extrastriate area OA, Inferior parietal lobule (lateral posterior cortex below the intraparietal sulcus), Principal Sulcus, Rostral superior parietal lobule

Targets:
Area 11, Area 32, Area 36, Area 8A, Caudal inferior parietal lobule, Cortical area 45A, Inferior parietal lobule (lateral posterior cortex below the intraparietal sulcus), Inferotemporal area TE, Lateral area 12, Lateral auditory parakoniocortex, Lateral intraparietal area, Occipitoparietal area, Orbital area 12, Posterior inferotemporal area, Posterior inferotemporal area (ventral), Primary auditory cortex, Principal Sulcus, Superior temporal area 1, Superior temporal area 2, Superior temporal area 3, Temporal area TF, Temporoparietal cortex, Temporopolar area TG, Ventral area 46, Ventral intraparietal area, Visual area 1, temporal visual association area in the lower bank of the superior temporal sulcus

---
Region: Intraparietal sulcus associated area in the superior temporal sulcus (IPa)

Super-regions:
Intraparietal sulcus associated area in the superior temporal sulcus < Superior temporal sulcus, fundus < Superior temporal sulcus < Temporal Lobe according to GM-Definition < GM-CerebralCortex < Brain

Sources:
Anterior inferotemporal area (dorsal), Anterior inferotemporal area (ventral), Area 7, Cortical area 46, Cortical area OAa, Inferior parietal lobule (lateral posterior cortex below the intraparietal sulcus), Inferotemporal area TE, Lateral intraparietal area, Occipitoparietal area, Posterior inferotemporal area, Temporal area TAa

Targets:
Anterior inferotemporal area (dorsal), Area 11, Area 36, Area 7b, Area 8A, Caudal inferior parietal lobule, Central inferotemporal area (ventral), Cortical area 45A, Inferotemporal area TE, Lateral area 12, Lateral intraparietal area, Medial superior temporal area (dorsal), Middle temporal area, Nucleus limitans thalami, Nucleus paracentralis thalami, Nucleus pulvinaris inferior thalami, Nucleus pulvinaris medialis thalami, Orbital area 12, Posterior inferotemporal area, Posterior inferotemporal area (dorsal), Posterior inferotemporal area (ventral), Superior temporal area 2, Temporal area TF, Ventral area 46, Visual area 1, temporal visual association area in the lower bank of the superior temporal sulcus

---
Region: Cortical area OAa (OAa)

Super-regions:
Cortical area OAa < Superior temporal sulcus < Temporal Lobe according to GM-Definition < GM-CerebralCortex < Brain

Sources:
Cortical area 46, Inferotemporal area TE, Visual area 1

Descendant sources:
Anterior inferotemporal area (ventral), Area 24a, Area 24b, Area 36, Area 6 (ventral part), Area 7a, Area 7b, Area 8, Basolateral nucleus of amygdala, Caudal area 8A, Central inferotemporal area (dorsal), Central

inferotemporal area (ventral), Cortical area 46, Dorsal prelunate gyrus, Floor of superior temporal sulcus, Frontal eye field, Intraparietal sulcus associated area in the superior temporal sulcus, Lateral intraparietal area, Lateral intraparietal area (external part), Lateral intraparietal area (internal part), Medial intraparietal area, Medial premotor area 6M, Medial superior temporal area, Medial superior temporal area (dorsal), Medial superior temporal area (posterior), Middle temporal area, Nucleus pulvinaris inferior thalami, Nucleus pulvinaris inferior thalami, central subdivision, Nucleus pulvinaris inferior thalami, lateral subdivision, Nucleus pulvinaris inferior thalami, pars medialis, Nucleus pulvinaris inferior thalami, pars posterior, Nucleus pulvinaris lateralis thalami pars ventrolateralis, Nucleus pulvinaris lateralis thalami pars ventromedialis, Nucleus pulvinaris medialis thalami, Nucleus pulvinaris thalami, pars oralis, Occipitoparietal area, Parietal area PG, medial part, Posterior inferotemporal area, Posterior intraparietal area, Temporal area TAa, Temporal area TF, Temporal area TH, Temporoparietal asscociated area (caudal part), Temporoparietal associated area (intermediate part), Temporoparietal associated area (rostral part), V4 transitional area, Ventral area 46, Ventral intraparietal area, Ventral visual area 3, Visual area 1, Visual area 2, Visual area 3, Visual area 3A, Visual area 4, Visual area 4 (dorsal part), Visual area V6A, posterior lateral auditory area

Targets:
Area 36, Caudal inferior parietal lobule, Central inferotemporal area (ventral), Inferior parietal lobule (lateral posterior cortex below the intraparietal sulcus), Inferotemporal area TE, Intraparietal sulcus associated area in the superior temporal sulcus, Lateral intraparietal area, Posterior inferotemporal area, Temporal area TF, Ventral intraparietal area, Visual area 4, temporal visual association area in the lower bank of the superior temporal sulcus

Descendant targets:
Agranular frontal area 2 (= caudal dorsolateral premotor area), Area 23c, Area 31, Area 36, Area 6 (ventral part), Area 7, Area 7a, Area 7b, Area 8A, Caudal and medial superior parietal lobule, Caudal inferior parietal lobule, Central amygdaloid nucleus, lateral part, Central inferotemporal area (ventral), Cortical area 45A, Cortical area 46, Dorsal prelunate gyrus, Floor of superior temporal sulcus, Frontal eye field, Inferior parietal lobule (lateral posterior cortex below the intraparietal sulcus), Inferotemporal area TE, Lateral intraparietal area, Medial superior temporal area (dorsal), Medial superior temporal area (posterior), Middle temporal area, Nucleus caudatus; genu, Nucleus pulvinaris inferior thalami, Nucleus pulvinaris inferior thalami, central subdivision, Nucleus pulvinaris inferior thalami, lateral subdivision, Nucleus pulvinaris inferior thalami, pars medialis, Nucleus pulvinaris inferior thalami, pars posterior, Nucleus pulvinaris lateralis thalami pars ventrolateralis, Nucleus pulvinaris lateralis thalami pars ventromedialis, Nucleus pulvinaris medialis thalami, Nucleus pulvinaris oralis thalami, Nucleus pulvinaris thalami, pars oralis, Parietal area PE (cingulate part), Parietal area PG, medial part, Posterior inferotemporal area, Posterior inferotemporal area (dorsal), Posterior inferotemporal area (ventral), Posterior intraparietal area, Putamen; caudal, Temporal area TF, Temporoparietal asscociated area (caudal part), Transitional sensory area, V4 transitional area, Ventral area 46, Ventral intraparietal area, Ventral visual area 3, Visual area 1, Visual area 2, Visual area 3, Visual area 3A, Visual area 4, posterior lateral auditory area, temporal visual association area in the lower bank of the superior temporal sulcus

Sub-regions:
Floor of superior temporal sulcus, Medial superior temporal area, Middle temporal area, Peripheral part of area MT

Region: Middle temporal area (MT)

Super-regions:
Middle temporal area < Cortical area OAa < Superior temporal sulcus < Temporal Lobe according to GM-Definition < GM-CerebralCortex < Brain

Sources:
Area 6 (ventral part), Basolateral nucleus of amygdala, Dorsal prelunate gyrus, Floor of superior temporal sulcus, Intraparietal sulcus associated area in the superior temporal sulcus, Lateral intraparietal area, Lateral intraparietal area (internal part), Medial intraparietal area, Medial superior temporal area, Medial superior temporal area (dorsal), Medial superior temporal area (posterior), Nucleus pulvinaris inferior thalami, Nucleus pulvinaris inferior thalami, central subdivision, Nucleus pulvinaris inferior thalami, lateral subdivision, Nucleus pulvinaris inferior thalami, pars medialis, Nucleus pulvinaris inferior thalami, pars posterior, Nucleus pulvinaris lateralis thalami pars ventrolateralis, Nucleus pulvinaris lateralis thalami pars ventromedialis, Nucleus pulvinaris medialis thalami, Nucleus pulvinaris thalami, pars oralis, Occipitoparietal area, Posterior inferotemporal area, Posterior intraparietal area, Temporoparietal asscociated area (caudal part), V4 transitional area, Ventral intraparietal area, Ventral visual area 3, Visual area 1, Visual area 2, Visual area 3, Visual area 3A, Visual area 4, Visual area 4 (dorsal part), Visual area V6A, posterior lateral auditory area

Targets:
Area 36, Area 6 (ventral part), Area 7, Area 8A, Caudal inferior parietal lobule, Central amygdaloid nucleus, lateral part, Central inferotemporal area (ventral), Cortical area 45A, Cortical area 46, Floor of superior temporal sulcus, Frontal eye field, Inferotemporal area TE, Lateral intraparietal area, Medial superior temporal area (dorsal), Medial superior temporal area (posterior), Nucleus caudatus; genu, Nucleus pulvinaris inferior thalami, Nucleus pulvinaris inferior thalami, central subdivision, Nucleus pulvinaris inferior thalami, lateral subdivision, Nucleus pulvinaris inferior thalami, pars medialis, Nucleus pulvinaris inferior thalami, pars posterior, Nucleus pulvinaris lateralis thalami pars ventrolateralis, Nucleus pulvinaris lateralis thalami pars ventromedialis, Nucleus pulvinaris medialis thalami, Nucleus pulvinaris oralis thalami, Nucleus pulvinaris thalami, pars oralis, Posterior inferotemporal area, Posterior inferotemporal area (dorsal), Posterior intraparietal area, Putamen; caudal, V4 transitional area, Ventral area 46, Ventral intraparietal area, Ventral visual area 3, Visual area 1, Visual area 2, Visual area 3, Visual area 3A, Visual area 4, posterior lateral auditory area

---
Region: Peripheral part of area MT (MTp)

Super-regions:
Peripheral part of area MT < Cortical area OAa < Superior temporal sulcus < Temporal Lobe according to GM-Definition < GM-CerebralCortex < Brain

Sources:
Area 7b, Lateral intraparietal area, Parietal area PG, medial part, Visual area 2

Targets:
Area 7b, Area 8A, Lateral intraparietal area, Parietal area PG, medial part

---
Region: Floor of superior temporal sulcus (FST)

Super-regions:
Floor of superior temporal sulcus < Cortical area OAa < Superior temporal sulcus < Temporal Lobe according to GM-Definition < GM-CerebralCortex < Brain

Sources:
Anterior inferotemporal area (ventral), Area 36, Central inferotemporal area (dorsal), Central inferotemporal area (ventral), Dorsal prelunate gyrus, Frontal eye field, Lateral intraparietal area, Medial

superior temporal area (dorsal), Medial superior temporal area (posterior), Middle temporal area, Occipitoparietal area, Posterior inferotemporal area, Temporal area TAa, Temporal area TF, Temporal area TH, Temporoparietal asscociated area (caudal part), V4 transitional area, Ventral intraparietal area, Ventral visual area 3, Visual area 2, Visual area 3, Visual area 3A, Visual area 4

Targets:
Area 6 (ventral part), Area 7a, Area 8A, Caudal inferior parietal lobule, Central inferotemporal area (ventral), Cortical area 45A, Frontal eye field, Inferior parietal lobule (lateral posterior cortex below the intraparietal sulcus), Inferotemporal area TE, Lateral intraparietal area, Medial superior temporal area (dorsal), Medial superior temporal area (posterior), Middle temporal area, Nucleus caudatus; genu, Posterior inferotemporal area, Posterior inferotemporal area (dorsal), Posterior inferotemporal area (ventral), Temporal area TF, Temporoparietal asscociated area (caudal part), V4 transitional area, Ventral intraparietal area, Visual area 3, Visual area 3A, Visual area 4, temporal visual association area in the lower bank of the superior temporal sulcus

---

Region: Medial superior temporal area (MST)

Super-regions:
Medial superior temporal area < Cortical area OAa < Superior temporal sulcus < Temporal Lobe according to GM-Definition < GM-CerebralCortex < Brain

Sources:
Area 7b, Basolateral nucleus of amygdala, Cortical area 46, Occipitoparietal area, Parietal area PG, medial part, Visual area 2

Descendant sources:
Area 24a, Area 24b, Area 7a, Area 8, Caudal area 8A, Cortical area 46, Dorsal prelunate gyrus, Floor of superior temporal sulcus, Frontal eye field, Intraparietal sulcus associated area in the superior temporal sulcus, Lateral intraparietal area, Lateral intraparietal area (external part), Lateral intraparietal area (internal part), Medial intraparietal area, Medial premotor area 6M, Middle temporal area, Nucleus pulvinaris thalami, pars oralis, Posterior inferotemporal area, Posterior intraparietal area, Temporal area TAa, Temporal area TF, Temporal area TH, Temporoparietal asscociated area (caudal part), Temporoparietal associated area (intermediate part), Temporoparietal associated area (rostral part), V4 transitional area, Ventral area 46, Ventral intraparietal area, Ventral visual area 3, Visual area 1, Visual area 2, Visual area 3, Visual area 3A, Visual area 4 (dorsal part)

Targets:
Agranular frontal area 2 (= caudal dorsolateral premotor area), Area 23c, Area 31, Area 6 (ventral part), Area 7b, Area 8A, Caudal and medial superior parietal lobule, Caudal inferior parietal lobule, Cortical area 45A, Lateral intraparietal area, Middle temporal area, Nucleus caudatus; genu, Parietal area PE (cingulate part), Parietal area PG, medial part, Posterior inferotemporal area, Transitional sensory area

Descendant targets:
Area 7, Area 7a, Dorsal prelunate gyrus, Floor of superior temporal sulcus, Frontal eye field, Lateral intraparietal area, Middle temporal area, Nucleus pulvinaris thalami, pars oralis, Posterior inferotemporal area, Temporoparietal asscociated area (caudal part), V4 transitional area, Ventral intraparietal area, Ventral visual area 3, Visual area 2, Visual area 3, Visual area 3A

Sub-regions:
Medial superior temporal area (dorsal), Medial superior temporal area (posterior)

Region: Medial superior temporal area (posterior) (MSTp)

Super-regions:
Medial superior temporal area (posterior) < Medial superior temporal area < Cortical area OAa < Superior temporal sulcus < Temporal Lobe according to GM-Definition < GM-CerebralCortex < Brain

Sources:
Dorsal prelunate gyrus, Floor of superior temporal sulcus, Frontal eye field, Lateral intraparietal area, Middle temporal area, Nucleus pulvinaris thalami, pars oralis, Temporoparietal asscociated area (caudal part), V4 transitional area, Ventral intraparietal area, Visual area 1, Visual area 2, Visual area 3A

Targets:
Floor of superior temporal sulcus, Frontal eye field, Middle temporal area, Nucleus pulvinaris thalami, pars oralis, Temporoparietal asscociated area (caudal part), Ventral intraparietal area, Visual area 2, Visual area 3A

Region: Medial superior temporal area (dorsal) (MSTd)

Super-regions:
Medial superior temporal area (dorsal) < Medial superior temporal area < Cortical area OAa < Superior temporal sulcus < Temporal Lobe according to GM-Definition < GM-CerebralCortex < Brain

Sources:
Area 24a, Area 24b, Area 7a, Area 8, Caudal area 8A, Cortical area 46, Dorsal prelunate gyrus, Floor of superior temporal sulcus, Frontal eye field, Intraparietal sulcus associated area in the superior temporal sulcus, Lateral intraparietal area, Lateral intraparietal area (external part), Lateral intraparietal area (internal part), Medial intraparietal area, Medial premotor area 6M, Middle temporal area, Nucleus pulvinaris thalami, pars oralis, Posterior inferotemporal area, Posterior intraparietal area, Temporal area TAa, Temporal area TF, Temporal area TH, Temporoparietal asscociated area (caudal part), Temporoparietal associated area (intermediate part), Temporoparietal associated area (rostral part), V4 transitional area, Ventral area 46, Ventral intraparietal area, Ventral visual area 3, Visual area 2, Visual area 3, Visual area 3A, Visual area 4 (dorsal part)

Targets:
Area 7, Area 7a, Dorsal prelunate gyrus, Floor of superior temporal sulcus, Frontal eye field, Lateral intraparietal area, Middle temporal area, Nucleus pulvinaris thalami, pars oralis, Posterior inferotemporal area, Temporoparietal asscociated area (caudal part), V4 transitional area, Ventral intraparietal area, Ventral visual area 3, Visual area 2, Visual area 3, Visual area 3A

Region: Striate cortex (OC#2)

Super-regions:
Striate cortex < GM-CerebralCortex < Brain

Descendant sources:
Agranular frontal area 2 (= caudal dorsolateral premotor area), Agranular frontal area 5 (= rostral ventrolateral premotor area), Agranular frontal area 6 (= pre-SMA), Agranular frontal area 7 (= rostral dorsolateral premotor area), Anterior inferotemporal area (ventral), Area 6 (ventral part), Area 7a, Basolateral nucleus of amygdala, Caudal and medial superior parietal lobule, Caudal inferior parietal lobule, Central inferotemporal area (dorsal),

Central inferotemporal area (ventral), Claustrum, Cortical area 45, Cortical area 46, Cortical area OAa, Cortical area PGa, Cortical area TEm, Dorsal prelunate gyrus, Dorsal visual area 3, Extrastriate area OA, Floor of superior temporal sulcus, Frontal eye field, Hypothalamus, Inferior parietal lobule (lateral posterior cortex below the intraparietal sulcus), Inferotemporal area TE, Intralaminar nuclei of the thalamus, Intraparietal sulcus associated area in the superior temporal sulcus, Lateral Geniculate Nucleus, Lateral auditory field, Lateral intraparietal area, Lateral intraparietal area (internal part), Medial basal nucleus of the amygdala, Medial intraparietal area, Medial superior temporal area, Medial superior temporal area (dorsal), Medial superior temporal area (posterior), Middle temporal area, Nucleus basalis thalami, Nucleus limitans thalami, Nucleus pulvinaris inferior thalami, Nucleus pulvinaris inferior thalami, central subdivision, Nucleus pulvinaris inferior thalami, lateral subdivision, Nucleus pulvinaris inferior thalami, pars medialis, Nucleus pulvinaris inferior thalami, pars posterior, Nucleus pulvinaris inferior thalami, shell of the lateral subdivision, Nucleus pulvinaris lateralis thalami pars alpha, Nucleus pulvinaris lateralis thalami pars ventrolateralis, Nucleus pulvinaris lateralis thalami pars ventromedialis, Nucleus pulvinaris medialis thalami, Nucleus pulvinaris thalami, Nucleus pulvinaris thalami, pars oralis, Occipitoparietal area, Parietal area PE (cingulate part), Parietal area PG, medial part, Posterior inferotemporal area, Posterior inferotemporal area (dorsal), Posterior inferotemporal area (ventral), Posterior intraparietal area, Primary sensory cortex, Principal Sulcus, Rostral superior parietal lobule, Superior temporal sulcus, Temporal area TF, Temporal area TH, V4 transitional area, Ventral intraparietal area, Ventral occipitotemporal area, Ventral posterior parietal area, Ventral visual area 3, Visual area 1, Visual area 2, Visual area 3, Visual area 3A, Visual area 4, Visual area 4 (dorsal part), Visual area 4 (ventral part), Visual area V6A, dorsointermediate visual field, dorsolateral visual cortex, caudal part, dorsolateral visual cortex, rostral part, posterior lateral auditory area

Descendant targets:

Agranular frontal area 2 (= caudal dorsolateral premotor area), Agranular frontal area 3 (= SMA-proper), Agranular frontal area 5 (= rostral ventrolateral premotor area), Agranular frontal area 6 (= pre-SMA), Agranular frontal area 7 (= rostral dorsolateral premotor area), Anterior inferotemporal area (ventral), Anterior intraparietal area, Area 10, Area 23, Area 23b, Area 23c, Area 24c (rostral part of the cingulate sulcus), Area 31, Area 32, Area 36, Area 6, Area 6 (ventral part), Area 7a, Area 8, Area 8A, Area 8B, Caudal and medial superior parietal lobule, Caudal inferior parietal lobule, Central amygdaloid nucleus, lateral part, Central inferotemporal area (dorsal), Central inferotemporal area (ventral), Cortical area 45A, Cortical area 46, Cortical area 9\/46d, Cortical area OAa, Cortical area PGa, Dorsal portion of area 8A, Dorsal prelunate gyrus, Dorsal visual area 3, Extrastriate area OA, Floor of superior temporal sulcus, Frontal eye field, Inferior parietal lobule (lateral posterior cortex below the intraparietal sulcus), Inferotemporal area TE, Lateral Geniculate Nucleus, Lateral intraparietal area, Lateral intraparietal area (external part), Lateral intraparietal area (internal part), Laterodorsal nucleus (thalamus), Medial basal nucleus of the amygdala, Medial intraparietal area, Medial superior temporal area, Medial superior temporal area (dorsal), Medial superior temporal area (posterior), Middle temporal area, Nucleus caudatus, Nucleus caudatus; genu, Nucleus caudatus; tail, Nucleus centralis superior lateralis thalami, Nucleus paracentralis thalami, Nucleus pulvinaris inferior thalami, Nucleus pulvinaris inferior thalami, central subdivision, Nucleus pulvinaris inferior thalami, lateral subdivision, Nucleus pulvinaris inferior thalami, pars medialis, Nucleus pulvinaris inferior thalami, shell of the lateral subdivision, Nucleus pulvinaris medialis thalami, Nucleus pulvinaris oralis thalami, Nucleus pulvinaris thalami, Nucleus pulvinaris thalami, pars oralis, Nucleus reticularis thalami, Nucleus ventralis lateralis thalami, pars postrema, Parietal area PE (cingulate part), Parietal area PG, medial part, Peripheral part of area MT, Posterior inferotemporal area, Posterior inferotemporal area (dorsal), Posterior inferotemporal area (ventral), Posterior intraparietal area, Premotor area 6 (dorsal part), Primary motor area, Principal Sulcus, Prostriate cortex, Putamen; caudal, Temporal area TF, Temporal area TF (lateral part), Temporal area TF (medial part), Temporal area TH, Temporal parietooccipital associated area in superior temporal sulcus, V4 transitional area, Ventral intraparietal area, Ventral occipitotemporal area, Ventral posterior lateral nucleus (thalamus), Ventral posterior parietal area, Ventral visual area 3, Visual area 1, Visual area 2, Visual area 3, Visual area 3A, Visual area 4, Visual area 4 (dorsal part), Visual area 4 (ventral part), Visual area V6A, dorsointermediate visual field, dorsolateral visual cortex, caudal part, dorsolateral visual cortex, rostral part, posterior lateral auditory area

Sub-regions:

Prostriate cortex, Visual anterior cortex, Visual area 1, Visual

area 2

Region: Visual anterior cortex (VAC)

Super-regions:
Visual anterior cortex < Striate cortex < GM-CerebralCortex < Brain

Descendant sources:
Agranular frontal area 2 (= caudal dorsolateral premotor area), Agranular frontal area 5 (= rostral ventrolateral premotor area), Agranular frontal area 6 (= pre-SMA), Agranular frontal area 7 (= rostral dorsolateral premotor area), Anterior inferotemporal area (ventral), Area 6 (ventral part), Area 7a, Basolateral nucleus of amygdala, Caudal and medial superior parietal lobule, Caudal inferior parietal lobule, Central inferotemporal area (dorsal), Central inferotemporal area (ventral), Claustrum, Cortical area 45, Cortical area 46, Cortical area OAa, Dorsal prelunate gyrus, Dorsal visual area 3, Floor of superior temporal sulcus, Frontal eye field, Hypothalamus, Inferior parietal lobule (lateral posterior cortex below the intraparietal sulcus), Inferotemporal area TE, Lateral Geniculate Nucleus, Lateral auditory field, Lateral intraparietal area, Lateral intraparietal area (internal part), Medial intraparietal area, Medial superior temporal area, Medial superior temporal area (dorsal), Medial superior temporal area (posterior), Middle temporal area, Nucleus basalis thalami, Nucleus limitans thalami, Nucleus pulvinaris inferior thalami, Nucleus pulvinaris inferior thalami, central subdivision, Nucleus pulvinaris inferior thalami, lateral subdivision, Nucleus pulvinaris inferior thalami, pars medialis, Nucleus pulvinaris inferior thalami, pars posterior, Nucleus pulvinaris lateralis thalami pars ventrolateralis, Nucleus pulvinaris lateralis thalami pars ventromedialis, Nucleus pulvinaris medialis thalami, Nucleus pulvinaris thalami, Nucleus pulvinaris thalami, pars oralis, Occipitoparietal area, Parietal area PE (cingulate part), Parietal area PG, medial part, Posterior inferotemporal area, Posterior inferotemporal area (dorsal), Posterior inferotemporal area (ventral), Posterior intraparietal area, Primary sensory cortex, Principal Sulcus, Rostral superior parietal lobule, Superior temporal sulcus, Temporal area TF, Temporal area TH, V4 transitional area, Ventral intraparietal area, Ventral occipitotemporal area, Ventral posterior parietal area, Ventral visual area 3, Visual area 1, Visual area 2, Visual area 3, Visual area 3A, Visual area 4, Visual area 4 (ventral part), Visual area V6A, dorsointermediate visual field, dorsolateral visual cortex, caudal part, dorsolateral visual cortex, rostral part, posterior lateral auditory area

Descendant targets:
Agranular frontal area 2 (= caudal dorsolateral premotor area), Agranular frontal area 3 (= SMA-proper), Agranular frontal area 5 (= rostral ventrolateral premotor area), Agranular frontal area 6 (= pre-SMA), Agranular frontal area 7 (= rostral dorsolateral premotor area), Anterior inferotemporal area (ventral), Anterior intraparietal area, Area 23, Area 23b, Area 23c, Area 31, Area 32, Area 36, Area 6, Area 6 (ventral part), Area 7a, Area 8A, Area 8B, Caudal and medial superior parietal lobule, Caudal inferior parietal lobule, Central amygdaloid nucleus, lateral part, Central inferotemporal area (dorsal), Central inferotemporal area (ventral), Cortical area 45A, Cortical area 46, Cortical area 9\/46d, Cortical area PGa, Dorsal portion of area 8A, Dorsal prelunate gyrus, Floor of superior temporal sulcus, Frontal eye field, Inferior parietal lobule (lateral posterior cortex below the intraparietal sulcus), Inferotemporal area TE, Lateral Geniculate Nucleus, Lateral intraparietal area, Lateral intraparietal area (external part), Lateral intraparietal area (internal part), Laterodorsal nucleus (thalamus), Medial basal nucleus of the amygdala, Medial intraparietal area, Medial superior temporal area (dorsal), Medial superior temporal area (posterior), Middle temporal area, Nucleus caudatus, Nucleus caudatus; genu, Nucleus caudatus; tail, Nucleus centralis superior lateralis thalami, Nucleus paracentralis thalami, Nucleus pulvinaris inferior thalami, Nucleus pulvinaris inferior thalami, central subdivision, Nucleus pulvinaris inferior thalami, lateral subdivision, Nucleus pulvinaris medialis thalami, Nucleus pulvinaris oralis thalami, Nucleus pulvinaris thalami, Nucleus pulvinaris thalami, pars oralis, Nucleus reticularis thalami, Nucleus ventralis lateralis thalami, pars postrema, Parietal area PE (cingulate part), Parietal area PG, medial part, Posterior inferotemporal area, Posterior inferotemporal area (dorsal), Posterior inferotemporal area (ventral), Posterior intraparietal area, Premotor area 6 (dorsal part), Primary

motor area, Principal Sulcus, Putamen; caudal, Temporal area TF, Temporal area TF (lateral part), Temporal area TF (medial part), Temporal area TH, Temporal parietooccipital associated area in superior temporal sulcus, V4 transitional area, Ventral intraparietal area, Ventral occipitotemporal area, Ventral posterior lateral nucleus (thalamus), Ventral visual area 3, Visual area 1, Visual area 2, Visual area 3, Visual area 3A, Visual area 4, Visual area 4 (ventral part), Visual area V6A, posterior lateral auditory area

Sub-regions:
Extrastriate area OA, Ventral occipitotemporal area

Region: Extrastriate area OA (OA)

Super-regions:
Extrastriate area OA < Visual anterior cortex < Striate cortex < GM-CerebralCortex < Brain

Sources:
Hypothalamus, Inferior parietal lobule (lateral posterior cortex below the intraparietal sulcus), Inferotemporal area TE, Lateral intraparietal area, Nucleus pulvinaris inferior thalami, Nucleus pulvinaris thalami, Primary sensory cortex, Principal Sulcus, Superior temporal sulcus, Temporal area TF, Visual area 2

Descendant sources:
Agranular frontal area 2 (= caudal dorsolateral premotor area), Agranular frontal area 5 (= rostral ventrolateral premotor area), Agranular frontal area 6 (= pre-SMA), Agranular frontal area 7 (= rostral dorsolateral premotor area), Anterior inferotemporal area (ventral), Area 6 (ventral part), Area 7a, Basolateral nucleus of amygdala, Caudal and medial superior parietal lobule, Caudal inferior parietal lobule, Central inferotemporal area (dorsal), Central inferotemporal area (ventral), Claustrum, Cortical area 45, Cortical area 46, Cortical area OAa, Dorsal prelunate gyrus, Dorsal visual area 3, Floor of superior temporal sulcus, Frontal eye field, Inferotemporal area TE, Lateral Geniculate Nucleus, Lateral auditory field, Lateral intraparietal area, Lateral intraparietal area (internal part), Medial intraparietal area, Medial superior temporal area, Medial superior temporal area (dorsal), Medial superior temporal area (posterior), Middle temporal area, Nucleus basalis thalami, Nucleus limitans thalami, Nucleus pulvinaris inferior thalami, Nucleus pulvinaris inferior thalami, central subdivision, Nucleus pulvinaris inferior thalami, lateral subdivision, Nucleus pulvinaris inferior thalami, pars medialis, Nucleus pulvinaris inferior thalami, pars posterior, Nucleus pulvinaris lateralis thalami pars ventrolateralis, Nucleus pulvinaris lateralis thalami pars ventromedialis, Nucleus pulvinaris medialis thalami, Nucleus pulvinaris thalami, pars oralis, Occipitoparietal area, Parietal area PE (cingulate part), Parietal area PG, medial part, Posterior inferotemporal area, Posterior inferotemporal area (dorsal), Posterior inferotemporal area (ventral), Posterior intraparietal area, Rostral superior parietal lobule, Superior temporal sulcus, Temporal area TF, Temporal area TH, V4 transitional area, Ventral intraparietal area, Ventral occipitotemporal area, Ventral posterior parietal area, Ventral visual area 3, Visual area 1, Visual area 2, Visual area 3, Visual area 3A, Visual area 4, Visual area 4 (ventral part), Visual area V6A, dorsointermediate visual field, dorsolateral visual cortex, caudal part, dorsolateral visual cortex, rostral part, posterior lateral auditory area

Targets:
Agranular frontal area 7 (= rostral dorsolateral premotor area), Area 23, Area 23b, Area 36, Area 8B, Caudal inferior parietal lobule, Cortical area 46, Cortical area 9\/46d, Cortical area PGa, Dorsal portion of area 8A, Inferotemporal area TE, Lateral Geniculate Nucleus, Lateral intraparietal area, Lateral intraparietal area (external part), Lateral intraparietal area (internal part), Laterodorsal nucleus (thalamus), Medial basal nucleus of the amygdala, Nucleus caudatus, Nucleus caudatus; genu, Nucleus pulvinaris inferior thalami, Nucleus reticularis thalami, Principal Sulcus, Putamen; caudal, Temporal area TF, Temporal parietooccipital associated area in superior temporal sulcus, Visual area 2, posterior lateral auditory area

Descendant targets:
Agranular frontal area 2 (= caudal dorsolateral premotor area), Agranular frontal area 3 (= SMA-proper), Agranular frontal area 5 (= rostral ventrolateral premotor area), Agranular frontal area 6 (= pre-SMA), Agranular frontal area 7 (= rostral dorsolateral premotor area), Anterior inferotemporal area (ventral), Anterior intraparietal area, Area 23, Area 23c, Area 31, Area 32, Area 6, Area 6 (ventral part), Area 7a, Area 8A, Caudal and medial superior parietal lobule, Caudal inferior parietal lobule, Central amygdaloid nucleus, lateral part, Central inferotemporal area (dorsal), Central inferotemporal area (ventral), Cortical area 45A, Cortical area 46, Dorsal prelunate gyrus, Floor of superior temporal sulcus, Frontal eye field, Inferior parietal lobule (lateral posterior cortex below the intraparietal sulcus), Lateral intraparietal area, Lateral intraparietal area (internal part), Laterodorsal nucleus (thalamus), Medial intraparietal area, Medial superior temporal area (dorsal), Medial superior temporal area (posterior), Middle temporal area, Nucleus caudatus, Nucleus caudatus; genu, Nucleus caudatus; tail, Nucleus centralis superior lateralis thalami, Nucleus paracentralis thalami, Nucleus pulvinaris inferior thalami, Nucleus pulvinaris inferior thalami, central subdivision, Nucleus pulvinaris inferior thalami, lateral subdivision, Nucleus pulvinaris medialis thalami, Nucleus pulvinaris oralis thalami, Nucleus pulvinaris thalami, Nucleus pulvinaris thalami, pars oralis, Nucleus ventralis lateralis thalami, pars postrema, Parietal area PE (cingulate part), Parietal area PG, medial part, Posterior inferotemporal area, Posterior inferotemporal area (dorsal), Posterior inferotemporal area (ventral), Posterior intraparietal area, Premotor area 6 (dorsal part), Primary motor area, Putamen; caudal, Temporal area TF, Temporal area TF (lateral part), Temporal area TF (medial part), Temporal area TH, V4 transitional area, Ventral intraparietal area, Ventral occipitotemporal area, Ventral posterior lateral nucleus (thalamus), Ventral visual area 3, Visual area 1, Visual area 2, Visual area 3, Visual area 3A, Visual area 4, Visual area 4 (ventral part), Visual area V6A, posterior lateral auditory area

Sub-regions:
Dorsal prelunate gyrus, Nucleus pulvinaris thalami, pars oralis, Ventral posterior parietal area, Visual area 3, Visual area 3A, Visual area 4, dorsointermediate visual field

---
Region: Visual area 3A (V3A)

Super-regions:
Visual area 3A < Extrastriate area OA < Visual anterior cortex < Striate cortex < GM-CerebralCortex < Brain

Sources:
Area 6 (ventral part), Dorsal prelunate gyrus, Floor of superior temporal sulcus, Lateral intraparietal area, Medial intraparietal area, Medial superior temporal area (dorsal), Medial superior temporal area (posterior), Middle temporal area, Posterior inferotemporal area, Ventral intraparietal area, Ventral visual area 3, Visual area 1, Visual area 2, Visual area 4

Targets:
Area 8A, Cortical area 45A, Dorsal prelunate gyrus, Floor of superior temporal sulcus, Frontal eye field, Lateral intraparietal area, Medial intraparietal area, Medial superior temporal area (dorsal), Medial superior temporal area (posterior), Middle temporal area, Nucleus pulvinaris thalami, pars oralis, Posterior inferotemporal area, Posterior inferotemporal area (dorsal), Ventral intraparietal area, Ventral visual area 3, Visual area 1, Visual area 2, Visual area 4

Region: Visual area 3 (V3)

Super-regions:
Visual area 3 < Extrastriate area OA < Visual anterior cortex < Striate cortex < GM-

CerebralCortex < Brain

Sources:
Area 6 (ventral part), Floor of superior temporal sulcus, Inferotemporal area TE, Lateral intraparietal area, Medial superior temporal area (dorsal), Middle temporal area, Posterior intraparietal area, Temporal area TF, V4 transitional area, Ventral intraparietal area, Visual area 1, Visual area 2, Visual area 4, Visual area V6A, posterior lateral auditory area

Descendant sources:
Lateral intraparietal area, Lateral intraparietal area (internal part), Medial superior temporal area (dorsal), Middle temporal area, Posterior inferotemporal area, Posterior intraparietal area, Temporal area TF, Ventral occipitotemporal area, Visual area 2, Visual area 3A, Visual area 4, Visual area 4 (ventral part)

Targets:
Area 23, Area 23c, Area 31, Caudal inferior parietal lobule, Cortical area 45A, Floor of superior temporal sulcus, Frontal eye field, Lateral intraparietal area, Medial superior temporal area (dorsal), Middle temporal area, Nucleus caudatus, Nucleus pulvinaris thalami, Nucleus pulvinaris thalami, pars oralis, Posterior intraparietal area, Temporal area TF, V4 transitional area, Ventral intraparietal area, Visual area 1, Visual area 2, Visual area 4

Descendant targets:
Area 8A, Dorsal prelunate gyrus, Floor of superior temporal sulcus, Frontal eye field, Lateral intraparietal area, Lateral intraparietal area (internal part), Medial superior temporal area (dorsal), Middle temporal area, Nucleus caudatus; genu, Nucleus pulvinaris inferior thalami, Nucleus pulvinaris medialis thalami, Nucleus pulvinaris thalami, Nucleus pulvinaris thalami, pars oralis, Posterior inferotemporal area, Posterior inferotemporal area (dorsal), Posterior inferotemporal area (ventral), Posterior intraparietal area, Temporal area TF, Ventral intraparietal area, Ventral occipitotemporal area, Ventral posterior lateral nucleus (thalamus), Visual area 2, Visual area 3A, Visual area 4, Visual area 4 (ventral part), posterior lateral auditory area

Sub-regions:
Dorsal visual area 3, Ventral visual area 3

Region: Dorsal visual area 3 (V3d)

Super-regions:
Dorsal visual area 3 < Visual area 3 < Extrastriate area OA < Visual anterior cortex < Striate cortex < GM-CerebralCortex < Brain

Sources:
Lateral intraparietal area, Posterior inferotemporal area, Visual area 2

Targets:
Area 8A, Lateral intraparietal area, Nucleus pulvinaris thalami, Posterior inferotemporal area, Visual area 4

Region: Ventral visual area 3 (V3v)

Super-regions:
Ventral visual area 3 < Visual area 3 < Extrastriate area OA < Visual anterior cortex < Striate cortex < GM-CerebralCortex < Brain

Sources:
Lateral intraparietal area, Lateral intraparietal area (internal part), Medial superior temporal area (dorsal), Middle temporal area, Posterior inferotemporal area, Posterior intraparietal

area, Temporal area TF, Ventral occipitotemporal area, Visual area 2, Visual area 3A, Visual area 4, Visual area 4 (ventral part)

Targets:
Area 8A, Dorsal prelunate gyrus, Floor of superior temporal sulcus, Frontal eye field, Lateral intraparietal area, Lateral intraparietal area (internal part), Medial superior temporal area (dorsal), Middle temporal area, Nucleus caudatus; genu, Nucleus pulvinaris inferior thalami, Nucleus pulvinaris medialis thalami, Nucleus pulvinaris thalami, Nucleus pulvinaris thalami, pars oralis, Posterior inferotemporal area, Posterior inferotemporal area (dorsal), Posterior inferotemporal area (ventral), Posterior intraparietal area, Temporal area TF, Ventral intraparietal area, Ventral occipitotemporal area, Ventral posterior lateral nucleus (thalamus), Visual area 2, Visual area 3A, Visual area 4, Visual area 4 (ventral part), posterior lateral auditory area

---
Region: Visual area 4 (V4)

Super-regions:
Visual area 4 < Extrastriate area OA < Visual anterior cortex < Striate cortex < GM-CerebralCortex < Brain

Sources:
Anterior inferotemporal area (ventral), Basolateral nucleus of amygdala, Caudal inferior parietal lobule, Central inferotemporal area (dorsal), Central inferotemporal area (ventral), Cortical area 45, Cortical area 46, Cortical area OAa, Dorsal prelunate gyrus, Dorsal visual area 3, Floor of superior temporal sulcus, Frontal eye field, Inferotemporal area TE, Lateral auditory field, Lateral intraparietal area, Middle temporal area, Nucleus basalis thalami, Nucleus pulvinaris inferior thalami, Nucleus pulvinaris inferior thalami, central subdivision, Nucleus pulvinaris inferior thalami, lateral subdivision, Nucleus pulvinaris inferior thalami, pars posterior, Nucleus pulvinaris lateralis thalami pars ventrolateralis, Nucleus pulvinaris lateralis thalami pars ventromedialis, Nucleus pulvinaris medialis thalami, Nucleus pulvinaris thalami, pars oralis, Posterior inferotemporal area, Posterior inferotemporal area (dorsal), Posterior inferotemporal area (ventral), Posterior intraparietal area, Superior temporal sulcus, Temporal area TF, Temporal area TH, Ventral intraparietal area, Ventral occipitotemporal area, Ventral visual area 3, Visual area 1, Visual area 2, Visual area 3, Visual area 3A, posterior lateral auditory area

Descendant sources:
Floor of superior temporal sulcus, Medial superior temporal area (dorsal), Middle temporal area, Occipitoparietal area, Posterior inferotemporal area, Ventral visual area 3, Visual area 1, Visual area 2, Visual area 3

Targets:
Anterior inferotemporal area (ventral), Area 8A, Caudal inferior parietal lobule, Central amygdaloid nucleus, lateral part, Central inferotemporal area (dorsal), Central inferotemporal area (ventral), Cortical area 45A, Cortical area 46, Dorsal prelunate gyrus, Floor of superior temporal sulcus, Frontal eye field, Lateral intraparietal area, Middle temporal area, Nucleus caudatus, Nucleus caudatus; genu, Nucleus caudatus; tail, Nucleus centralis superior lateralis thalami, Nucleus paracentralis thalami, Nucleus pulvinaris inferior thalami, Nucleus pulvinaris medialis thalami, Nucleus pulvinaris oralis thalami, Nucleus pulvinaris thalami, Posterior inferotemporal area, Posterior inferotemporal area (dorsal), Posterior inferotemporal area (ventral), Posterior intraparietal area, Putamen; caudal, Temporal area TF, Temporal area TF (lateral part), Temporal area TF (medial part), Temporal area TH, Ventral posterior lateral nucleus (thalamus), Ventral visual area 3, Visual area 1, Visual area 2, Visual

area 3, Visual area 3A, posterior lateral auditory area

Descendant targets:
Area 6 (ventral part), Area 8A, Caudal inferior parietal lobule, Cortical area 45A, Floor of superior temporal sulcus, Frontal eye field, Inferior parietal lobule (lateral posterior cortex below the intraparietal sulcus), Lateral intraparietal area, Medial superior temporal area (dorsal), Medial superior temporal area (posterior), Middle temporal area, Nucleus caudatus, Nucleus caudatus; genu, Nucleus centralis superior lateralis thalami, Nucleus paracentralis thalami, Nucleus pulvinaris inferior thalami, Nucleus pulvinaris medialis thalami, Nucleus pulvinaris oralis thalami, Nucleus pulvinaris thalami, pars oralis, Nucleus ventralis lateralis thalami, pars postrema, Posterior inferotemporal area, Posterior inferotemporal area (dorsal), Posterior inferotemporal area (ventral), Putamen; caudal, Ventral visual area 3, Visual area 1, Visual area 3, posterior lateral auditory area

Sub-regions:
V4 transitional area, Visual area 4 (dorsal part), Visual area 4 (ventral part)

Region: V4 transitional area (V4t)

Super-regions:
V4 transitional area < Visual area 4 < Extrastriate area OA < Visual anterior cortex < Striate cortex < GM-CerebralCortex < Brain

Sources:
Floor of superior temporal sulcus, Medial superior temporal area (dorsal), Middle temporal area, Occipitoparietal area, Posterior inferotemporal area, Visual area 2, Visual area 3

Targets:
Area 8A, Cortical area 45A, Floor of superior temporal sulcus, Frontal eye field, Lateral intraparietal area, Medial superior temporal area (dorsal), Medial superior temporal area (posterior), Middle temporal area, Nucleus centralis superior lateralis thalami, Nucleus paracentralis thalami, Nucleus pulvinaris inferior thalami, Nucleus pulvinaris medialis thalami, Nucleus pulvinaris thalami, pars oralis, Posterior inferotemporal area, Posterior inferotemporal area (dorsal), Posterior inferotemporal area (ventral), Visual area 1, Visual area 3, posterior lateral auditory area

---
Region: Visual area 4 (dorsal part) (V4d)

Super-regions:
Visual area 4 (dorsal part) < Visual area 4 < Extrastriate area OA < Visual anterior cortex < Striate cortex < GM-CerebralCortex < Brain

Sources:
Visual area 1, Visual area 2

Descendant sources:
Visual area 2

Targets:
Caudal inferior parietal lobule, Lateral intraparietal area, Medial superior temporal area (dorsal), Middle temporal area, Nucleus caudatus, Nucleus caudatus; genu, Nucleus pulvinaris inferior thalami, Nucleus pulvinaris medialis thalami, Nucleus pulvinaris oralis thalami, Nucleus ventralis lateralis thalami, pars postrema, Posterior inferotemporal area, Posterior inferotemporal area (dorsal), Posterior inferotemporal area (ventral), Putamen; caudal,

```
            Visual area 1,  posterior lateral auditory area

        Descendant targets:
            Area 6 (ventral part)

        Sub-regions:
            dorsolateral visual cortex, caudal part,
            dorsolateral visual cortex, rostral part


          -------------------------------------------------------
          Region: dorsolateral visual cortex, rostral part (DLr)
          -------------------------------------------------------

              Super-regions:
                  dorsolateral visual cortex, rostral part   <
                  Visual area 4 (dorsal part)   <   Visual area
                  4   <   Extrastriate area OA   <   Visual
                  anterior cortex   <   Striate cortex   <
                  GM-CerebralCortex   <   Brain

              Sources:
                  Visual area 2

              Targets:
                  Area 6 (ventral part)


          -------------------------------------------------------
          Region: dorsolateral visual cortex, caudal part (DLc)
          -------------------------------------------------------

              Super-regions:
                  dorsolateral visual cortex, caudal part   <
                  Visual area 4 (dorsal part)   <   Visual area
                  4   <   Extrastriate area OA   <   Visual
                  anterior cortex   <   Striate cortex   <
                  GM-CerebralCortex   <   Brain

              Sources:
                  Visual area 2

              Targets:
                  Area 6 (ventral part)


     ------------------------------------------------------------
     Region: Visual area 4 (ventral part) (V4v)
     ------------------------------------------------------------

        Super-regions:
            Visual area 4 (ventral part)   <   Visual area 4
            <   Extrastriate area OA   <   Visual anterior
            cortex   <   Striate cortex   <   GM-
            CerebralCortex   <   Brain

        Sources:
            Ventral visual area 3

        Targets:
            Inferior parietal lobule (lateral posterior cortex
            below the intraparietal sulcus),  Posterior
            inferotemporal area,  Posterior inferotemporal
            area (dorsal),  Posterior inferotemporal area
            (ventral),  Ventral visual area 3


-----------------------------------------------------------------
Region: Ventral posterior parietal area (VPP)
-----------------------------------------------------------------

   Super-regions:
       Ventral posterior parietal area   <   Extrastriate area
       OA   <   Visual anterior cortex   <   Striate cortex
       <   GM-CerebralCortex   <   Brain

   Sources:
       Visual area 2

   Targets:
       Area 6 (ventral part)


-----------------------------------------------------------------
Region: dorsointermediate visual field (DI#1)
-----------------------------------------------------------------

   Super-regions:
```

dorsointermediate visual field < Extrastriate area OA < Visual anterior cortex < Striate cortex < GM-CerebralCortex < Brain

Sources:
Visual area 2

Targets:
Area 6 (ventral part)

Region: Nucleus pulvinaris thalami, pars oralis (PO#4)

Super-regions:
Nucleus pulvinaris thalami, pars oralis <
Extrastriate area OA < Visual anterior cortex <
Striate cortex < GM-CerebralCortex < Brain

Sources:
Area 7a, Dorsal prelunate gyrus, Frontal eye field, Lateral intraparietal area, Medial intraparietal area, Medial superior temporal area (dorsal), Medial superior temporal area (posterior), Middle temporal area, Parietal area PG, medial part, Posterior intraparietal area, Temporal area TF, V4 transitional area, Ventral intraparietal area, Ventral visual area 3, Visual area 1, Visual area 2, Visual area 3, Visual area 3A

Descendant sources:
Agranular frontal area 2 (= caudal dorsolateral premotor area), Agranular frontal area 5 (= rostral ventrolateral premotor area), Agranular frontal area 6 (= pre-SMA), Agranular frontal area 7 (= rostral dorsolateral premotor area), Area 6 (ventral part), Area 7a, Caudal and medial superior parietal lobule, Claustrum, Cortical area 46, Floor of superior temporal sulcus, Lateral Geniculate Nucleus, Lateral intraparietal area, Medial intraparietal area, Medial superior temporal area, Middle temporal area, Nucleus limitans thalami, Nucleus pulvinaris inferior thalami, central subdivision, Nucleus pulvinaris inferior thalami, lateral subdivision, Nucleus pulvinaris inferior thalami, pars medialis, Parietal area PE (cingulate part), Parietal area PG, medial part, Rostral superior parietal lobule, Ventral intraparietal area, Ventral posterior parietal area, Visual area 1, Visual area 2, Visual area V6A, dorsointermediate visual field, dorsolateral visual cortex, caudal part, dorsolateral visual cortex, rostral part, posterior lateral auditory area

Targets:
Agranular frontal area 2 (= caudal dorsolateral premotor area), Agranular frontal area 7 (= rostral dorsolateral premotor area), Area 32, Area 6, Area 7a, Area 8A, Caudal inferior parietal lobule, Cortical area 45A, Dorsal prelunate gyrus, Lateral intraparietal area, Medial superior temporal area (dorsal), Medial superior temporal area (posterior), Middle temporal area, Parietal area PG, medial part, Premotor area 6 (dorsal part), Visual area 1, Visual area 4

Descendant targets:
Agranular frontal area 2 (= caudal dorsolateral premotor area), Agranular frontal area 3 (= SMA-proper), Agranular frontal area 5 (= rostral ventrolateral premotor area), Agranular frontal area 6 (= pre-SMA), Agranular frontal area 7 (= rostral dorsolateral premotor area), Anterior intraparietal area, Area 6 (ventral part), Area 7a, Caudal and medial superior parietal lobule, Cortical area 46, Dorsal prelunate gyrus, Frontal eye field, Lateral intraparietal area, Medial intraparietal area, Middle temporal area, Nucleus pulvinaris inferior thalami, Nucleus pulvinaris inferior thalami, central subdivision, Nucleus pulvinaris inferior thalami, lateral subdivision, Nucleus pulvinaris medialis thalami, Nucleus pulvinaris thalami, Parietal area PE (cingulate part), Parietal area PG, medial part, Primary motor area, Ventral intraparietal area, Ventral posterior lateral nucleus (thalamus), Visual area 1, Visual area 2, Visual area 3, Visual area 3A, Visual area V6A, posterior lateral auditory area

Sub-regions:
Area 6 (ventral part), Visual area V6A

Region: Visual area V6A (V6A)

Super-regions:
Visual area V6A < Nucleus pulvinaris thalami, pars oralis < Extrastriate area OA < Visual anterior cortex < Striate cortex < GM-CerebralCortex < Brain

Sources:
Agranular frontal area 2 (= caudal dorsolateral premotor area), Agranular frontal area 5 (= rostral ventrolateral premotor area), Agranular frontal area 6 (= pre-SMA), Agranular frontal area 7 (= rostral dorsolateral premotor area), Area 6 (ventral part), Area 7a, Caudal and medial superior parietal lobule, Cortical area 46, Lateral intraparietal area, Medial intraparietal area, Parietal area PE (cingulate part), Parietal area PG, medial part, Rostral superior parietal lobule, Ventral intraparietal area

Targets:
Agranular frontal area 2 (= caudal dorsolateral premotor area), Agranular frontal area 3 (= SMA-proper), Agranular frontal area 5 (= rostral ventrolateral premotor area), Agranular frontal area 6 (= pre-SMA), Agranular frontal area 7 (= rostral dorsolateral premotor area), Anterior intraparietal area, Area 6 (ventral part), Area 7a, Caudal and medial superior parietal lobule, Cortical area 46, Dorsal prelunate gyrus, Lateral intraparietal area, Medial intraparietal area, Middle temporal area, Parietal area PE (cingulate part), Parietal area PG, medial part, Primary motor area, Ventral intraparietal area, Visual area 3

Region: Area 6 (ventral part) (V6)

Super-regions:
Area 6 (ventral part) < Nucleus pulvinaris thalami, pars oralis < Extrastriate area OA < Visual anterior cortex < Striate cortex < GM-CerebralCortex < Brain

Sources:
Claustrum, Floor of superior temporal sulcus, Lateral Geniculate Nucleus, Medial superior temporal area, Middle temporal area, Nucleus limitans thalami, Nucleus pulvinaris inferior thalami, central subdivision, Nucleus pulvinaris inferior thalami, lateral subdivision, Nucleus pulvinaris inferior thalami, pars medialis, Ventral posterior parietal area, Visual area 1, Visual area 2, Visual area V6A, dorsointermediate visual field, dorsolateral visual cortex, caudal part, dorsolateral visual cortex, rostral part, posterior lateral auditory area

Targets:
Agranular frontal area 3 (= SMA-proper), Agranular frontal area 5 (= rostral ventrolateral premotor area), Agranular frontal area 7 (= rostral dorsolateral premotor area), Area 7a, Caudal and medial superior parietal lobule, Dorsal prelunate gyrus, Frontal eye field, Lateral intraparietal area, Medial intraparietal area, Middle temporal area, Nucleus pulvinaris inferior thalami, Nucleus pulvinaris inferior thalami, central subdivision, Nucleus pulvinaris inferior thalami, lateral subdivision, Nucleus pulvinaris medialis thalami, Nucleus pulvinaris thalami, Parietal area PG, medial part, Ventral intraparietal area, Ventral posterior lateral nucleus (thalamus), Visual area 1, Visual area 2, Visual area 3, Visual area 3A, Visual area V6A, posterior lateral auditory area

---
Region: Dorsal prelunate gyrus (DP)

Super-regions:
Dorsal prelunate gyrus < Extrastriate area OA < Visual anterior cortex < Striate cortex < GM-CerebralCortex < Brain

Sources:
Area 6 (ventral part), Area 7a, Cortical area 46, Frontal eye field, Inferotemporal area TE, Lateral intraparietal area, Medial superior temporal area (dorsal), Nucleus pulvinaris thalami, pars oralis, Posterior inferotemporal area, Posterior intraparietal area, Ventral visual area 3, Visual area 3A, Visual area 4, Visual area V6A

Targets:
Area 7a, Caudal inferior parietal lobule, Central amygdaloid nucleus, lateral part, Cortical area 46, Floor of superior temporal sulcus, Lateral intraparietal area, Laterodorsal nucleus (thalamus), Medial superior temporal area (dorsal), Medial superior temporal area (posterior), Middle temporal area, Nucleus centralis superior lateralis thalami, Nucleus paracentralis thalami, Nucleus pulvinaris inferior thalami, Nucleus pulvinaris medialis thalami, Nucleus pulvinaris oralis thalami, Nucleus pulvinaris thalami, pars oralis, Posterior inferotemporal area, Posterior intraparietal area, Ventral posterior lateral nucleus (thalamus), Visual area 3A, Visual area 4, posterior lateral auditory area

---
Region: Ventral occipitotemporal area (VOT)

Super-regions:
Ventral occipitotemporal area < Visual anterior cortex < Striate cortex < GM-CerebralCortex < Brain

Sources:
Ventral visual area 3, Visual area 2

Targets:
Posterior inferotemporal area (dorsal), Posterior inferotemporal area (ventral), Ventral visual area 3, Visual area 2, Visual area 4

Region: Visual area 1 (V1)

Super-regions:
Visual area 1 < Striate cortex < GM-CerebralCortex < Brain

Sources:
Area 6 (ventral part), Basolateral nucleus of amygdala, Claustrum, Cortical area PGa, Cortical area TEm, Inferotemporal area TE, Intralaminar nuclei of the thalamus, Intraparietal sulcus associated area in the superior temporal sulcus, Lateral Geniculate Nucleus, Lateral intraparietal area, Medial basal nucleus of the amygdala, Middle temporal area, Nucleus pulvinaris inferior thalami, Nucleus pulvinaris inferior thalami, lateral subdivision, Nucleus pulvinaris inferior thalami, shell of the lateral subdivision, Nucleus pulvinaris lateralis thalami pars alpha, Nucleus pulvinaris lateralis thalami pars ventrolateralis, Nucleus pulvinaris lateralis thalami pars ventromedialis, Nucleus pulvinaris thalami, Nucleus pulvinaris thalami, pars oralis, Posterior inferotemporal area, Posterior intraparietal area, Temporal area TF, Temporal area TH, V4 transitional area, Visual area 2, Visual area 3, Visual area 3A, Visual area 4, Visual area 4 (dorsal part), posterior lateral auditory area

Targets:
Area 6 (ventral part), Cortical area OAa, Medial superior temporal area (posterior), Middle temporal area, Nucleus pulvinaris inferior thalami, central subdivision, Nucleus pulvinaris inferior thalami, lateral subdivision, Nucleus pulvinaris inferior thalami, pars medialis, Nucleus pulvinaris inferior thalami, shell of the lateral subdivision, Nucleus

pulvinaris thalami, Nucleus pulvinaris thalami, pars oralis, Posterior intraparietal area, Visual area 2, Visual area 3, Visual area 3A, Visual area 4, Visual area 4 (dorsal part)

Region: Prostriate cortex (ProSt)

Super-regions:
Prostriate cortex < Striate cortex < GM-CerebralCortex < Brain

Sources:
Visual area 2

Targets:
Area 24c (rostral part of the cingulate sulcus), Temporal area TF

Region: Visual area 2 (V2)

Super-regions:
Visual area 2 < Striate cortex < GM-CerebralCortex < Brain

Sources:
Area 6 (ventral part), Basolateral nucleus of amygdala, Cortical area TEm, Extrastriate area OA, Inferotemporal area TE, Lateral Geniculate Nucleus, Lateral intraparietal area, Medial superior temporal area (dorsal), Medial superior temporal area (posterior), Middle temporal area, Nucleus pulvinaris inferior thalami, Nucleus pulvinaris inferior thalami, central subdivision, Nucleus pulvinaris inferior thalami, lateral subdivision, Nucleus pulvinaris inferior thalami, pars medialis, Nucleus pulvinaris lateralis thalami pars ventrolateralis, Nucleus pulvinaris lateralis thalami pars ventromedialis, Nucleus pulvinaris thalami, Parietal area PG, medial part, Posterior inferotemporal area, Temporal area TF, Ventral occipitotemporal area, Ventral visual area 3, Visual area 1, Visual area 3, Visual area 3A, Visual area 4, posterior lateral auditory area

Targets:
Area 10, Area 23, Area 32, Area 6 (ventral part), Area 8, Area 8A, Caudal inferior parietal lobule, Cortical area 45A, Dorsal visual area 3, Extrastriate area OA, Floor of superior temporal sulcus, Frontal eye field, Inferotemporal area TE, Lateral Geniculate Nucleus, Lateral intraparietal area, Lateral intraparietal area (internal part), Laterodorsal nucleus (thalamus), Medial basal nucleus of the amygdala, Medial superior temporal area, Medial superior temporal area (dorsal), Medial superior temporal area (posterior), Middle temporal area, Nucleus caudatus, Nucleus caudatus; genu, Nucleus caudatus; tail, Nucleus paracentralis thalami, Nucleus pulvinaris inferior thalami, Nucleus pulvinaris oralis thalami, Nucleus pulvinaris thalami, Nucleus pulvinaris thalami, pars oralis, Nucleus reticularis thalami, Parietal area PG, medial part, Peripheral part of area MT, Posterior inferotemporal area, Posterior inferotemporal area (dorsal), Posterior inferotemporal area (ventral), Posterior intraparietal area, Prostriate cortex, Putamen; caudal, Temporal area TF, V4 transitional area, Ventral intraparietal area, Ventral occipitotemporal area, Ventral posterior lateral nucleus (thalamus), Ventral posterior parietal area, Ventral visual area 3, Visual area 1, Visual area 3, Visual area 3A, Visual area 4, Visual area 4 (dorsal part), dorsointermediate visual field, dorsolateral visual cortex, caudal part, dorsolateral visual cortex, rostral part, posterior lateral auditory area

---
Region: Basal Ganglia according to GM-Definition (BG)

Super-regions:
Basal Ganglia according to GM-Definition < Brain

Descendant sources:
Accessor basal nucleus (amygdala), ventromedial division, Accessory basal amygdaloid nucleus, dorsal division, Accessory basal amygdaloid nucleus, parvicellular part, Accessory basal amygdaloid nucleus, ventral division, Agranular frontal area 7 (= rostral dorsolateral premotor area), Agranular insula, Anterior inferotemporal area (dorsal), Anterior inferotemporal area (ventral), Area 10, Area 11, Area 12, Area 20, Area 21, Area 23,

Area 24b, Area 24c (rostral part of the cingulate sulcus), Area 25, Area 32, Area 35, Area 36, Area 6, Area 7, Area 8, Area 9, Basal amygdaloid nucleus, intermediate part, Basal amygdaloid nucleus, ventral lateral division, Basolateral nucleus of amygdala, CA1 subfield of Ammon`s horn, Caudal and medial superior parietal lobule, Caudal inferior parietal lobule, Caudal part of area 36, Central inferotemporal area, Claustrum, Cortical area 36p, Cortical area 45, Cortical area 46, Dysgranular insular cortex, Entorhinal cortex, Extrastriate area OA, Fascia dentata hippocampi, Floor of superior temporal sulcus, Frontal eye field, Granular insular cortex, Hypothalamus, Inferior parietal lobule (lateral posterior cortex below the intraparietal sulcus), Inferotemporal area TE, Insula, Intermediate agranula insular cortex, LGN external magnocellular layer, Lateral agranular insular cortex, Lateral area 11, Lateral area 12, Lateral auditory field, Lateral intraparietal area, Lateral nucleus (amygdala), dorsal intermediate division, Lateral nucleus (amygdala), ventral division, Medial agranular insular cortex, Medial area 10, Medial area 11, Medial area 12, Medial basal nucleus of the amygdala, Medial basal nucleus of the amygdala, Medial intraparietal area, Medial superior temporal area, Middle temporal area, Midline nuclei of the thalamus, Midpart of the inferior parietal lobule, Nucleus basalis thalami, Nucleus caudatus; genu, Nucleus caudatus; tail, Nucleus centralis densocellularis thalami, Nucleus centralis inferior thalami, Nucleus paraventricularis thalami, pars anterior, Nucleus pulvinaris thalami, Nucleus reuniens thalami, Orbital area 10, Orbital area 12, Orbitofrontal area 13, Orbitofrontal area 13, lateral part, Orbitofrontal area 13, medial part, Orbitofrontal area 13a, Orbitofrontal area 14, Parahippocampal cortex, Parietal area PE (cingulate part), Parietal area PG, medial part, Piriform cortex, Posterior inferotemporal area, Posteromedial agranular insular cortex, Precentral opercular area, Premotor area 6 (dorsal part), Premotor area 6Va, Premotor area 6Vb, Primary sensory cortex, Putamen; caudal, Rostral area 12, Rostral area 14, Rostral inferior parietal lobule, Rostral parietal operculum, Rostral part of area 36, Rostral superior parietal lobule, Superior temporal sulcus, Superior temporal sulcus, dorsal, Temporal area TA, Temporal area TF, Temporal area TH, Temporal proisocortex, Temporopolar area TG, Ventral visual area 3, Visual area 2, Visual area 3, Visual area 4, Visual area 4 (dorsal part), accessory basal nucleus (amygdala), magnocellular subdivision, area 24, central nucleus of the amygdala, cortical nucleus (amygdala), lateral nucleus (amygdala), ventrolateral subdivision, periamygdaloid cortex, prosubiculum, substantia nigra, superior temporal gyrus, temporal visual association area in the lower bank of the superior temporal sulcus

Descendant targets:

Accessor basal nucleus (amygdala), ventromedial division, Accessory basal amygdaloid nucleus, dorsal division, Accessory basal amygdaloid nucleus, parvicellular part, Accessory basal amygdaloid nucleus, ventral division, Agranular frontal area 7 (= rostral dorsolateral premotor area), Agranular insula, Amygdala, Anterior inferotemporal area (dorsal), Anterior inferotemporal area (ventral), Anterior medial nucleus, Area 10, Area 11, Area 12, Area 20, Area 21, Area 25, Area 32, Area 35, Area 36, Area 6, Area 6 (ventral part), Area 7, Area 8, Area 8B, Area 9, Basal amygdaloid nucleus, intermediate part, Basal amygdaloid nucleus, ventral lateral division, Basolateral nucleus of amygdala, CA1 subfield of Ammon`s horn, CA3 subfield of Ammons horn, Caudal inferior parietal lobule, Caudal part of area 36, Central inferotemporal area, Cingulate motor areas, Cortical area 45, Cortical area 46, Dysgranular insular cortex, Entorhinal cortex, Entorhinal cortex, Extrastriate area OA, Fascia dentata hippocampi, Frontal eye field, Globus pallidus external part, Granular insular cortex, Gustatory cortex, Hippocampus, Hypothalamus, Inferotemporal area TE, Insula, Intermediate agranula insular cortex, Intermediate field of entorhinal cortex, LGN external magnocellular layer, Lateral area 12, Lateral auditory field, Lateral field (caudal part) of entorhinal cortex, Lateral field (rostral part) of entorhinal cortex, Lateral field of entorhinal cortex, Lateral nucleus (amygdala), dorsal division, Lateral nucleus (amygdala), dorsal intermediate division, Lateral nucleus (amygdala), ventral division, Laterodorsal nucleus (thalamus), Medial area 11, Medial basal nucleus of the amygdala, Medial superior temporal area, Middle temporal area, Nucleus basalis thalami, Nucleus caudatus; genu, Nucleus centralis densocellularis thalami, Nucleus centralis inferior thalami, Nucleus centralis intermedialis thalami, Nucleus limitans thalami, Nucleus medialis dorsalis thalami, Nucleus medialis dorsalis thalami, pars fibrosa, Nucleus medialis dorsalis thalami, pars magnocellularis, Nucleus medialis dorsalis thalami, pars paramediana, Nucleus of the lateral olfactory tract, Nucleus parataenialis thalami, Nucleus paraventricularis thalami, pars anterior, Nucleus peripeduncularis thalami, Nucleus pulvinaris inferior thalami, Nucleus pulvinaris medialis thalami, Nucleus reuniens thalami, Olfactory Complex, Orbital area 12, Orbitofrontal area 13, Orbitofrontal area 13a, Orbitofrontal area 14, Periamygdaloid cortex 2, Posterior inferotemporal area, Posteromedial agranular insular cortex, Premotor area 6 (dorsal part), Primary motor area, Primary somatosensory cortex, Rostral area 14, Rostral inferior parietal lobule, Rostral part of area 36, Secondary somatosensory cortex, Temporal area TA, Temporal area TF, Temporal area TH, Temporal proisocortex, Temporopolar area TG, Ventral area 46, Visual area 1, Visual area 2, Visual area 4, accessory basal nucleus (amygdala), magnocellular subdivision, amygdalohippocampal area, anterior amygdaloid area, area 24, central nucleus of the

amygdala, cortical nucleus (amygdala), cortical nucleus, anterior division, cortical nucleus, posterior division, lateral nucleus (amygdala), ventrolateral subdivision, medial entorhinal cortex, periamygdaloid cortex, prosubiculum, substantia nigra, superior parietal lobule (posterior dorsomedial parietal cortex above the intraparietal sulcus), temporal visual association area in the lower bank of the superior temporal sulcus, ventral striatal shell

Sub-regions:
Amygdala, Claustrum, Globus pallidus external part, Nucleus subthalamicus, Primary sensory cortex, striatum, substantia nigra

---

Region: Amygdala (Amyg)

Super-regions:
Amygdala < Basal Ganglia according to GM-Definition < Brain

Sources:
Hypothalamus, Insula, Primary sensory cortex

Descendant sources:
Accessor basal nucleus (amygdala), ventromedial division, Accessory basal amygdaloid nucleus, dorsal division, Accessory basal amygdaloid nucleus, parvicellular part, Accessory basal amygdaloid nucleus, ventral division, Agranular insula, Anterior inferotemporal area (dorsal), Anterior inferotemporal area (ventral), Area 10, Area 11, Area 12, Area 20, Area 21, Area 25, Area 32, Area 35, Area 36, Area 6, Area 8, Area 9, Basal amygdaloid nucleus, intermediate part, Basal amygdaloid nucleus, ventral lateral division, Basolateral nucleus of amygdala, CA1 subfield of Ammon`s horn, Caudal part of area 36, Central inferotemporal area, Claustrum, Cortical area 36p, Cortical area 45, Cortical area 46, Dysgranular insular cortex, Entorhinal cortex, Granular insular cortex, Inferotemporal area TE, Intermediate agranula insular cortex, LGN external magnocellular layer, Lateral area 12, Lateral auditory field, Lateral nucleus (amygdala), dorsal intermediate division, Lateral nucleus (amygdala), ventral division, Medial agranular insular cortex, Medial area 11, Medial basal nucleus of the amygdala, Medial basal nucleus of the amygdala, Midline nuclei of the thalamus, Nucleus basalis thalami, Nucleus centralis densocellularis thalami, Nucleus centralis inferior thalami, Nucleus paraventricularis thalami, pars anterior, Nucleus pulvinaris thalami, Nucleus reuniens thalami, Orbitofrontal area 13, Orbitofrontal area 13a, Orbitofrontal area 14, Parahippocampal cortex, Piriform cortex, Posterior inferotemporal area, Rostral part of area 36, Superior temporal sulcus, dorsal, Temporal area TF, Temporal area TH, Temporal proisocortex, Temporopolar area TG, accessory basal nucleus (amygdala), magnocellular subdivision, area 24, central nucleus of the amygdala, cortical nucleus (amygdala), lateral nucleus (amygdala), ventrolateral subdivision, periamygdaloid cortex, prosubiculum, substantia nigra, superior temporal gyrus, temporal visual association area in the lower bank of the superior temporal sulcus

Targets:
Anterior medial nucleus, Area 11, Area 25, Area 6, Area 8B, Area 9, Laterodorsal nucleus (thalamus), Nucleus centralis densocellularis thalami, Nucleus centralis inferior thalami, Nucleus centralis intermedialis thalami, Nucleus limitans thalami, Nucleus medialis dorsalis thalami, Nucleus medialis dorsalis thalami, pars magnocellularis, Nucleus parataenialis thalami, Nucleus paraventricularis thalami, pars anterior, Nucleus pulvinaris medialis thalami, Nucleus reuniens thalami, Orbitofrontal area 13, Orbitofrontal area 14, area 24

Descendant targets:
Accessor basal nucleus (amygdala), ventromedial division, Accessory basal amygdaloid nucleus, dorsal division, Accessory basal amygdaloid nucleus, parvicellular part, Accessory basal amygdaloid nucleus, ventral division, Agranular insula, Anterior inferotemporal area (dorsal), Anterior inferotemporal area (ventral), Area 10, Area 11, Area 12, Area 20, Area 21, Area 25, Area 32, Area 35, Area 36, Area 6, Area 8, Area 9, Basal amygdaloid nucleus, intermediate part, Basal amygdaloid nucleus, ventral lateral division, Basolateral nucleus of amygdala, CA1 subfield of Ammon`s horn, CA3 subfield of Ammons horn, Caudal part of area 36, Central inferotemporal area, Cingulate motor areas, Cortical area 46, Dysgranular insular cortex, Entorhinal cortex, Fascia dentata hippocampi, Gustatory cortex, Hippocampus, Inferotemporal area TE, Insula, Intermediate agranula insular cortex, Intermediate field of entorhinal cortex, LGN external magnocellular layer, Lateral area 12, Lateral auditory field, Lateral field (caudal part) of entorhinal cortex, Lateral field (rostral part) of entorhinal cortex, Lateral field of entorhinal cortex, Lateral nucleus (amygdala), dorsal division, Lateral nucleus (amygdala), dorsal intermediate

division, Lateral nucleus (amygdala), ventral division, Medial area 11, Medial basal nucleus of the amygdala, Medial superior temporal area, Middle temporal area, Nucleus basalis thalami, Nucleus medialis dorsalis thalami, Nucleus medialis dorsalis thalami, pars fibrosa, Nucleus medialis dorsalis thalami, pars magnocellularis, Nucleus medialis dorsalis thalami, pars paramediana, Nucleus of the lateral olfactory tract, Nucleus peripeduncularis thalami, Nucleus pulvinaris inferior thalami, Orbital area 12, Orbitofrontal area 13, Orbitofrontal area 13a, Orbitofrontal area 14, Periamygdaloid cortex 2, Posterior inferotemporal area, Posteromedial agranular insular cortex, Rostral area 14, Rostral part of area 36, Temporal area TA, Temporal area TF, Temporal area TH, Temporal proisocortex, Temporopolar area TG, Ventral area 46, Visual area 1, Visual area 2, Visual area 4, accessory basal nucleus (amygdala), magnocellular subdivision, amygdalohippocampal area, anterior amygdaloid area, area 24, central nucleus of the amygdala, cortical nucleus (amygdala), cortical nucleus, anterior division, cortical nucleus, posterior division, lateral nucleus (amygdala), ventrolateral subdivision, medial entorhinal cortex, periamygdaloid cortex, prosubiculum, temporal visual association area in the lower bank of the superior temporal sulcus, ventral striatal shell

Sub-regions:
LGN external magnocellular layer, Lateral auditory field, Nucleus basalis thalami, Nucleus pulvinaris inferior thalami, anterior amygdaloid area, central nucleus of the amygdala, periamygdaloid cortex

---
Region: Nucleus basalis thalami (B#2)

Super-regions:
Nucleus basalis thalami < Amygdala < Basal Ganglia according to GM-Definition < Brain

Sources:
Anterior inferotemporal area (dorsal), Anterior inferotemporal area (ventral), Area 21, Area 35, Area 8, CA1 subfield of Ammon`s horn, Caudal part of area 36, LGN external magnocellular layer, Lateral auditory field, Medial area 11, Rostral part of area 36, Temporal area TF, Temporal area TH, Temporal proisocortex, Temporopolar area TG, central nucleus of the amygdala, cortical nucleus (amygdala), temporal visual association area in the lower bank of the superior temporal sulcus

Descendant sources:
Accessor basal nucleus (amygdala), ventromedial division, Accessory basal amygdaloid nucleus, dorsal division, Accessory basal amygdaloid nucleus, parvicellular part, Accessory basal amygdaloid nucleus, ventral division, Agranular insula, Anterior inferotemporal area (dorsal), Anterior inferotemporal area (ventral), Area 20, Area 21, Area 25, Area 35, Area 36, Basal amygdaloid nucleus, intermediate part, Basal amygdaloid nucleus, ventral lateral division, Basolateral nucleus of amygdala, CA1 subfield of Ammon`s horn, Caudal part of area 36, Central inferotemporal area, Cortical area 36p, Entorhinal cortex, Inferotemporal area TE, Intermediate agranula insular cortex, Lateral area 12, Lateral auditory field, Lateral nucleus (amygdala), dorsal intermediate division, Lateral nucleus (amygdala), ventral division, Medial agranular insular cortex, Orbitofrontal area 13, Orbitofrontal area 13a, Posterior inferotemporal area, Rostral part of area 36, Temporal area TF, Temporal area TH, Temporopolar area TG, accessory basal nucleus (amygdala), magnocellular subdivision, area 24, lateral nucleus (amygdala), ventrolateral subdivision, periamygdaloid cortex, prosubiculum, temporal visual association area in the lower bank of the superior temporal sulcus

Targets:
Agranular insula, Anterior inferotemporal area (dorsal), Area 10, Area 11, Area 12, Area 21, Area 25, Area 32, Area 35, Area 36, Area 9, CA1 subfield of Ammon`s horn, CA3 subfield of Ammons horn, Caudal part of area 36, Entorhinal cortex, Hippocampus, Inferotemporal area TE, Intermediate agranula insular cortex, Intermediate field of entorhinal cortex, LGN external magnocellular layer, Lateral area 12, Lateral auditory field, Lateral field of entorhinal cortex, Nucleus medialis dorsalis thalami, Nucleus medialis dorsalis thalami, pars fibrosa, Nucleus medialis dorsalis thalami, pars magnocellularis, Nucleus medialis dorsalis thalami, pars paramediana, Nucleus peripeduncularis thalami, Orbital area 12, Orbitofrontal area 13, Orbitofrontal area 13a, Orbitofrontal area 14, Posterior inferotemporal area, Rostral part of area 36, Temporal area TF, Temporal area TH, Temporal proisocortex,

Temporopolar area TG, Visual area 4, amygdalohippocampal area, area 24, central nucleus of the amygdala, cortical nucleus, posterior division, medial entorhinal cortex, periamygdaloid cortex, temporal visual association area in the lower bank of the superior temporal sulcus, ventral striatal shell

Descendant targets:
Accessor basal nucleus (amygdala), ventromedial division, Accessory basal amygdaloid nucleus, dorsal division, Accessory basal amygdaloid nucleus, parvicellular part, Accessory basal amygdaloid nucleus, ventral division, Anterior inferotemporal area (dorsal), Anterior inferotemporal area (ventral), Area 11, Area 12, Area 20, Area 21, Area 25, Area 32, Area 35, Area 6, Area 8, Area 9, Basal amygdaloid nucleus, intermediate part, Basal amygdaloid nucleus, ventral lateral division, Basolateral nucleus of amygdala, CA1 subfield of Ammon`s horn, CA3 subfield of Ammons horn, Caudal part of area 36, Central inferotemporal area, Cingulate motor areas, Cortical area 46, Entorhinal cortex, Fascia dentata hippocampi, Hippocampus, Inferotemporal area TE, Intermediate agranula insular cortex, LGN external magnocellular layer, Lateral auditory field, Lateral nucleus (amygdala), dorsal division, Lateral nucleus (amygdala), dorsal intermediate division, Lateral nucleus (amygdala), ventral division, Medial area 11, Medial basal nucleus of the amygdala, Medial superior temporal area, Middle temporal area, Nucleus medialis dorsalis thalami, Nucleus medialis dorsalis thalami, pars magnocellularis, Nucleus of the lateral olfactory tract, Nucleus peripeduncularis thalami, Nucleus pulvinaris inferior thalami, Orbital area 12, Orbitofrontal area 13, Orbitofrontal area 13a, Orbitofrontal area 14, Periamygdaloid cortex 2, Posterior inferotemporal area, Posteromedial agranular insular cortex, Rostral area 14, Rostral part of area 36, Temporal area TF, Temporal area TH, Temporal proisocortex, Temporopolar area TG, Ventral area 46, Visual area 1, Visual area 2, Visual area 4, accessory basal nucleus (amygdala), magnocellular subdivision, amygdalohippocampal area, anterior amygdaloid area, area 24, central nucleus of the amygdala, cortical nucleus (amygdala), cortical nucleus, anterior division, cortical nucleus, posterior division, lateral nucleus (amygdala), ventrolateral subdivision, medial entorhinal cortex, periamygdaloid cortex, prosubiculum, temporal visual association area in the lower bank of the superior temporal sulcus, ventral striatal shell

Sub-regions:
Accessor basal nucleus (amygdala), ventromedial division, Accessory basal amygdaloid nucleus, dorsal division, Accessory basal amygdaloid nucleus, parvicellular part, Accessory basal amygdaloid nucleus, ventral division, Basal amygdaloid nucleus, intermediate part, Basal amygdaloid nucleus, ventral lateral division, Basolateral nucleus of amygdala, Medial basal nucleus of the amygdala, accessory basal nucleus (amygdala), magnocellular subdivision

---
Region: Basolateral nucleus of amygdala (Bla)

Super-regions:
Basolateral nucleus of amygdala < Nucleus basalis thalami < Amygdala < Basal Ganglia according to GM-Definition < Brain

Sources:
Accessory basal amygdaloid nucleus, parvicellular part, Anterior inferotemporal area (dorsal), Anterior inferotemporal area (ventral), Area 20, Area 21, Central inferotemporal area, Inferotemporal area TE, Lateral auditory field, Posterior inferotemporal area, Temporopolar area TG, accessory basal nucleus (amygdala), magnocellular subdivision, area 24, temporal visual association area in the lower bank of the superior temporal sulcus

Targets:
Accessory basal amygdaloid nucleus, parvicellular part, Anterior inferotemporal area (dorsal), Anterior inferotemporal area (ventral), Area 11, Area 20, Area 21, Area 25, Area 32, Area 35, Area 6, Area 8, Area 9, Central inferotemporal area, Cortical area 46, Entorhinal cortex, Inferotemporal area TE, LGN external magnocellular layer, Lateral auditory field, Medial basal nucleus of the amygdala, Medial superior temporal area, Middle temporal area, Nucleus medialis dorsalis thalami, pars magnocellularis, Orbital area 12, Orbitofrontal area 13, Orbitofrontal area 14, Periamygdaloid cortex 2, Posterior inferotemporal area, Temporal proisocortex, Temporopolar

area TG, Ventral area 46, Visual area 1, Visual area 2, Visual area 4, accessory basal nucleus (amygdala), magnocellular subdivision, amygdalohippocampal area, anterior amygdaloid area, area 24, central nucleus of the amygdala, cortical nucleus (amygdala), temporal visual association area in the lower bank of the superior temporal sulcus

---

Region: Accessory basal amygdaloid nucleus, parvicellular part (Abpc)

Super-regions:

Accessory basal amygdaloid nucleus, parvicellular part < Nucleus basalis thalami < Amygdala < Basal Ganglia according to GM-Definition < Brain

Sources:

Accessor basal nucleus (amygdala), ventromedial division, Accessory basal amygdaloid nucleus, dorsal division, Accessory basal amygdaloid nucleus, ventral division, Area 36, Basal amygdaloid nucleus, intermediate part, Basal amygdaloid nucleus, ventral lateral division, Basolateral nucleus of amygdala, Lateral area 12, Lateral auditory field, Lateral nucleus (amygdala), dorsal intermediate division, Lateral nucleus (amygdala), ventral division, Rostral part of area 36, Temporal area TF, Temporal area TH, accessory basal nucleus (amygdala), magnocellular subdivision, lateral nucleus (amygdala), ventrolateral subdivision, periamygdaloid cortex

Targets:

Area 12, Area 35, Area 6, Basal amygdaloid nucleus, intermediate part, Basolateral nucleus of amygdala, Caudal part of area 36, Entorhinal cortex, Fascia dentata hippocampi, Intermediate agranula insular cortex, LGN external magnocellular layer, Lateral auditory field, Medial basal nucleus of the amygdala, Nucleus medialis dorsalis thalami, Nucleus medialis dorsalis thalami, pars magnocellularis, Orbital area 12, Orbitofrontal area 13, Orbitofrontal area 13a, Orbitofrontal area 14, Periamygdaloid cortex 2, Posteromedial agranular insular cortex, Rostral area 14, Rostral part of area 36, Temporal area TF, Temporal area TH, accessory basal nucleus (amygdala), magnocellular subdivision, amygdalohippocampal area, central nucleus of the amygdala, cortical nucleus (amygdala)

Region: Basal amygdaloid nucleus, intermediate part (Bi)

Super-regions:

Basal amygdaloid nucleus, intermediate part < Nucleus basalis thalami < Amygdala < Basal Ganglia according to GM-Definition < Brain

Sources:

Accessor basal nucleus (amygdala), ventromedial division, Accessory basal amygdaloid nucleus, dorsal division, Accessory basal amygdaloid nucleus, parvicellular part, Accessory basal amygdaloid nucleus, ventral division, Agranular insula, Area 25, Area 35, Area 36, Basal amygdaloid nucleus, ventral lateral division, Caudal part of area 36, Cortical area 36p, Entorhinal cortex, Inferotemporal area TE, Intermediate agranula insular cortex, Lateral auditory field, Lateral nucleus (amygdala), dorsal intermediate division, Lateral nucleus (amygdala), ventral division, Medial agranular insular cortex, Orbitofrontal area 13, Orbitofrontal area 13a, Rostral part of area 36, Temporal area TF, lateral nucleus (amygdala), ventrolateral subdivision

Targets:

Accessory basal amygdaloid nucleus, dorsal division, Accessory basal amygdaloid nucleus, parvicellular part, Accessory basal amygdaloid nucleus, ventral division, Area 12, Basal amygdaloid nucleus, ventral lateral division, Caudal part of area 36, Fascia dentata hippocampi, Intermediate agranula insular cortex, Lateral nucleus (amygdala), dorsal intermediate division, Medial area 11, Orbital area 12, Orbitofrontal area 13, Orbitofrontal area 13a, Orbitofrontal area 14, Posteromedial agranular insular cortex, Rostral area 14, Rostral part of area 36, Temporal area TF, anterior amygdaloid area, central nucleus of the amygdala

---
Region: Accessory basal amygdaloid nucleus, dorsal division (ABd)

Super-regions:
Accessory basal amygdaloid nucleus, dorsal division < Nucleus basalis thalami < Amygdala < Basal Ganglia according to GM-Definition < Brain

Sources:
Accessor basal nucleus (amygdala), ventromedial division, Accessory basal amygdaloid nucleus, ventral division, Basal amygdaloid nucleus, intermediate part, Basal amygdaloid nucleus, ventral lateral division

Targets:
Accessor basal nucleus (amygdala), ventromedial division, Accessory basal amygdaloid nucleus, parvicellular part, Accessory basal amygdaloid nucleus, ventral division, Basal amygdaloid nucleus, intermediate part, Basal amygdaloid nucleus, ventral lateral division, CA1 subfield of Ammon`s horn, CA3 subfield of Ammons horn, LGN external magnocellular layer, Lateral nucleus (amygdala), dorsal division, Lateral nucleus (amygdala), dorsal intermediate division, Nucleus of the lateral olfactory tract, Nucleus pulvinaris inferior thalami, Periamygdaloid cortex 2, anterior amygdaloid area, central nucleus of the amygdala, cortical nucleus, anterior division, cortical nucleus, posterior division, lateral nucleus (amygdala), ventrolateral subdivision, ventral striatal shell

---
Region: Basal amygdaloid nucleus, ventral lateral division (Bvl)

Super-regions:
Basal amygdaloid nucleus, ventral lateral division < Nucleus basalis thalami < Amygdala < Basal Ganglia according to GM-Definition < Brain

Sources:
Accessor basal nucleus (amygdala), ventromedial division, Accessory basal amygdaloid nucleus, dorsal division, Accessory basal amygdaloid nucleus, ventral division, Basal amygdaloid nucleus, intermediate part

Targets:
Accessor basal nucleus (amygdala), ventromedial division, Accessory basal amygdaloid nucleus, dorsal division, Accessory basal amygdaloid nucleus, parvicellular part, Accessory basal amygdaloid nucleus, ventral division, Basal amygdaloid nucleus, intermediate part, LGN external magnocellular layer, Lateral nucleus (amygdala), ventral division, Nucleus pulvinaris inferior thalami, Periamygdaloid cortex 2, amygdalohippocampal area, anterior amygdaloid area, central nucleus of the amygdala, cortical nucleus, anterior division, cortical nucleus, posterior division, ventral striatal shell

---
Region: Accessory basal amygdaloid nucleus, ventral division (ABv)

Super-regions:
Accessory basal amygdaloid nucleus, ventral division < Nucleus basalis thalami < Amygdala < Basal Ganglia according to GM-Definition < Brain

Sources:
Accessor basal nucleus (amygdala), ventromedial division, Accessory basal amygdaloid nucleus, dorsal division, Basal amygdaloid nucleus, intermediate part, Basal amygdaloid nucleus, ventral lateral division

Targets:
Accessor basal nucleus (amygdala), ventromedial division, Accessory basal amygdaloid nucleus, dorsal division, Accessory basal amygdaloid nucleus, parvicellular part, Basal amygdaloid nucleus, intermediate part, Basal amygdaloid nucleus, ventral lateral division, CA1 subfield of Ammon`s horn, LGN external magnocellular layer, Lateral nucleus (amygdala), dorsal division, Lateral nucleus (amygdala), dorsal intermediate division, Nucleus of the lateral olfactory tract, Nucleus pulvinaris inferior

thalami, Periamygdaloid cortex 2, amygdalohippocampal area, anterior amygdaloid area, central nucleus of the amygdala, cortical nucleus, anterior division, cortical nucleus, posterior division, lateral nucleus (amygdala), ventrolateral subdivision, ventral striatal shell

---

Region: Medial basal nucleus of the amygdala (MB)

Super-regions:
Medial basal nucleus of the amygdala < Nucleus basalis thalami < Amygdala < Basal Ganglia according to GM-Definition < Brain

Sources:
Accessory basal amygdaloid nucleus, parvicellular part, Anterior inferotemporal area (ventral), Area 20, Basolateral nucleus of amygdala, CA1 subfield of Ammon`s horn, Central inferotemporal area, Temporopolar area TG, accessory basal nucleus (amygdala), magnocellular subdivision, prosubiculum, temporal visual association area in the lower bank of the superior temporal sulcus

Targets:
Anterior inferotemporal area (ventral), Area 11, Area 20, Area 21, Area 25, Area 32, Area 35, CA1 subfield of Ammon`s horn, CA3 subfield of Ammons horn, Central inferotemporal area, Entorhinal cortex, Hippocampus, Inferotemporal area TE, Lateral auditory field, Nucleus medialis dorsalis thalami, Nucleus medialis dorsalis thalami, pars magnocellularis, Nucleus peripeduncularis thalami, Orbital area 12, Orbitofrontal area 13, Orbitofrontal area 14, Posterior inferotemporal area, Temporal proisocortex, Temporopolar area TG, Ventral area 46, area 24, medial entorhinal cortex, prosubiculum, temporal visual association area in the lower bank of the superior temporal sulcus

---

Region: Accessor basal nucleus (amygdala), ventromedial division (ABvm)

Super-regions:
Accessor basal nucleus (amygdala), ventromedial division < Nucleus basalis thalami < Amygdala < Basal Ganglia according to GM-Definition < Brain

Sources:
Accessory basal amygdaloid nucleus, dorsal division, Accessory basal amygdaloid nucleus, ventral division, Basal amygdaloid nucleus, ventral lateral division, Lateral auditory field, Lateral nucleus (amygdala), dorsal intermediate division, Lateral nucleus (amygdala), ventral division, lateral nucleus (amygdala), ventrolateral subdivision

Targets:
Accessory basal amygdaloid nucleus, dorsal division, Accessory basal amygdaloid nucleus, parvicellular part, Accessory basal amygdaloid nucleus, ventral division, Basal amygdaloid nucleus, intermediate part, Basal amygdaloid nucleus, ventral lateral division, CA1 subfield of Ammon`s horn, Intermediate agranula insular cortex, LGN external magnocellular layer, Lateral nucleus (amygdala), dorsal division, Lateral nucleus (amygdala), dorsal intermediate division, Lateral nucleus (amygdala), ventral division, Nucleus pulvinaris inferior thalami, Orbital area 12, Orbitofrontal area 13, Orbitofrontal area 14, Periamygdaloid cortex 2, Posteromedial agranular insular cortex, anterior amygdaloid area, central nucleus of the amygdala, cortical nucleus, anterior division, cortical nucleus, posterior division, prosubiculum, ventral striatal shell

---

Region: accessory basal nucleus (amygdala), magnocellular subdivision (ABmg)

Super-regions:
accessory basal nucleus (amygdala), magnocellular subdivision < Nucleus basalis thalami < Amygdala < Basal Ganglia according to GM-Definition < Brain

Sources:

Accessory basal amygdaloid nucleus, parvicellular part, Agranular insula, Area 25, Area 35, Area 36, Basolateral nucleus of amygdala, Caudal part of area 36, Cortical area 36p, Entorhinal cortex, Inferotemporal area TE, Intermediate agranula insular cortex, Lateral auditory field, Lateral nucleus (amygdala), dorsal intermediate division, Lateral nucleus (amygdala), ventral division, Medial agranular insular cortex, Orbitofrontal area 13, Orbitofrontal area 13a, Rostral part of area 36, Temporal area TF, lateral nucleus (amygdala), ventrolateral subdivision, periamygdaloid cortex

Targets:
Accessory basal amygdaloid nucleus, parvicellular part, Area 12, Area 6, Basolateral nucleus of amygdala, Cingulate motor areas, Fascia dentata hippocampi, Intermediate agranula insular cortex, LGN external magnocellular layer, Lateral auditory field, Medial area 11, Medial basal nucleus of the amygdala, Nucleus medialis dorsalis thalami, Nucleus medialis dorsalis thalami, pars magnocellularis, Orbital area 12, Orbitofrontal area 13, Orbitofrontal area 13a, Orbitofrontal area 14, Periamygdaloid cortex 2, Posteromedial agranular insular cortex, Rostral area 14, Rostral part of area 36, Temporal area TF, Temporal area TH, amygdalohippocampal area, anterior amygdaloid area, central nucleus of the amygdala, cortical nucleus (amygdala), periamygdaloid cortex

---
Region: anterior amygdaloid area (A)

Super-regions:
anterior amygdaloid area < Amygdala < Basal Ganglia according to GM-Definition < Brain

Sources:
Accessor basal nucleus (amygdala), ventromedial division, Accessory basal amygdaloid nucleus, dorsal division, Accessory basal amygdaloid nucleus, ventral division, Area 36, Basal amygdaloid nucleus, intermediate part, Basal amygdaloid nucleus, ventral lateral division, Basolateral nucleus of amygdala, Lateral auditory field, Lateral nucleus (amygdala), dorsal intermediate division, Lateral nucleus (amygdala), ventral division, Rostral part of area 36, accessory basal nucleus (amygdala), magnocellular subdivision, lateral nucleus (amygdala), ventrolateral subdivision

Targets:
Area 32, Area 35, Caudal part of area 36, Entorhinal cortex, Nucleus medialis dorsalis thalami, Orbitofrontal area 13, Rostral part of area 36, Temporal area TF, Temporal area TH, Temporopolar area TG, medial entorhinal cortex

---
Region: Nucleus pulvinaris inferior thalami (I#2)

Super-regions:
Nucleus pulvinaris inferior thalami < Amygdala < Basal Ganglia according to GM-Definition < Brain

Sources:
Accessor basal nucleus (amygdala), ventromedial division, Accessory basal amygdaloid nucleus, dorsal division, Accessory basal amygdaloid nucleus, ventral division, Basal amygdaloid nucleus, ventral lateral division, Lateral nucleus (amygdala), ventral division

Targets:
Orbital area 12

Region: LGN external magnocellular layer (ME#1)

Super-regions:
LGN external magnocellular layer < Amygdala < Basal Ganglia according to GM-Definition < Brain

Sources:
Accessor basal nucleus (amygdala), ventromedial division, Accessory basal amygdaloid nucleus, dorsal division, Accessory basal amygdaloid nucleus, parvicellular part, Accessory basal

amygdaloid nucleus, ventral division, Area 36, Basal amygdaloid nucleus, ventral lateral division, Basolateral nucleus of amygdala, Intermediate agranula insular cortex, Lateral auditory field, Lateral nucleus (amygdala), dorsal intermediate division, Lateral nucleus (amygdala), ventral division, Medial agranular insular cortex, Nucleus basalis thalami, Orbitofrontal area 13a, Temporopolar area TG, accessory basal nucleus (amygdala), magnocellular subdivision

Targets:
Entorhinal cortex, Intermediate agranula insular cortex, Nucleus basalis thalami, Nucleus medialis dorsalis thalami, Orbitofrontal area 13, Posteromedial agranular insular cortex, Rostral part of area 36, Temporopolar area TG, medial entorhinal cortex

---
Region: central nucleus of the amygdala (CE#1)

Super-regions:
central nucleus of the amygdala < Amygdala < Basal Ganglia according to GM-Definition < Brain

Sources:
Accessor basal nucleus (amygdala), ventromedial division, Accessory basal amygdaloid nucleus, dorsal division, Accessory basal amygdaloid nucleus, parvicellular part, Accessory basal amygdaloid nucleus, ventral division, Anterior inferotemporal area (ventral), Area 36, Basal amygdaloid nucleus, intermediate part, Basal amygdaloid nucleus, ventral lateral division, Basolateral nucleus of amygdala, Intermediate agranula insular cortex, Lateral auditory field, Lateral nucleus (amygdala), dorsal intermediate division, Lateral nucleus (amygdala), ventral division, Medial agranular insular cortex, Nucleus basalis thalami, Orbitofrontal area 13a, Rostral part of area 36, Temporal area TF, accessory basal nucleus (amygdala), magnocellular subdivision, periamygdaloid cortex

Targets:
Lateral auditory field, Nucleus basalis thalami, Nucleus medialis dorsalis thalami, Posteromedial agranular insular cortex, Rostral part of area 36, Temporopolar area TG

Region: periamygdaloid cortex (PAC#1)

Super-regions:
periamygdaloid cortex < Amygdala < Basal Ganglia according to GM-Definition < Brain

Sources:
Intermediate agranula insular cortex, Lateral auditory field, Lateral nucleus (amygdala), dorsal intermediate division, Lateral nucleus (amygdala), ventral division, Nucleus basalis thalami, Orbitofrontal area 13a, accessory basal nucleus (amygdala), magnocellular subdivision

Descendant sources:
Accessor basal nucleus (amygdala), ventromedial division, Accessory basal amygdaloid nucleus, dorsal division, Accessory basal amygdaloid nucleus, parvicellular part, Accessory basal amygdaloid nucleus, ventral division, Area 36, Basal amygdaloid nucleus, ventral lateral division, Basolateral nucleus of amygdala, CA1 subfield of Ammon`s horn, Lateral auditory field, Lateral nucleus (amygdala), dorsal intermediate division, Lateral nucleus (amygdala), ventral division, Nucleus basalis thalami, Rostral part of area 36, Temporopolar area TG, accessory basal nucleus (amygdala), magnocellular subdivision, lateral nucleus (amygdala), ventrolateral subdivision

Targets:
Accessory basal amygdaloid nucleus, parvicellular part, Area 11, Area 25, Area 32, Caudal part of area 36, Entorhinal cortex, Intermediate agranula insular cortex, Lateral auditory field, Nucleus medialis dorsalis thalami, Orbitofrontal area 13, Orbitofrontal area 13a, Posteromedial agranular insular cortex, Rostral part of area 36, Temporal area TF, Temporal area TH, Temporal proisocortex, accessory basal nucleus (amygdala), magnocellular subdivision, central nucleus of the amygdala

Descendant targets:
Anterior inferotemporal area (ventral), Area 20, Area 32, Caudal part of area 36, Entorhinal cortex, Inferotemporal area TE, Intermediate agranula insular cortex, Lateral auditory

field, Nucleus basalis thalami, Nucleus medialis dorsalis thalami, Nucleus medialis dorsalis thalami, pars magnocellularis, Orbitofrontal area 13, Orbitofrontal area 13a, Orbitofrontal area 14, Posteromedial agranular insular cortex, Rostral part of area 36, Temporal area TF, Temporopolar area TG

Sub-regions:
Periamygdaloid cortex 2, amygdalohippocampal area, cortical nucleus (amygdala)

Region: amygdalohippocampal area (AHA)

Super-regions:
amygdalohippocampal area < periamygdaloid cortex < Amygdala < Basal Ganglia according to GM-Definition < Brain

Sources:
Accessory basal amygdaloid nucleus, parvicellular part, Accessory basal amygdaloid nucleus, ventral division, Area 36, Basal amygdaloid nucleus, ventral lateral division, Basolateral nucleus of amygdala, Lateral auditory field, Lateral nucleus (amygdala), dorsal intermediate division, Lateral nucleus (amygdala), ventral division, Nucleus basalis thalami, accessory basal nucleus (amygdala), magnocellular subdivision, lateral nucleus (amygdala), ventrolateral subdivision

Targets:
Area 32, Nucleus medialis dorsalis thalami, Nucleus medialis dorsalis thalami, pars magnocellularis, Orbitofrontal area 14, Rostral part of area 36

Region: Periamygdaloid cortex 2 (PAC2)

Super-regions:
Periamygdaloid cortex 2 < periamygdaloid cortex < Amygdala < Basal Ganglia according to GM-Definition < Brain

Sources:
Accessor basal nucleus (amygdala), ventromedial division, Accessory basal amygdaloid nucleus, dorsal division, Accessory basal amygdaloid nucleus, parvicellular part, Accessory basal amygdaloid nucleus, ventral division, Area 36, Basal amygdaloid nucleus, ventral lateral division, Basolateral nucleus of amygdala, CA1 subfield of Ammon`s horn, Lateral auditory field, Lateral nucleus (amygdala), dorsal intermediate division, Lateral nucleus (amygdala), ventral division, Rostral part of area 36, Temporopolar area TG, accessory basal nucleus (amygdala), magnocellular subdivision, lateral nucleus (amygdala), ventrolateral subdivision

Targets:
Anterior inferotemporal area (ventral), Area 20, Caudal part of area 36, Orbitofrontal area 13, Rostral part of area 36, Temporopolar area TG

Region: cortical nucleus (amygdala) (Co)

Super-regions:
cortical nucleus (amygdala) < periamygdaloid cortex < Amygdala < Basal Ganglia according to GM-Definition < Brain

Sources:
Accessory basal amygdaloid nucleus, parvicellular part, Basolateral nucleus of amygdala, CA1 subfield of Ammon`s horn, Temporopolar area TG, accessory basal nucleus (amygdala), magnocellular subdivision

Descendant sources:
Accessor basal nucleus (amygdala), ventromedial division, Accessory basal amygdaloid nucleus, dorsal division, Accessory basal amygdaloid nucleus, ventral division, Area 36, Basal amygdaloid nucleus, ventral lateral division, Lateral auditory field, Lateral nucleus (amygdala), dorsal intermediate division, Lateral nucleus (amygdala), ventral

division, Nucleus basalis thalami, Rostral part of area 36, lateral nucleus (amygdala), ventrolateral subdivision

Targets:
Entorhinal cortex, Inferotemporal area TE, Lateral auditory field, Nucleus basalis thalami, Temporopolar area TG

Descendant targets:
Intermediate agranula insular cortex, Nucleus medialis dorsalis thalami, Orbitofrontal area 13a, Posteromedial agranular insular cortex, Rostral part of area 36, Temporal area TF

Sub-regions:
Nucleus of the lateral olfactory tract, cortical nucleus, anterior division, cortical nucleus, posterior division

---
Region: cortical nucleus, posterior division (COp)

Super-regions:
cortical nucleus, posterior division < cortical nucleus (amygdala) < periamygdaloid cortex < Amygdala < Basal Ganglia according to GM-Definition < Brain

Sources:
Accessor basal nucleus (amygdala), ventromedial division, Accessory basal amygdaloid nucleus, dorsal division, Accessory basal amygdaloid nucleus, ventral division, Area 36, Basal amygdaloid nucleus, ventral lateral division, Lateral auditory field, Lateral nucleus (amygdala), dorsal intermediate division, Lateral nucleus (amygdala), ventral division, Nucleus basalis thalami, lateral nucleus (amygdala), ventrolateral subdivision

Targets:
Nucleus medialis dorsalis thalami, Temporal area TF

Region: Nucleus of the lateral olfactory tract (NLOT)

Super-regions:
Nucleus of the lateral olfactory tract < cortical nucleus (amygdala) < periamygdaloid cortex < Amygdala < Basal Ganglia according to GM-Definition < Brain

Sources:
Accessory basal amygdaloid nucleus, dorsal division, Accessory basal amygdaloid nucleus, ventral division, Area 36, Lateral auditory field, Lateral nucleus (amygdala), dorsal intermediate division, Lateral nucleus (amygdala), ventral division, Rostral part of area 36, lateral nucleus (amygdala), ventrolateral subdivision

Targets:
Rostral part of area 36

Region: cortical nucleus, anterior division (COa)

Super-regions:
cortical nucleus, anterior division < cortical nucleus (amygdala) < periamygdaloid cortex < Amygdala < Basal Ganglia according to GM-Definition < Brain

Sources:
Accessor basal nucleus (amygdala), ventromedial division, Accessory basal amygdaloid nucleus, dorsal division, Accessory basal amygdaloid nucleus, ventral division, Area 36, Basal amygdaloid nucleus, ventral lateral division, Lateral auditory field, Lateral nucleus (amygdala), dorsal intermediate division, Lateral nucleus (amygdala), ventral division, Rostral part of area 36

Targets:

Intermediate agranula insular cortex, Nucleus medialis dorsalis thalami, Orbitofrontal area 13a, Posteromedial agranular insular cortex, Rostral part of area 36

Region: Lateral auditory field (L#2)

Super-regions:
Lateral auditory field < Amygdala < Basal Ganglia according to GM-Definition < Brain

Sources:
Accessory basal amygdaloid nucleus, parvicellular part, Anterior inferotemporal area (dorsal), Anterior inferotemporal area (ventral), Area 20, Area 21, Area 35, Area 36, Basolateral nucleus of amygdala, Caudal part of area 36, Central inferotemporal area, Inferotemporal area TE, Intermediate agranula insular cortex, Lateral area 12, Medial agranular insular cortex, Medial basal nucleus of the amygdala, Midline nuclei of the thalamus, Nucleus basalis thalami, Nucleus centralis densocellularis thalami, Nucleus centralis inferior thalami, Nucleus paraventricularis thalami, pars anterior, Nucleus reuniens thalami, Orbitofrontal area 13a, Posterior inferotemporal area, Rostral part of area 36, Temporal area TF, Temporal area TH, Temporal proisocortex, Temporopolar area TG, accessory basal nucleus (amygdala), magnocellular subdivision, central nucleus of the amygdala, cortical nucleus (amygdala), periamygdaloid cortex, temporal visual association area in the lower bank of the superior temporal sulcus

Descendant sources:
Accessor basal nucleus (amygdala), ventromedial division, Accessory basal amygdaloid nucleus, dorsal division, Accessory basal amygdaloid nucleus, ventral division, Agranular insula, Area 10, Area 11, Area 12, Area 25, Area 32, Area 35, Area 36, Area 6, Area 8, Area 9, Basal amygdaloid nucleus, intermediate part, Basal amygdaloid nucleus, ventral lateral division, Caudal part of area 36, Claustrum, Cortical area 45, Cortical area 46, Dysgranular insular cortex, Entorhinal cortex, Granular insular cortex, Inferotemporal area TE, Lateral nucleus (amygdala), dorsal intermediate division, Lateral nucleus (amygdala), ventral division, Medial basal nucleus of the amygdala, Midline nuclei of the thalamus, Nucleus pulvinaris thalami, Orbitofrontal area 13, Orbitofrontal area 13a, Orbitofrontal area 14, Parahippocampal cortex, Piriform cortex, Posterior inferotemporal area, Rostral part of area 36, Superior temporal sulcus, dorsal, Temporal area TF, Temporal area TH, Temporal proisocortex, area 24, lateral nucleus (amygdala), ventrolateral subdivision, substantia nigra, superior temporal gyrus

Targets:
Accessor basal nucleus (amygdala), ventromedial division, Accessory basal amygdaloid nucleus, parvicellular part, Agranular insula, Anterior inferotemporal area (ventral), Area 12, Area 20, Area 25, Area 32, Area 35, Area 36, Basal amygdaloid nucleus, intermediate part, Basolateral nucleus of amygdala, Caudal part of area 36, Dysgranular insular cortex, Entorhinal cortex, Fascia dentata hippocampi, Gustatory cortex, Inferotemporal area TE, Insula, Intermediate agranula insular cortex, Intermediate field of entorhinal cortex, LGN external magnocellular layer, Lateral field (caudal part) of entorhinal cortex, Lateral field (rostral part) of entorhinal cortex, Lateral field of entorhinal cortex, Medial area 11, Nucleus basalis thalami, Nucleus medialis dorsalis thalami, Nucleus medialis dorsalis thalami, pars magnocellularis, Nucleus of the lateral olfactory tract, Orbitofrontal area 13, Orbitofrontal area 13a, Orbitofrontal area 14, Periamygdaloid cortex 2, Posterior inferotemporal area, Posteromedial agranular insular cortex, Rostral area 14, Rostral part of area 36, Temporal area TA, Temporal area TF, Temporal area TH, Temporal proisocortex, Temporopolar area TG, Visual area 4, accessory basal nucleus (amygdala), magnocellular subdivision, amygdalohippocampal area, anterior amygdaloid area, area 24, central nucleus of the amygdala, cortical nucleus, anterior division, cortical nucleus, posterior division, medial entorhinal cortex, periamygdaloid cortex

Descendant targets:
Accessor basal nucleus (amygdala), ventromedial division, Accessory basal amygdaloid nucleus, parvicellular part, Basal amygdaloid nucleus, intermediate part, LGN external magnocellular layer, Lateral nucleus (amygdala), dorsal division, Lateral nucleus (amygdala), dorsal intermediate division, Lateral nucleus (amygdala), ventral division, Nucleus

of the lateral olfactory tract, Nucleus pulvinaris inferior thalami, Periamygdaloid cortex 2, Rostral part of area 36, Temporal proisocortex, accessory basal nucleus (amygdala), magnocellular subdivision, amygdalohippocampal area, anterior amygdaloid area, central nucleus of the amygdala, cortical nucleus, anterior division, cortical nucleus, posterior division, lateral nucleus (amygdala), ventrolateral subdivision, periamygdaloid cortex

Sub-regions:
Lateral amygdaloid nucleus, dorsomedial region, Lateral nucleus (amygdala), ventral division, lateral nucleus (amygdala), ventrolateral subdivision

---
Region: Lateral amygdaloid nucleus, dorsomedial region (Ldm)

Super-regions:
Lateral amygdaloid nucleus, dorsomedial region < Lateral auditory field < Amygdala < Basal Ganglia according to GM-Definition < Brain

Descendant sources:
Accessor basal nucleus (amygdala), ventromedial division, Accessory basal amygdaloid nucleus, dorsal division, Accessory basal amygdaloid nucleus, ventral division, Agranular insula, Area 10, Area 11, Area 12, Area 25, Area 32, Area 35, Area 36, Area 6, Area 8, Area 9, Basal amygdaloid nucleus, intermediate part, Caudal part of area 36, Claustrum, Cortical area 45, Cortical area 46, Dysgranular insular cortex, Entorhinal cortex, Granular insular cortex, Inferotemporal area TE, Lateral nucleus (amygdala), dorsal intermediate division, Lateral nucleus (amygdala), ventral division, Medial basal nucleus of the amygdala, Midline nuclei of the thalamus, Nucleus pulvinaris thalami, Orbitofrontal area 13, Orbitofrontal area 13a, Orbitofrontal area 14, Parahippocampal cortex, Piriform cortex, Posterior inferotemporal area, Rostral part of area 36, Superior temporal sulcus, dorsal, Temporal area TF, Temporal area TH, Temporal proisocortex, area 24, lateral nucleus (amygdala), ventrolateral subdivision, substantia nigra, superior temporal gyrus

Descendant targets:
Accessor basal nucleus (amygdala), ventromedial division, Accessory basal amygdaloid nucleus, parvicellular part, Basal amygdaloid nucleus, intermediate part, LGN external magnocellular layer, Lateral nucleus (amygdala), dorsal division, Lateral nucleus (amygdala), ventral division, Nucleus of the lateral olfactory tract, Periamygdaloid cortex 2, Rostral part of area 36, accessory basal nucleus (amygdala), magnocellular subdivision, amygdalohippocampal area, anterior amygdaloid area, central nucleus of the amygdala, cortical nucleus, anterior division, cortical nucleus, posterior division, lateral nucleus (amygdala), ventrolateral subdivision, periamygdaloid cortex

Sub-regions:
Lateral nucleus (amygdala), dorsal division, Lateral nucleus (amygdala), dorsal intermediate division

---
Region: Lateral nucleus (amygdala), dorsal intermediate division (Ldi)

Super-regions:
Lateral nucleus (amygdala), dorsal intermediate division < Lateral amygdaloid nucleus, dorsomedial region < Lateral auditory field < Amygdala < Basal Ganglia according to GM-Definition < Brain

Sources:
Accessor basal nucleus (amygdala), ventromedial division, Accessory basal amygdaloid nucleus, dorsal division, Accessory basal amygdaloid nucleus, ventral division, Agranular insula, Area 10, Area 11, Area 12, Area 25, Area 32, Area 35, Area 36, Area 6, Area 8, Area 9, Basal amygdaloid nucleus, intermediate part, Caudal part of area 36, Claustrum, Cortical area 45, Cortical area 46, Dysgranular insular cortex, Entorhinal cortex, Granular insular cortex, Inferotemporal area TE, Lateral nucleus (amygdala), ventral division, Medial basal nucleus of the amygdala, Midline nuclei of the thalamus, Nucleus pulvinaris thalami, Orbitofrontal area 13,

Orbitofrontal area 13a, Orbitofrontal area 14, Parahippocampal cortex, Piriform cortex, Posterior inferotemporal area, Rostral part of area 36, Superior temporal sulcus, dorsal, Temporal area TF, Temporal area TH, Temporal proisocortex, area 24, lateral nucleus (amygdala), ventrolateral subdivision, substantia nigra, superior temporal gyrus

Targets:
Accessor basal nucleus (amygdala), ventromedial division, Accessory basal amygdaloid nucleus, parvicellular part, Basal amygdaloid nucleus, intermediate part, LGN external magnocellular layer, Lateral nucleus (amygdala), dorsal division, Lateral nucleus (amygdala), ventral division, Nucleus of the lateral olfactory tract, Periamygdaloid cortex 2, accessory basal nucleus (amygdala), magnocellular subdivision, amygdalohippocampal area, anterior amygdaloid area, central nucleus of the amygdala, cortical nucleus, anterior division, cortical nucleus, posterior division, lateral nucleus (amygdala), ventrolateral subdivision, periamygdaloid cortex

---
Region: Lateral nucleus (amygdala), dorsal division (Ld#2)

Super-regions:
Lateral nucleus (amygdala), dorsal division < Lateral amygdaloid nucleus, dorsomedial region < Lateral auditory field < Amygdala < Basal Ganglia according to GM-Definition < Brain

Sources:
Accessor basal nucleus (amygdala), ventromedial division, Accessory basal amygdaloid nucleus, dorsal division, Accessory basal amygdaloid nucleus, ventral division, Agranular insula, Area 10, Area 11, Area 12, Area 25, Area 32, Area 35, Area 36, Area 9, Caudal part of area 36, Cortical area 45, Cortical area 46, Dysgranular insular cortex, Entorhinal cortex, Granular insular cortex, Inferotemporal area TE, Lateral nucleus (amygdala), dorsal intermediate division, Orbitofrontal area 13, Orbitofrontal area 13a, Orbitofrontal area 14, Parahippocampal cortex, Piriform cortex, Posterior inferotemporal area, Rostral part of area 36, Superior temporal sulcus, dorsal, Temporal area TF, Temporal area TH, Temporal proisocortex, area 24, lateral nucleus (amygdala), ventrolateral subdivision, superior temporal gyrus

Targets:
Rostral part of area 36

Region: Lateral nucleus (amygdala), ventral division (Lv)

Super-regions:
Lateral nucleus (amygdala), ventral division < Lateral auditory field < Amygdala < Basal Ganglia according to GM-Definition < Brain

Sources:
Accessor basal nucleus (amygdala), ventromedial division, Agranular insula, Area 10, Area 12, Area 25, Area 32, Area 35, Area 36, Area 9, Basal amygdaloid nucleus, ventral lateral division, Caudal part of area 36, Claustrum, Cortical area 46, Dysgranular insular cortex, Entorhinal cortex, Granular insular cortex, Inferotemporal area TE, Lateral nucleus (amygdala), dorsal intermediate division, Medial basal nucleus of the amygdala, Midline nuclei of the thalamus, Nucleus pulvinaris thalami, Orbitofrontal area 13, Orbitofrontal area 13a, Orbitofrontal area 14, Parahippocampal cortex, Piriform cortex, Posterior inferotemporal area, Rostral part of area 36, Superior temporal sulcus, dorsal, Temporal area TF, Temporal area TH, Temporal proisocortex, area 24, lateral nucleus (amygdala), ventrolateral subdivision, substantia nigra, superior temporal gyrus

Targets:
Accessor basal nucleus (amygdala), ventromedial division, Accessory basal amygdaloid nucleus, parvicellular part, Basal amygdaloid nucleus, intermediate part, LGN external magnocellular layer, Lateral nucleus (amygdala), dorsal

intermediate division, Nucleus of the lateral olfactory tract, Nucleus pulvinaris inferior thalami, Periamygdaloid cortex 2, accessory basal nucleus (amygdala), magnocellular subdivision, amygdalohippocampal area, anterior amygdaloid area, central nucleus of the amygdala, cortical nucleus, anterior division, cortical nucleus, posterior division, lateral nucleus (amygdala), ventrolateral subdivision, periamygdaloid cortex

---
Region: lateral nucleus (amygdala), ventrolateral subdivision (Lvl)

Super-regions:
lateral nucleus (amygdala), ventrolateral subdivision < Lateral auditory field < Amygdala < Basal Ganglia according to GM-Definition < Brain

Sources:
Accessory basal amygdaloid nucleus, dorsal division, Accessory basal amygdaloid nucleus, ventral division, Agranular insula, Area 10, Area 11, Area 12, Area 25, Area 32, Area 35, Area 36, Caudal part of area 36, Dysgranular insular cortex, Entorhinal cortex, Granular insular cortex, Inferotemporal area TE, Lateral nucleus (amygdala), dorsal intermediate division, Lateral nucleus (amygdala), ventral division, Orbitofrontal area 13, Orbitofrontal area 13a, Orbitofrontal area 14, Parahippocampal cortex, Piriform cortex, Rostral part of area 36, Superior temporal sulcus, dorsal, Temporal area TF, Temporal area TH, Temporal proisocortex, area 24, superior temporal gyrus

Targets:
Accessor basal nucleus (amygdala), ventromedial division, Accessory basal amygdaloid nucleus, parvicellular part, Basal amygdaloid nucleus, intermediate part, Lateral nucleus (amygdala), dorsal division, Lateral nucleus (amygdala), dorsal intermediate division, Lateral nucleus (amygdala), ventral division, Nucleus of the lateral olfactory tract, Periamygdaloid cortex 2, Rostral part of area 36, Temporal proisocortex, accessory basal nucleus (amygdala), magnocellular subdivision, amygdalohippocampal area, anterior amygdaloid area, cortical nucleus, posterior division

---
Region: substantia nigra (SN)

Super-regions:
substantia nigra < Basal Ganglia according to GM-Definition < Brain

Sources:
Agranular frontal area 7 (= rostral dorsolateral premotor area), Frontal eye field, Nucleus caudatus; genu, Nucleus caudatus; tail, Premotor area 6 (dorsal part)

Targets:
Lateral nucleus (amygdala), dorsal intermediate division, Lateral nucleus (amygdala), ventral division, Nucleus caudatus; genu

---
Region: Primary sensory cortex (SI#2)

Super-regions:
Primary sensory cortex < Basal Ganglia according to GM-Definition < Brain

Sources:
Area 24b, Area 24c (rostral part of the cingulate sulcus), Area 25, Area 32, Area 9, Cortical area 45, Cortical area 46, Intermediate agranula insular cortex, Lateral agranular insular cortex, Lateral area 11, Lateral area 12, Medial agranular insular cortex, Medial area 10, Medial area 11, Medial area 12, Orbital area 10, Orbital area 12, Orbitofrontal area 13, lateral part, Orbitofrontal area 13, medial part, Orbitofrontal area 13a, Posteromedial agranular insular cortex, Precentral opercular area, Premotor area 6Va, Premotor area 6Vb, Rostral area 12, Rostral area 14

Targets:
Agranular frontal area 7 (= rostral dorsolateral premotor area), Amygdala, Area 12, Area 25, Area 7, Caudal inferior parietal

lobule, Cortical area 45, Cortical area 46, Extrastriate area OA, Fascia dentata hippocampi, Frontal eye field, Granular insular cortex, Hypothalamus, Inferotemporal area TE, Insula, Intermediate field of entorhinal cortex, Nucleus medialis dorsalis thalami, Nucleus medialis dorsalis thalami, pars magnocellularis, Olfactory Complex, Orbitofrontal area 13, Premotor area 6 (dorsal part), Primary motor area, Primary somatosensory cortex, Secondary somatosensory cortex, Temporal area TA, Temporal area TH, Temporopolar area TG, area 24, superior parietal lobule (posterior dorsomedial parietal cortex above the intraparietal sulcus)

Region: Nucleus subthalamicus (Sub.Th)

Super-regions:
Nucleus subthalamicus < Basal Ganglia according to GM-Definition < Brain

Sources:
Insula, Premotor area 6 (dorsal part)

Targets:
Frontal eye field

Region: Globus pallidus external part (GPe)

Super-regions:
Globus pallidus external part < Basal Ganglia according to GM-Definition < Brain

Sources:
Nucleus caudatus; genu, Nucleus caudatus; tail, Putamen; caudal

Targets:
Nucleus medialis dorsalis thalami

Region: striatum (STR)

Super-regions:
striatum < Basal Ganglia according to GM-Definition < Brain

Descendant sources:
Agranular frontal area 7 (= rostral dorsolateral premotor area), Area 10, Area 11, Area 12, Area 23, Area 24b, Area 24c (rostral part of the cingulate sulcus), Area 25, Area 32, Area 35, Area 7, Area 8, Area 9, Caudal and medial superior parietal lobule, Caudal inferior parietal lobule, Cortical area 45, Cortical area 46, Extrastriate area OA, Fascia dentata hippocampi, Floor of superior temporal sulcus, Frontal eye field, Inferior parietal lobule (lateral posterior cortex below the intraparietal sulcus), Inferotemporal area TE, Intermediate agranula insular cortex, Lateral agranular insular cortex, Lateral area 11, Lateral area 12, Lateral intraparietal area, Medial agranular insular cortex, Medial area 10, Medial area 11, Medial area 12, Medial basal nucleus of the amygdala, Medial intraparietal area, Medial superior temporal area, Middle temporal area, Midpart of the inferior parietal lobule, Orbital area 10, Orbital area 12, Orbitofrontal area 13, Orbitofrontal area 13, lateral part, Orbitofrontal area 13, medial part, Orbitofrontal area 13a, Orbitofrontal area 14, Parietal area PE (cingulate part), Parietal area PG, medial part, Posterior inferotemporal area, Posteromedial agranular insular cortex, Precentral opercular area, Premotor area 6 (dorsal part), Premotor area 6Va, Premotor area 6Vb, Rostral area 12, Rostral area 14, Rostral inferior parietal lobule, Rostral parietal operculum, Rostral superior parietal lobule, Superior temporal sulcus, Temporal area TA, Temporal area TF, Temporal area TH, Temporopolar area TG, Ventral visual area 3, Visual area 2, Visual area 3, Visual area 4, Visual area 4 (dorsal part), area 24, substantia nigra, superior temporal gyrus

Descendant targets:
Globus pallidus external part, Posterior inferotemporal area, substantia nigra

Sub-regions:
Nucleus caudatus, Putamen

Region: Nucleus caudatus (Cd)

Super-regions:
Nucleus caudatus < striatum < Basal Ganglia according to GM-Definition < Brain

Sources:
Agranular frontal area 7 (= rostral dorsolateral premotor area), Area 10, Area 11, Area 12, Area 25, Area 32, Area 35, Area 7, Area 8, Area 9, Caudal and medial superior parietal lobule, Cortical area 45, Cortical area 46, Extrastriate area OA, Frontal eye field, Inferior parietal lobule (lateral posterior cortex below the intraparietal sulcus), Inferotemporal area TE, Intermediate agranula insular cortex, Lateral agranular insular cortex, Lateral area 11, Lateral area 12, Lateral intraparietal area, Medial area 10, Medial area 11, Medial area 12, Medial intraparietal area, Midpart of the inferior parietal lobule, Orbital area 10, Orbital area 12, Orbitofrontal area 13, Orbitofrontal area 13, lateral part, Orbitofrontal area 13, medial part, Orbitofrontal area 13a, Orbitofrontal area 14, Parietal area PE (cingulate part), Parietal area PG, medial part, Posterior inferotemporal area, Posteromedial agranular insular cortex, Premotor area 6 (dorsal part), Rostral area 12, Rostral area 14, Rostral inferior parietal lobule, Rostral superior parietal lobule, Temporal area TA, Temporal area TF, Temporopolar area TG, Visual area 2, Visual area 3, Visual area 4, Visual area 4 (dorsal part), area 24, superior temporal gyrus

Descendant sources:
Area 23, Area 25, Area 35, Area 7, Area 8, Area 9, Caudal and medial superior parietal lobule, Caudal inferior parietal lobule, Cortical area 46, Extrastriate area OA, Fascia dentata hippocampi, Floor of superior temporal sulcus, Inferior parietal lobule (lateral posterior cortex below the intraparietal sulcus), Inferotemporal area TE, Medial area 12, Medial basal nucleus of the amygdala, Medial superior temporal area, Middle temporal area, Posterior inferotemporal area, Rostral inferior parietal lobule, Rostral superior parietal lobule, Superior temporal sulcus, Temporal area TA, Temporal area TF, Temporal area TH, Temporopolar area TG, Ventral visual area 3, Visual area 2, Visual area 4, Visual area 4 (dorsal part), area 24, substantia nigra, superior temporal gyrus

Descendant targets:
Globus pallidus external part, substantia nigra

Sub-regions:
Nucleus caudatus; genu, Nucleus caudatus; tail

Region: Nucleus caudatus; tail (Cd_t)

Super-regions:
Nucleus caudatus; tail < Nucleus caudatus < striatum < Basal Ganglia according to GM-Definition < Brain

Sources:
Area 25, Area 35, Cortical area 46, Fascia dentata hippocampi, Inferior parietal lobule (lateral posterior cortex below the intraparietal sulcus), Inferotemporal area TE, Medial area 12, Temporal area TA, Temporal area TF, Temporal area TH, Temporopolar area TG, Visual area 2, Visual area 4, area 24, superior temporal gyrus

Targets:
Globus pallidus external part, substantia nigra

Region: Nucleus caudatus; genu (Cd_g)

Super-regions:
Nucleus caudatus; genu < Nucleus caudatus < striatum < Basal Ganglia according to GM-Definition < Brain

Sources:
Area 23, Area 7, Area 8, Area 9, Caudal and medial superior parietal lobule, Caudal inferior parietal lobule, Cortical area 46, Extrastriate area OA, Floor of superior temporal sulcus, Inferior parietal lobule (lateral posterior cortex below the intraparietal sulcus), Inferotemporal area TE, Medial basal nucleus of the amygdala, Medial superior temporal area, Middle temporal area, Posterior inferotemporal area, Rostral inferior

parietal lobule, Rostral superior parietal lobule, Superior temporal sulcus, Temporal area TA, Temporal area TF, Ventral visual area 3, Visual area 2, Visual area 4, Visual area 4 (dorsal part), substantia nigra, superior temporal gyrus

Targets:
Globus pallidus external part, substantia nigra

Region: Putamen (Pu)

Super-regions:
Putamen < striatum < Basal Ganglia according to GM-Definition < Brain

Sources:
Agranular frontal area 7 (= rostral dorsolateral premotor area), Area 12, Area 7, Area 8, Area 9, Caudal and medial superior parietal lobule, Cortical area 45, Inferotemporal area TE, Lateral agranular insular cortex, Lateral area 11, Medial intraparietal area, Midpart of the inferior parietal lobule, Parietal area PE (cingulate part), Parietal area PG, medial part, Posterior inferotemporal area, Premotor area 6 (dorsal part), Rostral inferior parietal lobule, Rostral parietal operculum, Rostral superior parietal lobule, Temporal area TF

Descendant sources:
Agranular frontal area 7 (= rostral dorsolateral premotor area), Area 10, Area 11, Area 12, Area 24b, Area 24c (rostral part of the cingulate sulcus), Area 32, Area 35, Area 7, Area 8, Area 9, Caudal and medial superior parietal lobule, Cortical area 45, Cortical area 46, Extrastriate area OA, Frontal eye field, Inferior parietal lobule (lateral posterior cortex below the intraparietal sulcus), Inferotemporal area TE, Intermediate agranula insular cortex, Lateral agranular insular cortex, Lateral area 11, Lateral area 12, Lateral intraparietal area, Medial agranular insular cortex, Medial area 10, Medial area 11, Medial area 12, Medial intraparietal area, Middle temporal area, Midpart of the inferior parietal lobule, Orbital area 10, Orbital area 12, Orbitofrontal area 13, lateral part, Orbitofrontal area 13, medial part, Orbitofrontal area 13a, Parietal area PE (cingulate part), Parietal area PG, medial part, Posterior inferotemporal area, Posteromedial agranular insular cortex, Precentral opercular area, Premotor area 6 (dorsal part), Premotor area 6Va, Premotor area 6Vb, Rostral area 12, Rostral area 14, Rostral inferior parietal lobule, Rostral parietal operculum, Rostral superior parietal lobule, Temporal area TA, Temporal area TF, Temporopolar area TG, Visual area 2, Visual area 4, Visual area 4 (dorsal part), superior temporal gyrus

Descendant targets:
Globus pallidus external part, Posterior inferotemporal area

Sub-regions:
Putamen; caudal, Putamen; rostral

Region: Putamen; rostral (Pu_r)

Super-regions:
Putamen; rostral < Putamen < striatum < Basal Ganglia according to GM-Definition < Brain

Sources:
Agranular frontal area 7 (= rostral dorsolateral premotor area), Area 10, Area 11, Area 12, Area 24b, Area 24c (rostral part of the cingulate sulcus), Area 32, Area 35, Area 7, Area 9, Caudal and medial superior parietal lobule, Cortical area 45, Cortical area 46, Inferior parietal lobule (lateral posterior cortex below the intraparietal sulcus), Inferotemporal area TE, Intermediate agranula insular cortex, Lateral agranular insular cortex, Lateral area 11, Lateral area 12, Medial agranular insular cortex, Medial area 10, Medial area 11, Medial area 12, Medial intraparietal area, Midpart of the inferior parietal lobule, Orbital area 10, Orbital area 12, Orbitofrontal area 13, lateral part, Orbitofrontal area 13, medial part, Orbitofrontal area 13a, Parietal area PE (cingulate part), Parietal area PG, medial part, Posteromedial agranular insular cortex, Precentral opercular area, Premotor area 6 (dorsal part), Premotor area 6Va, Premotor area 6Vb, Rostral area 12, Rostral

area 14, Rostral inferior parietal lobule, Rostral superior parietal lobule, Temporal area TA, Temporal area TF, Temporopolar area TG, superior temporal gyrus

Targets:
Posterior inferotemporal area

Region: Putamen; caudal (Pu_c)

Super-regions:
Putamen; caudal < Putamen < striatum < Basal Ganglia according to GM-Definition < Brain

Sources:
Agranular frontal area 7 (= rostral dorsolateral premotor area), Area 12, Area 7, Area 8, Area 9, Caudal and medial superior parietal lobule, Cortical area 46, Extrastriate area OA, Frontal eye field, Inferior parietal lobule (lateral posterior cortex below the intraparietal sulcus), Inferotemporal area TE, Lateral intraparietal area, Medial intraparietal area, Middle temporal area, Midpart of the inferior parietal lobule, Parietal area PE (cingulate part), Parietal area PG, medial part, Posterior inferotemporal area, Premotor area 6 (dorsal part), Rostral inferior parietal lobule, Rostral parietal operculum, Rostral superior parietal lobule, Temporopolar area TG, Visual area 2, Visual area 4, Visual area 4 (dorsal part)

Targets:
Globus pallidus external part

Region: Claustrum (Clau)

Super-regions:
Claustrum < Basal Ganglia according to GM-Definition < Brain

Sources:
Agranular frontal area 7 (= rostral dorsolateral premotor area), Area 8, Frontal eye field, Insula, Posterior inferotemporal area, Premotor area 6 (dorsal part), Rostral inferior parietal lobule, area 24

Targets:
Agranular frontal area 7 (= rostral dorsolateral premotor area), Area 35, Area 6 (ventral part), Cortical area 46, Entorhinal cortex, Entorhinal cortex, Frontal eye field, Lateral nucleus (amygdala), dorsal intermediate division, Lateral nucleus (amygdala), ventral division, Posterior inferotemporal area, Premotor area 6 (dorsal part), Rostral inferior parietal lobule, Temporopolar area TG, Visual area 1, area 24, medial entorhinal cortex, superior parietal lobule (posterior dorsomedial parietal cortex above the intraparietal sulcus)

Region: Medial basal nucleus of the amygdala (MB#2)

Super-regions:
Medial basal nucleus of the amygdala < Brain

Sources:
Area 8, Extrastriate area OA, Inferotemporal area TE, Posterior inferotemporal area, Visual area 2

Targets:
Lateral Geniculate Nucleus, Lateral nucleus (amygdala), dorsal intermediate division, Lateral nucleus (amygdala), ventral division, Nucleus caudatus; genu, Nucleus pulvinaris inferior thalami, Nucleus pulvinaris inferior thalami, central subdivision, Nucleus pulvinaris inferior thalami, lateral subdivision, Nucleus pulvinaris inferior thalami, pars medialis, Nucleus pulvinaris inferior thalami, pars posterior, Nucleus pulvinaris lateralis thalami pars alpha, Nucleus pulvinaris medialis thalami, Nucleus pulvinaris thalami, Temporopolar area TG, Visual area 1, posterior lateral auditory area

---
Region: Olfactory Complex (OFC)

Super-regions:
    Olfactory Complex < Brain

Sources:
    Area 36, Dysgranular Temporopolar Cortex, Entorhinal cortex, Lateral field of entorhinal cortex, Primary sensory cortex, Rostral part of area 36, Temporopolar area TG

Targets:
    Entorhinal cortex, Entorhinal cortex, Intermediate agranula insular cortex, Medial area 12, Nucleus medialis dorsalis thalami, Orbitofrontal area 13, Orbitofrontal area 13a, Orbitofrontal area 14, Posteromedial agranular insular cortex, Temporopolar area TG